The following vignette applies to the next **2** items. The items in the set must be answered in sequential order. Once you click **Proceed to Next Item**, you will not be able to add or change an answer.

A 34-year-old man is brought to the emergency department with new-onset confusion and lethargy. Laboratory studies, including an arterial blood gas, are obtained. The changes in his blood gas parameters are shown in the graph below. Point A represents these parameters at the patient's physiologic baseline, and point B indicates his state on arrival in the emergency department.



1 2 3 4 5 6 7 8 9 10 11 12 13 14 15 16 17 18 19 20 21 22 23 24 25 26 27 28 29 30

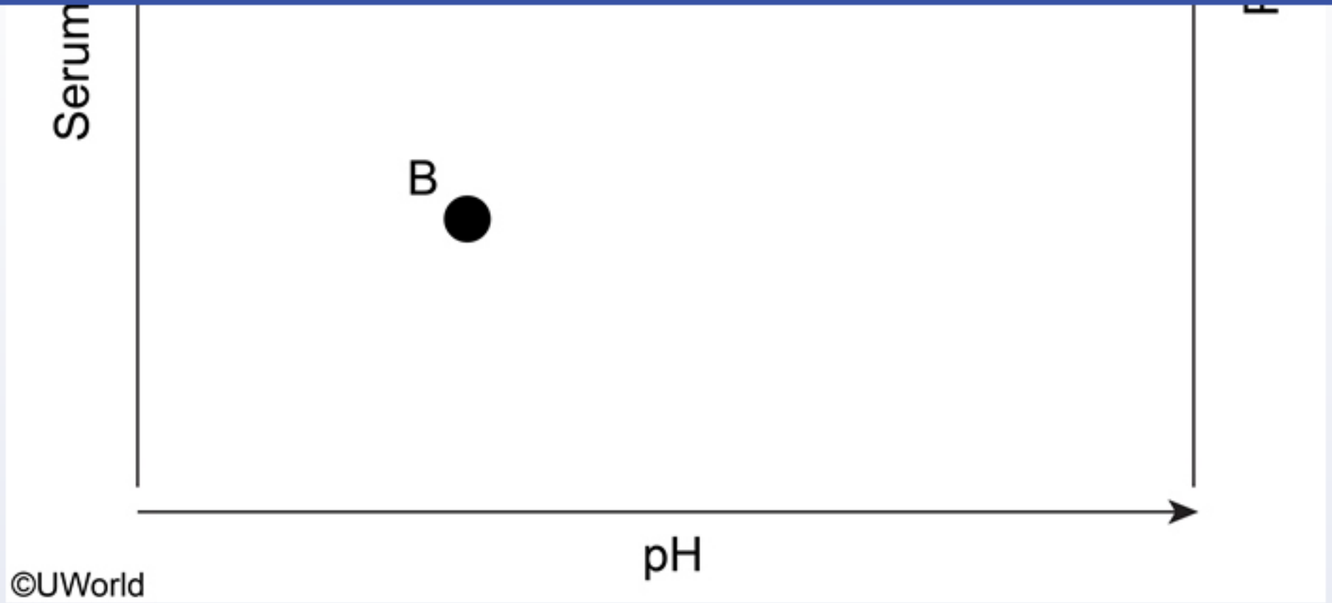

Item 1 of 2

Which of the following is the most likely diagnosis?

- A. Metabolic acidosis
- B. Metabolic alkalosis
- C. Respiratory acidosis
- D. Respiratory alkalosis

Submit

1 2 3 4 5 6 7 8 9 10 11 12 13 14 15 16 17 18 19 20 21 22 23 24 25 26 27 28 29 30

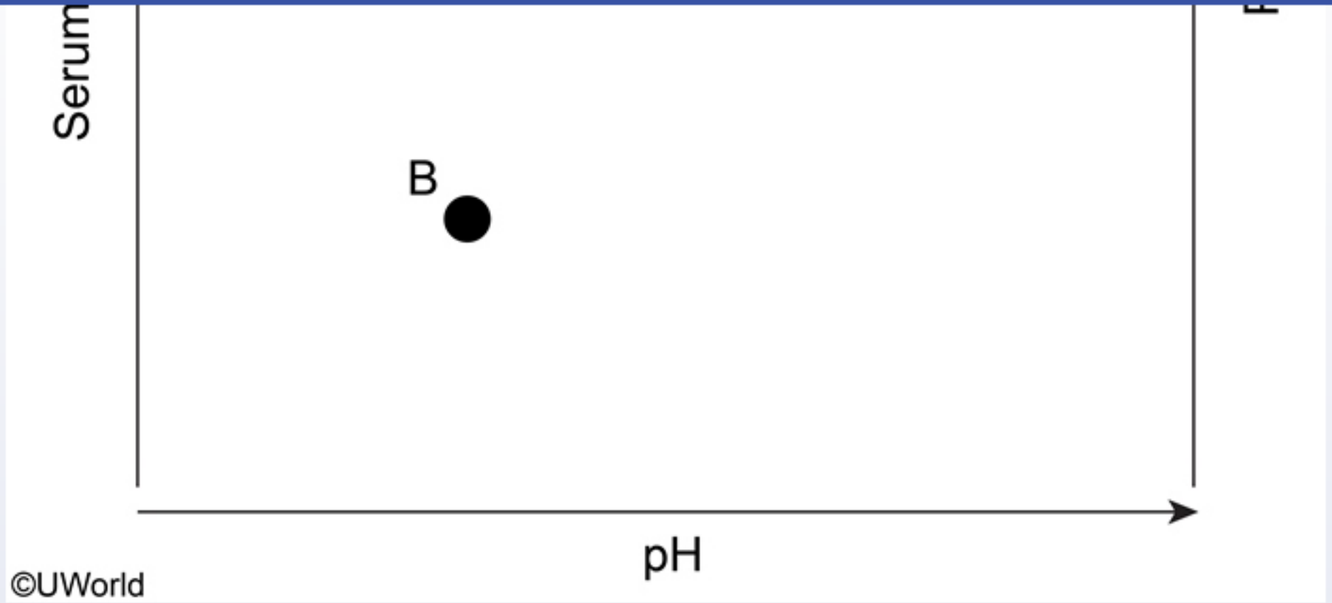

Item 1 of 2

Which of the following is the most likely diagnosis?

- ✓ A. Metabolic acidosis (86%)
- B. Metabolic alkalosis (6%)
- C. Respiratory acidosis (5%)
- D. Respiratory alkalosis (1%)

Omitted
Correct answer

86%

04 mins, 21 secs

04/26/2020

Arterial blood gas interpretation of acid-base disorders

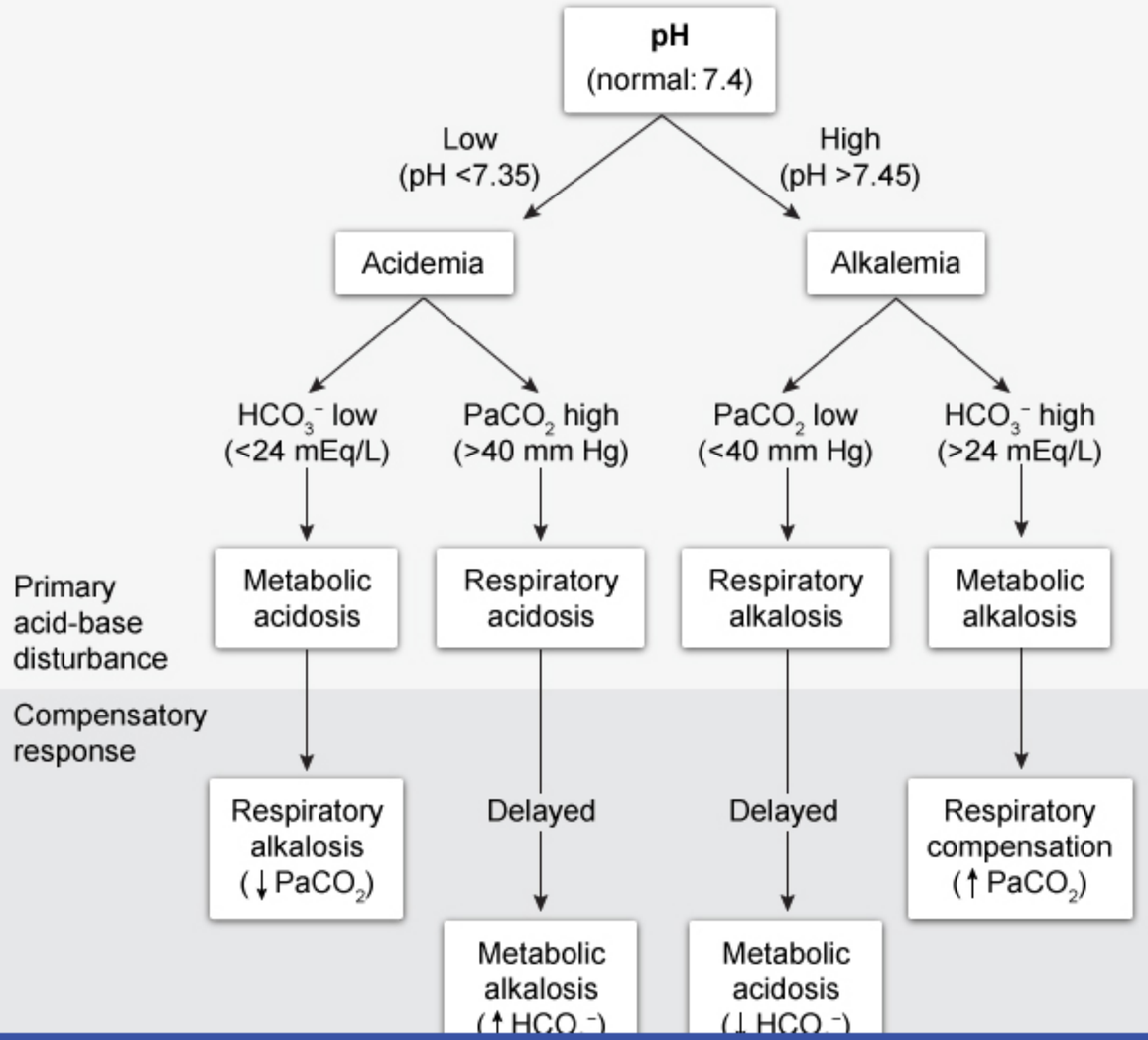

($\uparrow HCO_3^-$) ($\downarrow HCO_3^-$)

* The normal ranges for $PaCO_2$ and HCO_3^- vary slightly around 40 mm Hg and 24 mEq/L. For simplicity, these numbers should be used as a normal baseline for acid-base calculations.

HCO_3^- = bicarbonate; **$PaCO_2$** = partial pressure of carbon dioxide in arterial blood.

©UWorld

Point B on the graph above shows that this patient has a **decreased pH** compared to his baseline physiologic state, which indicates acidosis. The next step is to assess whether his acidosis is primarily metabolic or respiratory. A **decrease in serum bicarbonate** is characteristic of metabolic acidosis. It is usually associated with a **decrease in $PaCO_2$** as a result of respiratory compensation for the primary **metabolic acidosis**.

(Choice B) Metabolic alkalosis would be characterized by increased pH and serum bicarbonate. The $PaCO_2$ would also increase due to respiratory compensation.

(Choice C) Respiratory acidosis is characterized by decreased pH and increased $PaCO_2$. Plasma bicarbonate gradually increases to compensate for the primary respiratory acidosis (renal compensation). However, unlike respiratory compensation, this is a delayed response that occurs over 3-5 days.

(Choice D) Respiratory alkalosis is characterized by increased pH and decreased $PaCO_2$. Plasma bicarbonate gradually decreases to compensate for the primary respiratory alkalosis (renal compensation). However, unlike respiratory compensation, this is a delayed response that occurs over 3-5 days.

Educational objective:
Metabolic acidosis is characterized by a decrease in serum pH and serum bicarbonate. $PaCO_2$ will also decrease as a result of respiratory compensation for primary metabolic acidosis.

Pathology	Renal, Urinary Systems & Electrolytes	Diabetic ketoacidosis
Subject	System	Topic

Copyright © UWorld. All rights reserved.

Item 2 of 2

After determining that the patient has an increased anion gap metabolic acidosis, an appropriate treatment is instituted. Within several hours, the patient's mental status improves significantly. Repeat laboratory studies show an increase in serum bicarbonate and sodium levels, a decrease in serum osmolality, and a drop in the serum potassium level. Which of the following treatments was most likely given to this patient?

- A. Insulin and normal saline
- B. Loop diuretics
- C. Mineralocorticoid injection
- D. Opioid antagonists
- E. Thyroxine supplementation

Submit

Item 2 of 2

After determining that the patient has an increased anion gap metabolic acidosis, an appropriate treatment is instituted. Within several hours, the patient's mental status improves significantly. Repeat laboratory studies show an increase in serum bicarbonate and sodium levels, a decrease in serum osmolality, and a drop in the serum potassium level. Which of the following treatments was most likely given to this patient?

- ✓ A. Insulin and normal saline (65%)
- B. Loop diuretics (14%)
- C. Mineralocorticoid injection (19%)
- D. Opioid antagonists (0%)
- E. Thyroxine supplementation (0%)

Omitted
Correct answer
A

65%
Answered correctly

02 secs
Time Spent

04/26/2020
Last Updated

Explanation

1 2 3 4 5 6 7 8 9 10 11 12 13 14 15 16 17 18 19 20 21 22 23 24 25 26 27 28 29 30

Diabetic ketoacidosis

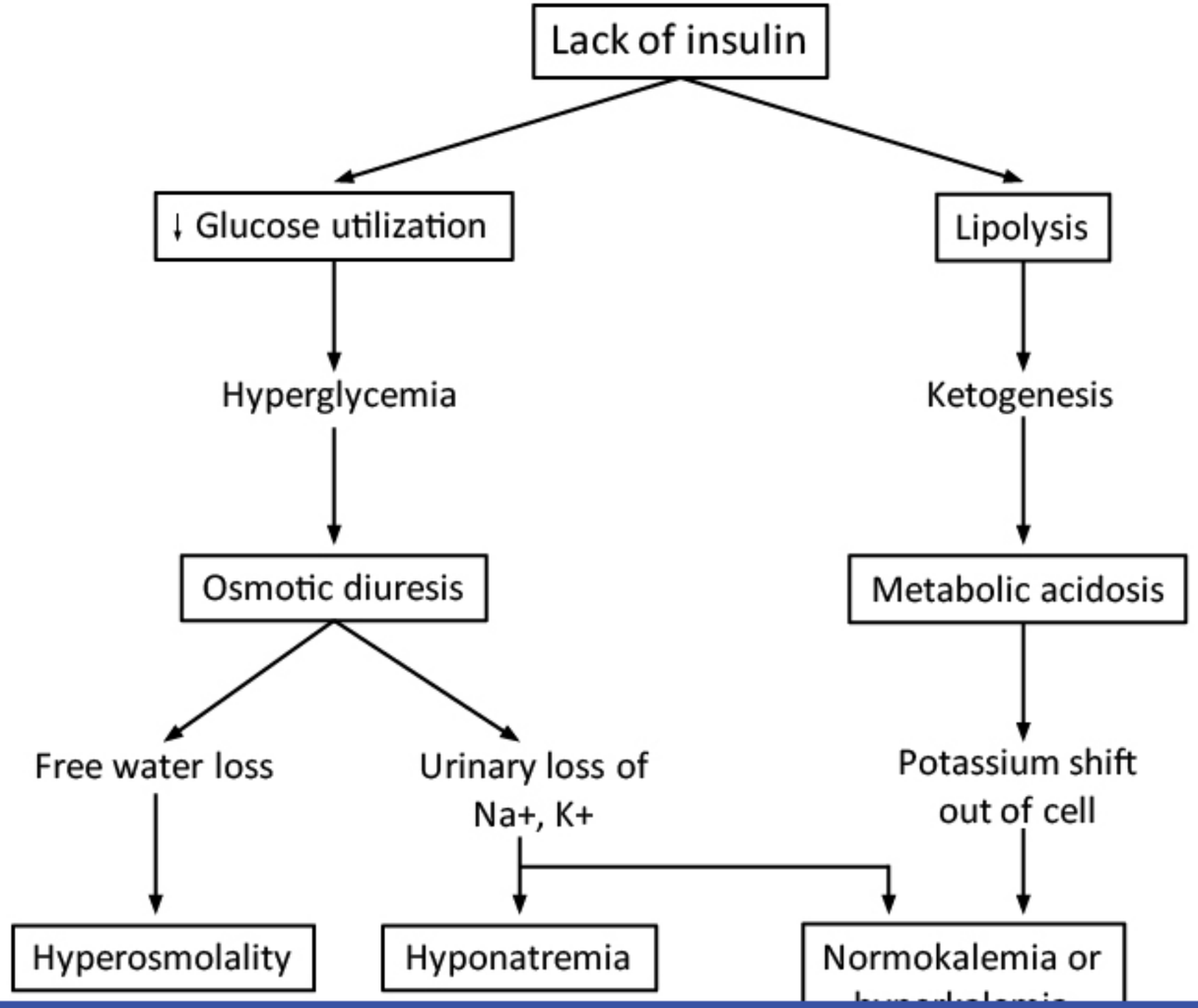

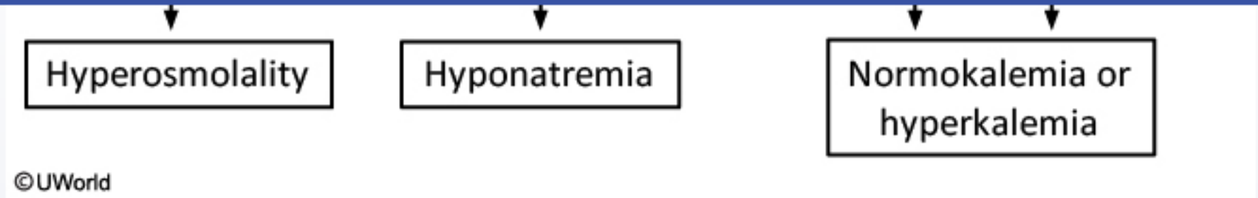

Based on the laboratory changes, this patient with an increased **anion gap metabolic acidosis** was most likely suffering from **diabetic ketoacidosis** (DKA). Patients classically have a fruity odor to the breath and often present with mental status changes, dehydration, abdominal pain, and tachypnea. Laboratory findings include hyperglycemia, ketosis, mild hyponatremia, normal or elevated serum potassium (despite a total body deficit), and increased plasma osmolality.

Insulin and hydration are the primary treatments for DKA. Insulin allows the cells to use glucose as an energy source, thereby decreasing lipolysis and production of ketone bodies. Because ketones are the principal acid produced in excess in patients with DKA, decreased production of ketone bodies will result in **increased serum bicarbonate**. Insulin also causes an intracellular shift of potassium, resulting in a decrease in the serum potassium level (which necessitates potassium repletion). In addition to insulin-induced changes, rehydration with normal saline will help normalize serum sodium concentration and decrease serum osmolality.

(Choice B) Loop diuretics could cause a decrease in potassium concentration as well as an increase in the serum concentration of bicarbonate. However, they also increase (not decrease) serum osmolality due to increased free water excretion (loop diuretics decrease the medullary concentration gradient, limiting the maximum tonicity of the urine).

(Choice C) Metabolic acidosis may develop in hypoaldosteronism (type 4 renal tubular acidosis), which is treated with exogenous mineralocorticoids. However, the combination of an increased anion gap and impaired mental status is not characteristic for hypoaldosteronism. Treatment with mineralocorticoids causes sodium and water retention with a mild increase in serum osmolality. Mineralocorticoids also decrease serum potassium and increase serum bicarbonate due to urinary K^+ and H^+ loss.

(Choice D) Opioid antagonists are useful in treating opioid overdoses, which typically cause respiratory acidosis (not anion gap metabolic acidosis) due to hypoventilation.

(Choice E) Thyroxine supplementation is useful in treating severe hypothyroidism, which may present with hyponatremia, extracellular volume expansion, and hypoglycemia.

Insulin and hydration are the primary treatments for DKA. Insulin allows the cells to use glucose as an energy source, thereby decreasing lipolysis and production of ketone bodies. Because ketones are the principal acid produced in excess in patients with DKA, decreased production of ketone bodies will result in **increased serum bicarbonate**. Insulin also causes an intracellular shift of potassium, resulting in a decrease in the serum potassium level (which necessitates potassium repletion). In addition to insulin-induced changes, rehydration with normal saline will help normalize serum sodium concentration and decrease serum osmolality.

(Choice B) Loop diuretics could cause a decrease in potassium concentration as well as an increase in the serum concentration of bicarbonate. However, they also increase (not decrease) serum osmolality due to increased free water excretion (loop diuretics decrease the medullary concentration gradient, limiting the maximum tonicity of the urine).

(Choice C) Metabolic acidosis may develop in hypoaldosteronism (type 4 renal tubular acidosis), which is treated with exogenous mineralocorticoids. However, the combination of an increased anion gap and impaired mental status is not characteristic for hypoaldosteronism. Treatment with mineralocorticoids causes sodium and water retention with a mild increase in serum osmolality. Mineralocorticoids also decrease serum potassium and increase serum bicarbonate due to urinary K^+ and H^+ loss.

(Choice D) Opioid antagonists are useful in treating opioid overdoses, which typically cause respiratory acidosis (not anion gap metabolic acidosis) due to hypoventilation.

(Choice E) Thyroxine supplementation is useful in treating severe hypothyroidism, which may present with hyponatremia, extracellular volume expansion, and hypoglycemia.

Educational objective:
The treatment of choice for diabetic ketoacidosis is intravenous normal saline and insulin. These therapies increase serum bicarbonate and sodium and decrease serum glucose, osmolality, and potassium.

Pathology	Renal, Urinary Systems & Electrolytes	Diabetic ketoacidosis
Subject	System	Topic

Copyright © UWorld. All rights reserved.

Insulin and hydration are the primary treatments for DKA. Insulin allows the cells to use glucose as an energy source, thereby decreasing

Exhibit Display

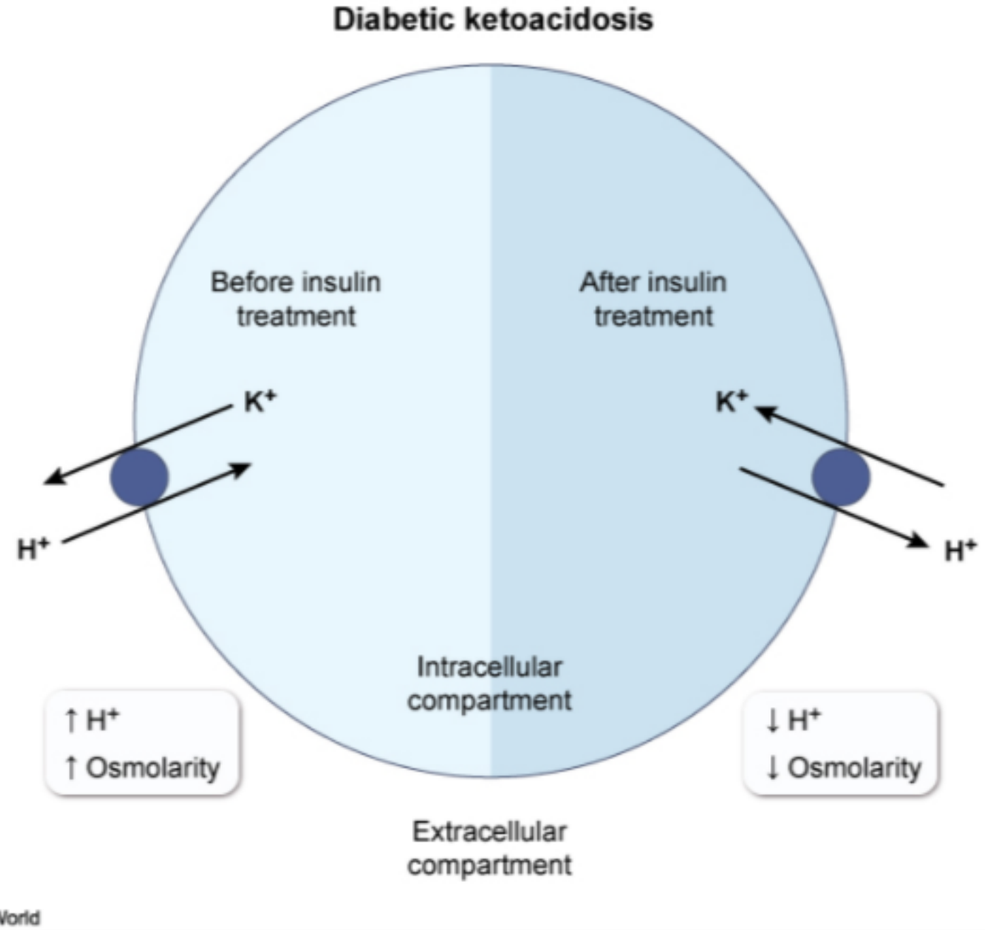

Zoom In | Zoom Out | Reset | Add To New Card | Existing Card

A 68-year-old man comes to the office due to episodes of gross hematuria over the last 3 months. Blood is present throughout micturition. The patient has no abdominal pain, dysuria, urinary frequency, or nocturia. Medical history includes type 2 diabetes mellitus, for which he takes metformin. The patient is retired, lives at home with his wife, and spends most of his free time working in his backyard greenhouse. Prior to retirement, he worked at a rubber manufacturing plant for 35 years. Vital signs are within normal limits. On examination, the abdomen is soft and nontender with no palpable masses. Serum creatinine is 1.1 mg/dL. Which of the following is most likely to be discovered on further workup of this patient's symptoms?

- A. Bladder cancer
- B. Glomerulonephritis
- C. Interstitial cystitis
- D. Polycystic kidney disease
- E. Prostate cancer
- F. Staghorn calculus

Submit

A 68-year-old man comes to the office due to episodes of gross hematuria over the last 3 months. Blood is present throughout micturition. The patient has no abdominal pain, dysuria, urinary frequency, or nocturia. Medical history includes type 2 diabetes mellitus, for which he takes metformin. The patient is retired, lives at home with his wife, and spends most of his free time working in his backyard greenhouse. Prior to retirement, he worked at a rubber manufacturing plant for 35 years. Vital signs are within normal limits. On examination, the abdomen is soft and nontender with no palpable masses. Serum creatinine is 1.1 mg/dL. Which of the following is most likely to be discovered on further workup of this patient's symptoms?

- ✓ A. Bladder cancer (87%)
- B. Glomerulonephritis (6%)
- C. Interstitial cystitis (2%)
- D. Polycystic kidney disease (0%)
- E. Prostate cancer (1%)
- F. Staghorn calculus (1%)

Omitted
Correct answer
A

87%
Answered correctly

02 secs
Time Spent

03/31/2020
Last Updated

Explanation

Specific cancer risk factors

Specific cancer risk factors			
Pancreas	• Tobacco smoke • Obesity	**Renal**	• Tobacco smoke • Obesity • Hypertension
Gastric	• Dietary nitrates • Alcohol & tobacco use • *Helicobacter pylori*	**Bladder**	• Tobacco smoke • Occupational exposures (rubber, plastics, aromatic amine-containing dyes, textiles, leather)
Liver	• Hepatitis B & C • Liver cirrhosis (any cause) • Hemochromatosis • Aflatoxin	**Breast**	• Early menarche • Late menopause • Nulliparity • *BRCA* mutations
Colorectal	• Hereditary CRC syndromes • Inflammatory bowel disease • Obesity • Charred or fried foods	**Prostate**	• Increasing age • African-American

CRC = colorectal cancer.

This patient has intermittent, **painless gross hematuria**. In an older patient, this presentation raises suspicion for urinary tract cancer, especially **urothelial (transitional cell) bladder cancer** (UBC). The diagnosis of UBC can be confirmed by identifying erythematous sessile, nodular, or papillary lesions on cystoscopy. The malignant epithelial cells are pleomorphic and have hyperchromatic nuclei, an increased nucleus/cytoplasm ratio, and disrupted orientation and polarity (in relation to the basal membrane). Frequent mitotic figures may be present.

UBC is most common in patients age >60, with men affected more often than women. Major risk factors include **cigarette smoking** and **occupational exposure** to rubber, plastics, aromatic amine–containing dyes, textiles, or leather. Cyclophosphamide therapy (eg, for lymphoma,

CRC = colorectal cancer.

This patient has intermittent, **painless gross hematuria**. In an older patient, this presentation raises suspicion for urinary tract cancer, especially **urothelial (transitional cell) bladder cancer** (UBC). The diagnosis of UBC can be confirmed by identifying erythematous sessile, nodular, or papillary lesions on cystoscopy. The malignant epithelial cells are pleomorphic and have hyperchromatic nuclei, an increased nucleus/cytoplasm ratio, and disrupted orientation and polarity (in relation to the basal membrane). Frequent mitotic figures may be present.

UBC is most common in patients age >60, with men affected more often than women. Major risk factors include **cigarette smoking** and **occupational exposure** to rubber, plastics, aromatic amine–containing dyes, textiles, or leather. Cyclophosphamide therapy (eg, for lymphoma, autoimmune disorders) also increases the risk. In Africa and the Middle East, infection with *Schistosoma haematobium* is associated with multiple cell types of bladder cancer, including UBC and squamous cell carcinoma.

(Choice B) Glomerulonephritis (of various etiologies) can cause grossly red or tea-colored urine but more commonly causes microscopic hematuria with red cell casts and dysmorphic red blood cells.

(Choice C) Interstitial cystitis is characterized by bladder pain, urinary frequency, and dysuria. Gross hematuria is not typical.

(Choice D) Autosomal dominant polycystic kidney disease can cause hypertension, hematuria, and renal insufficiency. However, hypertension is usually present by age 40, and this patient has no other suggestive features (eg, renal insufficiency, palpable kidneys).

(Choice E) Prostate cancer is typically asymptomatic or discovered on evaluation for lower urinary tract voiding symptoms (eg, decreased force of stream, nocturia). Painless hematuria without voiding symptoms is more suggestive of bladder cancer.

(Choice F) Staghorn calculi are large magnesium ammonium phosphate (struvite) stones that fill the renal calyces. Although they may cause hematuria, they are typically seen in patients with recurrent urinary tract infections by urease-producing bacteria (eg, *Proteus*, *Klebsiella*).

Educational objective:
Urothelial (transitional cell) bladder cancer typically affects the elderly and presents with gross hematuria. A history of smoking or occupational exposure to rubber, plastics, aromatic amine–containing dyes, textiles, or leather increases the risk.

References

- Epidemiology and risk factors of urothelial bladder cancer.

UBC is most common in patients age >60, with men affected more often than women. Major risk factors include **cigarette smoking** and **occupational exposure** to rubber, plastics, aromatic amine–containing dyes, textiles, or leather. Cyclophosphamide therapy (eg, for lymphoma, autoimmune disorders) also increases the risk. In Africa and the Middle East, infection with *Schistosoma haematobium* is associated with multiple cell types of bladder cancer, including UBC and squamous cell carcinoma.

(Choice B) Glomerulonephritis (of various etiologies) can cause grossly red or tea-colored urine but more commonly causes microscopic hematuria with red cell casts and dysmorphic red blood cells.

(Choice C) Interstitial cystitis is characterized by bladder pain, urinary frequency, and dysuria. Gross hematuria is not typical.

(Choice D) Autosomal dominant polycystic kidney disease can cause hypertension, hematuria, and renal insufficiency. However, hypertension is usually present by age 40, and this patient has no other suggestive features (eg, renal insufficiency, palpable kidneys).

(Choice E) Prostate cancer is typically asymptomatic or discovered on evaluation for lower urinary tract voiding symptoms (eg, decreased force of stream, nocturia). Painless hematuria without voiding symptoms is more suggestive of bladder cancer.

(Choice F) Staghorn calculi are large magnesium ammonium phosphate (struvite) stones that fill the renal calyces. Although they may cause hematuria, they are typically seen in patients with recurrent urinary tract infections by urease-producing bacteria (eg, *Proteus*, *Klebsiella*).

Educational objective:
Urothelial (transitional cell) bladder cancer typically affects the elderly and presents with gross hematuria. A history of smoking or occupational exposure to rubber, plastics, aromatic amine–containing dyes, textiles, or leather increases the risk.

References

- Epidemiology and risk factors of urothelial bladder cancer.

Pathology	Renal, Urinary Systems & Electrolytes	Bladder cancer
Subject	System	Topic

Copyright © UWorld. All rights reserved.

Settings

Item 3 of 40
Question Id: 7623

Mark | Previous | Next | Full Screen | Tutorial | Lab Values | Notes | Calculator | Reverse Color | Text Zoom | Settings

- Hereditary CRC syndromes

Exhibit Display

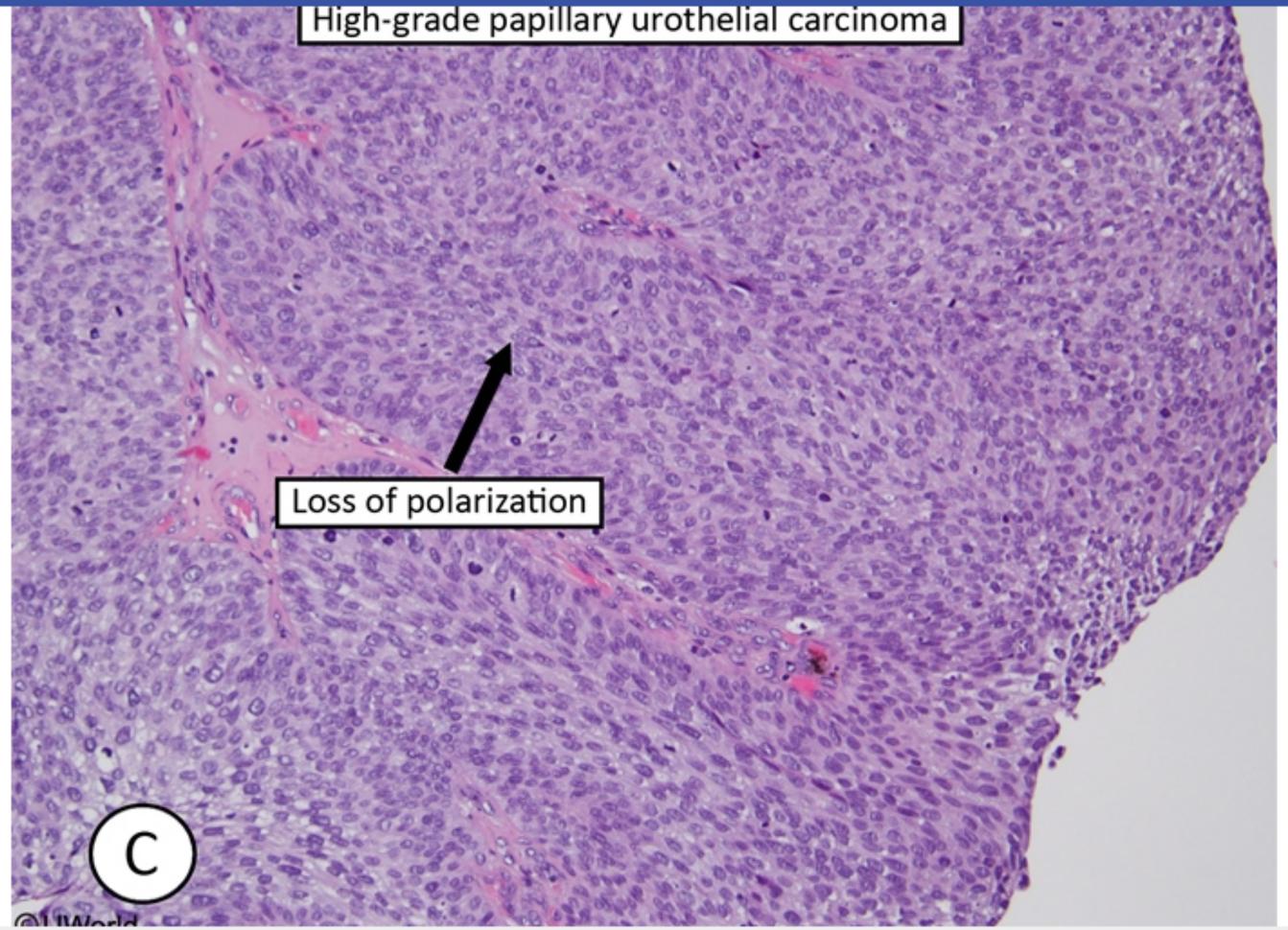

Zoom In | Zoom Out | Reset | Add To New Card | Existing Card

Educational objective:

Block Time Remaining: 00:04:25
TUTOR

4 | Feedback | Suspend | End Block

1
2
3
4
5
6
7
8
9
10
11
12
13
14
15
16
17
18
19
20
21
22
23
24
25
26
27
28
29
30

- Hereditary CRC syndromes

Exhibit Display

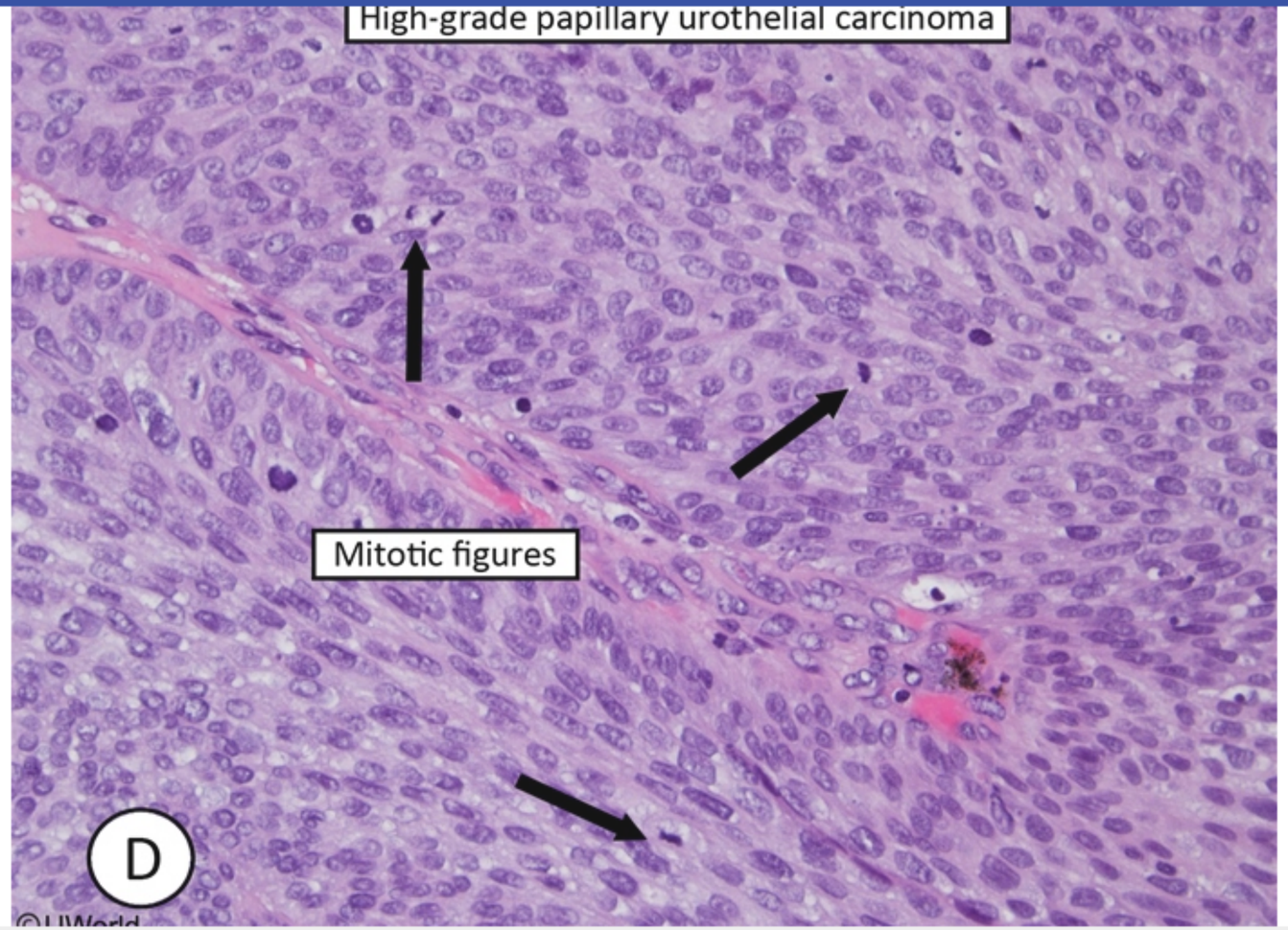

Zoom In | Zoom Out | Reset | Add To New Card | Existing Card

Educational objective:

A 68-year-old man comes to the office due to a weak urinary stream, hesitancy, and straining on micturition. These symptoms have been present for the past 2 years but have gradually become more severe and are beginning to affect his quality of life. The patient recently started noticing continuous urine leakage, nocturia, polyuria, and urgency. He has no other medical problems and takes no medications. The patient does not use tobacco or alcohol. He is a business management consultant and motivational speaker. Vital signs are normal. BMI is 27 kg/m^2. The patient's kidneys are most likely to demonstrate which of the following findings?

A. Glomerular sclerosis and hyalinosis

B. Hyperplastic arteriolar changes

C. Ischemic tubular necrosis

D. Parenchymal pressure atrophy

E. Tubular epithelial dysplasia

Submit

A 68-year-old man comes to the office due to a weak urinary stream, hesitancy, and straining on micturition. These symptoms have been present for the past 2 years but have gradually become more severe and are beginning to affect his quality of life. The patient recently started noticing continuous urine leakage, nocturia, polyuria, and urgency. He has no other medical problems and takes no medications. The patient does not use tobacco or alcohol. He is a business management consultant and motivational speaker. Vital signs are normal. BMI is 27 kg/m^2. The patient's kidneys are most likely to demonstrate which of the following findings?

- A. Glomerular sclerosis and hyalinosis (9%)
- B. Hyperplastic arteriolar changes (6%)
- C. Ischemic tubular necrosis (2%)
- ✓ D. Parenchymal pressure atrophy (75%)
- E. Tubular epithelial dysplasia (6%)

Omitted
Correct answer
D

75%
Answered correctly

02 secs
Time Spent

03/21/2020
Last Updated

Explanation

Male urogenital anatomy

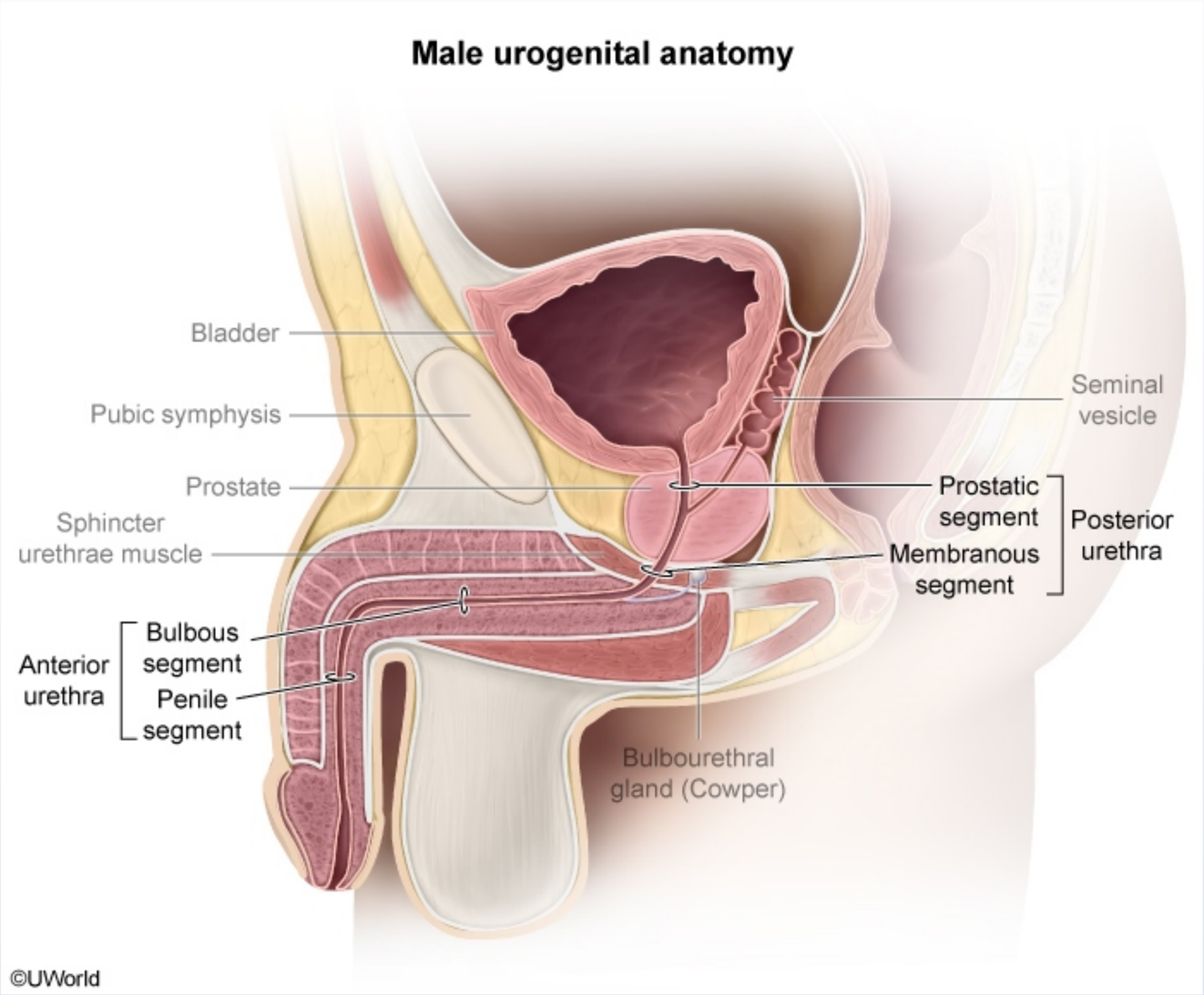

This patient has progressive lower urinary tract symptoms, likely due to **benign prostatic hyperplasia** (BPH). BPH is common in older men and

©UWorld

This patient has progressive lower urinary tract symptoms, likely due to **benign prostatic hyperplasia** (BPH). BPH is common in older men and is characterized by a combination of epithelial and stromal hyperplasia, predominantly in the periurethral and transition zones. On palpation, the prostate has a rubbery consistency, in contrast to prostate cancer, in which the gland is nodular and very firm.

As the prostate enlarges it impinges on the prostatic urethra, causing progressively worsening **bladder outlet obstruction**. This leads to problems voiding (eg, hesitancy, straining, weak urinary stream) and impaired urine storage (eg, daytime frequency, urgency, nocturia). As BPH progresses, incomplete bladder emptying leads to overflow incontinence (involuntary urine spillage from an overly full bladder). Increased hydrostatic force is needed to overcome the obstruction, causing hypertrophy of the bladder wall musculature and dilation of the ureters, renal pelvis, and calyces (**hydronephrosis**). If left untreated, urinary reflux can lead to significant pressure-induced **parenchymal atrophy** with scarring and eventual **chronic kidney disease**.

(Choice A) Glomerular sclerosis and hyalinosis are typical of diabetic nephrosclerosis and focal segmental glomerulosclerosis (FSGS). Diabetes can cause autonomic neuropathy with overflow incontinence, but it is rare and typically occurs in poorly controlled chronic diabetes. FSGS does not cause lower urinary tract symptoms.

(Choice B) Hyperplastic arteriolar changes are seen in severe (malignant) hypertension. Hypertension does not cause lower urinary tract symptoms. Additionally, this patient does not have a history of high blood pressure or symptoms associated with malignant hypertension (eg, headache, blurred vision).

(Choice C) Ischemic tubular necrosis results from decreased renal perfusion (eg, sepsis, hemorrhage, heart failure). Patients develop oliguria, azotemia (elevated blood levels of nitrogenous wastes), elevated serum creatinine, and electrolyte disturbances.

(Choice E) Epithelial dysplasia (eg, alterations in cell shape and size, nuclei size, and staining) is considered a precursor of malignancy. BPH does not predispose to renal tubular dysplasia or prostate cancer.

Educational objective:
Benign prostatic hyperplasia leads to progressive bladder outlet obstruction. Over time, increased urinary pressures can cause hydronephrosis and renal parenchymal atrophy with scarring. This can progress to chronic kidney disease.

As the prostate enlarges it impinges on the prostatic urethra, causing progressively worsening **bladder outlet obstruction**. This leads to problems voiding (eg, hesitancy, straining, weak urinary stream) and impaired urine storage (eg, daytime frequency, urgency, nocturia). As BPH progresses, incomplete bladder emptying leads to overflow incontinence (involuntary urine spillage from an overly full bladder). Increased hydrostatic force is needed to overcome the obstruction, causing hypertrophy of the bladder wall musculature and dilation of the ureters, renal pelvis, and calyces (**hydronephrosis**). If left untreated, urinary reflux can lead to significant pressure-induced **parenchymal atrophy** with scarring and eventual **chronic kidney disease**.

(Choice A) Glomerular sclerosis and hyalinosis are typical of diabetic nephrosclerosis and focal segmental glomerulosclerosis (FSGS). Diabetes can cause autonomic neuropathy with overflow incontinence, but it is rare and typically occurs in poorly controlled chronic diabetes. FSGS does not cause lower urinary tract symptoms.

(Choice B) Hyperplastic arteriolar changes are seen in severe (malignant) hypertension. Hypertension does not cause lower urinary tract symptoms. Additionally, this patient does not have a history of high blood pressure or symptoms associated with malignant hypertension (eg, headache, blurred vision).

(Choice C) Ischemic tubular necrosis results from decreased renal perfusion (eg, sepsis, hemorrhage, heart failure). Patients develop oliguria, azotemia (elevated blood levels of nitrogenous wastes), elevated serum creatinine, and electrolyte disturbances.

(Choice E) Epithelial dysplasia (eg, alterations in cell shape and size, nuclei size, and staining) is considered a precursor of malignancy. BPH does not predispose to renal tubular dysplasia or prostate cancer.

Educational objective:
Benign prostatic hyperplasia leads to progressive bladder outlet obstruction. Over time, increased urinary pressures can cause hydronephrosis and renal parenchymal atrophy with scarring. This can progress to chronic kidney disease.

Pathology	Renal, Urinary Systems & Electrolytes	Benign prostatic hyperplasia
Subject	System	Topic

Copyright © UWorld. All rights reserved.

A 3-month-old boy is brought to the office due to fussiness, poor weight gain, and polyuria. Urine volume is 700-800 mL/day. The patient's maternal grandfather has polydipsia and polyuria. Serum sodium is 151 mEq/L. Genetic testing reveals a vasopressin-2 receptor mutation. Which of the following additional findings is most likely to be seen in this patient?

	Serum osmolality	Urine osmolality after water deprivation	Change in urine osmolality with desmopressin administration
A.	High	Low	No change
B.	High	High	No change
C.	High	Low	Increased
D.	Low	High	No change
E.	Low	Low	No change
F.	Low	Low	Increased

Submit

A 3-month-old boy is brought to the office due to fussiness, poor weight gain, and polyuria. Urine volume is 700-800 mL/day. The patient's maternal grandfather has polydipsia and polyuria. Serum sodium is 151 mEq/L. Genetic testing reveals a vasopressin-2 receptor mutation. Which of the following additional findings is most likely to be seen in this patient?

	Serum osmolality	Urine osmolality after water deprivation	Change in urine osmolality with desmopressin administration
✓ A. (70%)	High	Low	No change
B. (12%)	High	High	No change
C. (7%)	High	Low	Increased
D. (4%)	Low	High	No change
E. (5%)	Low	Low	No change
F. (1%)	Low	Low	Increased

Omitted
Correct answer

70%
Answered correctly

02 secs
Time Spent

03/05/2020
Last Updated

Polyuria & polydipsia			
	Baseline serum osmolality	Water deprivation test	
		Urine osmolality after water deprivation	Urine osmolality with vasopressin injection
Normal	Normal	Increased	No change
Central diabetes insipidus	High	No change	Increased
Nephrogenic diabetes insipidus	High	No change	No change
Primary polydipsia	Low	Increased	No change

This patient with a vasopressin-2 (V2) receptor mutation has polyuria and hypernatremia, findings which are consistent with congenital **nephrogenic diabetes insipidus** (DI).

V2 receptors are located in the renal cortical collecting ducts. When serum osmolality rises (eg, water deprivation, dehydration), there is increased release of antidiuretic hormone (ADH, vasopressin) which activates V2 receptors to reabsorb water into the systemic circulation. Water reabsorption leads to concentrated urine (low urinary volume, high urine osmolality) and lower serum osmolality.

Mutations that impair normal V2 receptor function result in nephrogenic DI (**ADH resistance**). Following water deprivation, the collecting ducts are unable to reabsorb water despite high circulating ADH levels, leading to ongoing urinary water losses. Therefore, nephrogenic DI manifests with large volumes of abnormally **dilute urine** (ie, polyuria with low urine osmolality), **high serum osmolality** (ie, hypernatremia), and dehydration.

High serum osmolality, polyuria, and dilute urine also occur in central DI, which is caused by deficient ADH production by the hypothalamus. As

This patient with a vasopressin-2 (V2) receptor mutation has polyuria and hypernatremia, findings which are consistent with congenital **nephrogenic diabetes insipidus** (DI).

V2 receptors are located in the renal cortical collecting ducts. When serum osmolality rises (eg, water deprivation, dehydration), there is increased release of antidiuretic hormone (ADH, vasopressin) which activates V2 receptors to reabsorb water into the systemic circulation. Water reabsorption leads to concentrated urine (low urinary volume, high urine osmolality) and lower serum osmolality.

Mutations that impair normal V2 receptor function result in nephrogenic DI (**ADH resistance**). Following water deprivation, the collecting ducts are unable to reabsorb water despite high circulating ADH levels, leading to ongoing urinary water losses. Therefore, nephrogenic DI manifests with large volumes of abnormally **dilute urine** (ie, polyuria with low urine osmolality), **high serum osmolality** (ie, hypernatremia), and dehydration.

High serum osmolality, polyuria, and dilute urine also occur in central DI, which is caused by deficient ADH production by the hypothalamus. As with nephrogenic DI, urine remains abnormally dilute after water deprivation. However, **challenge with desmopressin** (an analogue of ADH) can differentiate between central and nephrogenic DI:

- In nephrogenic DI, desmopressin cannot correct the underlying ADH resistance. Therefore, **urine osmolality remains unchanged** (eg, low).
- In **central DI**, desmopressin corrects the underlying ADH deficiency. Therefore, **urine osmolality increases** following administration **(Choice C)**.

(Choice B) High baseline serum osmolality and high urine osmolality can be seen in states of marked hyperglycemia with glucosuria (ie, solute diuresis). Although polyuria can occur, the ADH response remains intact, so urine osmolality will be high with water deprivation.

(Choice D) Primary polydipsia can also result in polyuria with dilute urine. However, unlike DI, serum osmolality and sodium are low (due to excess water intake), and dilute urine represents an appropriate physiologic response. ADH response is intact, so urine osmolality is appropriately high following water deprivation. No additional change is seen with desmopressin because maximum ADH levels are reached with water deprivation.

(Choices E and F) This patient has visible signs of dehydration and hypernatremia; because sodium is a major determinant of serum osmolality, a high serum osmolality is expected.

High serum osmolality, polyuria, and dilute urine also occur in central DI, which is caused by deficient ADH production by the hypothalamus. As with nephrogenic DI, urine remains abnormally dilute after water deprivation. However, **challenge with desmopressin** (an analogue of ADH) can differentiate between central and nephrogenic DI:

- In nephrogenic DI, desmopressin cannot correct the underlying ADH resistance. Therefore, **urine osmolality remains unchanged** (eg, low).
- In **central DI**, desmopressin corrects the underlying ADH deficiency. Therefore, **urine osmolality increases** following administration **(Choice C)**.

(Choice B) High baseline serum osmolality and high urine osmolality can be seen in states of marked hyperglycemia with glucosuria (ie, solute diuresis). Although polyuria can occur, the ADH response remains intact, so urine osmolality will be high with water deprivation.

(Choice D) Primary polydipsia can also result in polyuria with dilute urine. However, unlike DI, serum osmolality and sodium are low (due to excess water intake), and dilute urine represents an appropriate physiologic response. ADH response is intact, so urine osmolality is appropriately high following water deprivation. No additional change is seen with desmopressin because maximum ADH levels are reached with water deprivation.

(Choices E and F) This patient has visible signs of dehydration and hypernatremia; because sodium is a major determinant of serum osmolality, a high serum osmolality is expected.

Educational objective:
Vasopressin-2 gene mutations are a cause of congenital nephrogenic diabetes insipidus, a condition in which renal resistance to antidiuretic hormone results in excessive urinary water losses. Expected findings include high baseline serum osmolality (typically with hypernatremia), persistently dilute urine after water deprivation (low urine osmolality), and lack of response to desmopressin.

Pathology	Renal, Urinary Systems & Electrolytes	Diabetes insipidus
Subject	System	Topic

Copyright © UWorld. All rights reserved.

A 42-year-old man comes to the office for evaluation of progressive generalized edema and weight gain for the past several weeks. He has no chest pain or shortness of breath. The patient has no chronic medical conditions and takes no medications. He last saw a physician a year ago for an upper respiratory infection. The patient does not use tobacco, alcohol, or illicit drugs. Blood pressure is 130/80 mm Hg and pulse is 84/min. Mild ascites is present. There is bilateral lower extremity pitting edema to the knees.

Laboratory results are as follows:

Serum chemistry	
Albumin	2.2 g/dL
Creatinine	1.0 mg/dL
Urinalysis	
Blood	negative
Protein	4+
Red blood cells	1-2/hpf
White blood cells	1/2/hpf

Urinary protein excretion is 6.0 g/24 hr. A kidney biopsy is performed, and electron microscopy of a glomerular capillary is shown below:

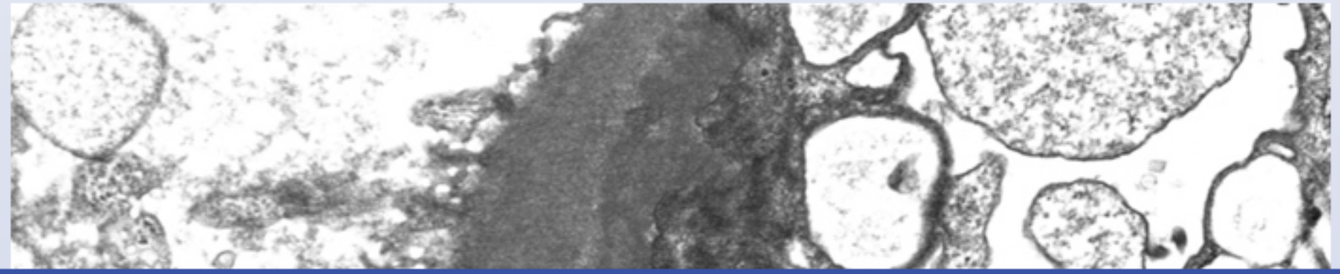

Urinary protein excretion is 6.0 g/24 hr. A kidney biopsy is performed, and electron microscopy of a glomerular capillary is shown below:

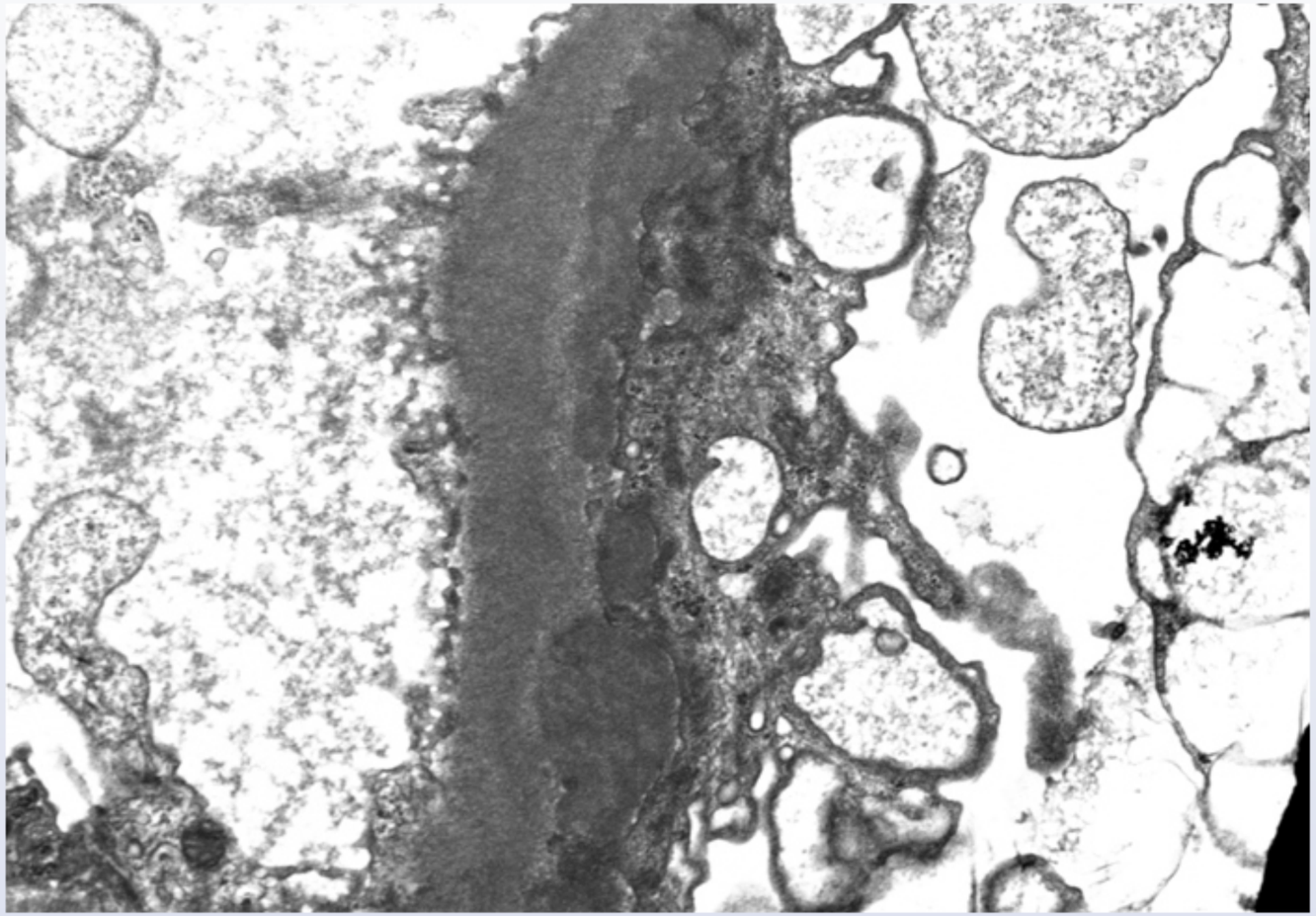

Which of the following is the most likely diagnosis?

A. Crescentic glomerulonephritis

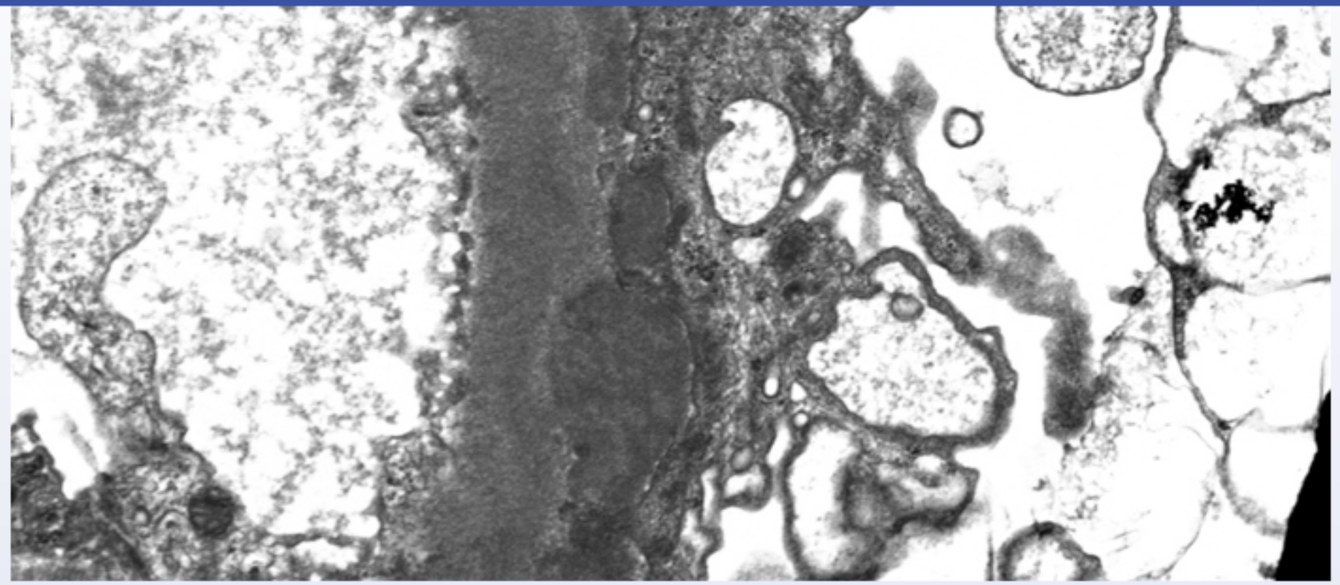

Which of the following is the most likely diagnosis?

- A. Crescentic glomerulonephritis
- B. Focal segmental glomerulosclerosis
- C. Membranous nephropathy
- D. Minimal change disease
- E. Poststreptococcal glomerulonephritis

Submit

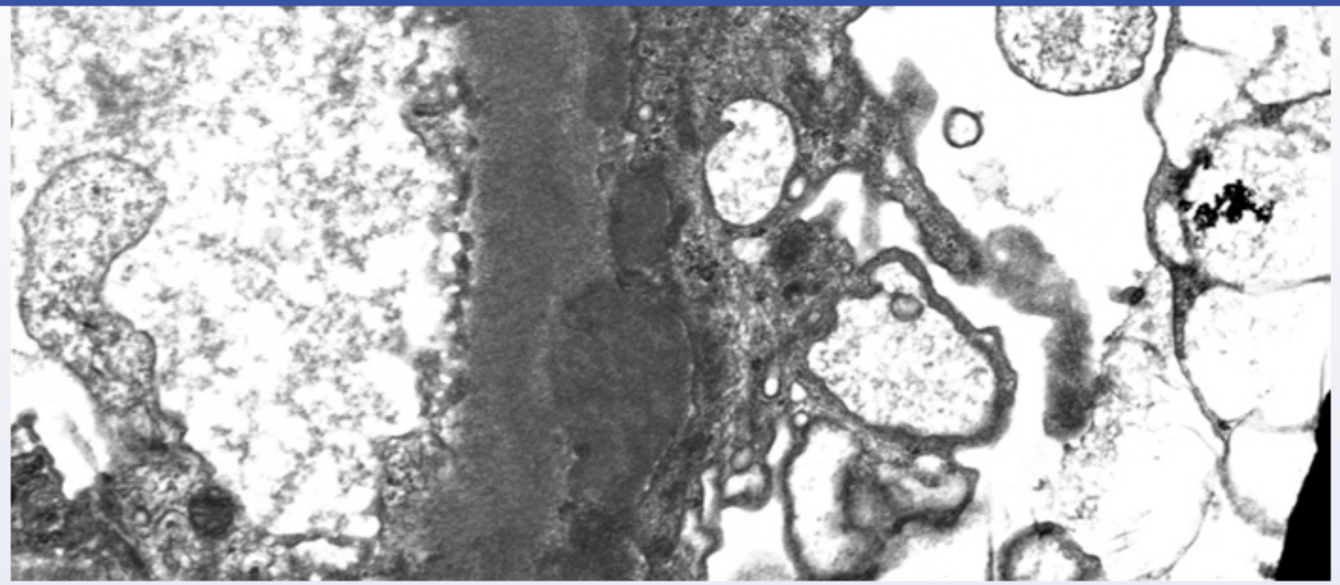

Which of the following is the most likely diagnosis?

A. Crescentic glomerulonephritis (2%)

B. Focal segmental glomerulosclerosis (11%)

✓ C. Membranous nephropathy (75%)

D. Minimal change disease (5%)

E. Poststreptococcal glomerulonephritis (4%)

Omitted
Correct answer

75%
Answered correctly

06 secs
Time Spent

05/20/2020
Last Updated

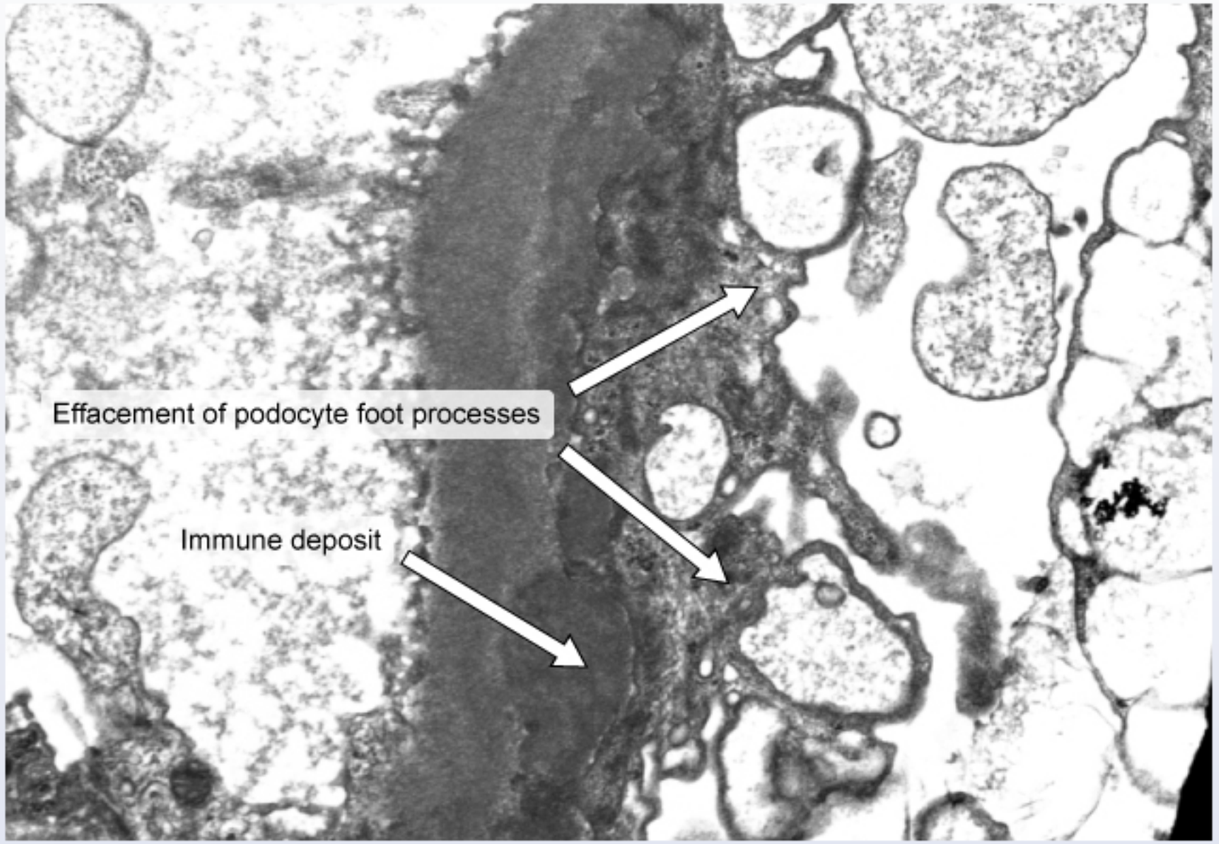

This patient has **nephrotic syndrome**, characterized by generalized edema, heavy proteinuria (>3.5 g/day), and hypoalbuminemia. Electron microscopy (EM) of the glomerular capillary demonstrates irregular, electron-dense **immune deposits** located on the glomerular basement membrane (GBM) with moderate **effacement of the podocyte foot processes**, consistent with **membranous nephropathy** (MN). MN results from immune-complex deposition in the subepithelial portions of the GBM. Light microscopy demonstrates diffuse glomerular capillary wall thickening without hypercellularity, whereas silver staining reveals "**spikes and domes**" of GBM that protrude between the immune deposits (which do not stain). Immunofluorescence microscopy demonstrates a diffuse granular pattern of IgG and C3 along the capillary loops.

MN is one of the most common causes of nephrotic syndrome in adults. Primary (idiopathic) MN is thought to be caused by autoantibodies

This patient has **nephrotic syndrome**, characterized by generalized edema, heavy proteinuria (>3.5 g/day), and hypoalbuminemia. Electron microscopy (EM) of the glomerular capillary demonstrates irregular, electron-dense **immune deposits** located on the glomerular basement membrane (GBM) with moderate **effacement of the podocyte foot processes**, consistent with **membranous nephropathy** (MN). MN results from immune-complex deposition in the subepithelial portions of the GBM. Light microscopy demonstrates diffuse glomerular capillary wall thickening without hypercellularity, whereas silver staining reveals "**spikes and domes**" of GBM that protrude between the immune deposits (which do not stain). Immunofluorescence microscopy demonstrates a diffuse granular pattern of IgG and C3 along the capillary loops.

MN is one of the most common causes of nephrotic syndrome in adults. Primary (idiopathic) MN is thought to be caused by autoantibodies directed at the phospholipase A2 receptor, whereas secondary MN can be associated with a variety of conditions including systemic lupus erythematosus, viral hepatitis, and solid tumors.

(Choices A and E) Crescentic glomerulonephritis (GN) and poststreptococcal GN are nephritic diseases that are characterized by hematuria, red blood cell casts, and hypertension, not heavy proteinuria. Poststreptococcal GN typically occurs in children two to four weeks after a group A streptococcal infection, and EM demonstrates large, subepithelial immune-complex "humps." Crescentic (rapidly progressive) GN can occur in a number of diseases (eg, anti-GBM disease, antineutrophil cytoplasmic antibody vasculitis). Proliferative crescents are visible on light microscopy, and EM may demonstrate rupture of the GBM.

(Choice B) Focal segmental glomerulosclerosis also causes nephrotic syndrome but is characterized by sclerosis and hyalinosis of portions of some, but not all, glomeruli. EM demonstrates diffuse foot process effacement; however, immune deposits (if present) typically occur in the sclerotic region of the glomerulus, not along the GBM.

(Choice D) Minimal change disease causes nephrotic syndrome but occurs more commonly in children. EM demonstrates extensive, diffuse effacement of the foot processes, and immune complexes are not seen.

Educational objective:
Membranous nephropathy is a common cause of nephrotic syndrome in adults. Electron microscopy of the glomerular capillary demonstrates irregular, subepithelial, electron-dense immune deposits on the glomerular basement membrane with moderate effacement of the podocyte foot processes; immunofluorescence microscopy demonstrates a diffuse granular pattern of IgG along the capillary loops.

Settings

1
2
3
4
5
6
7
8
9
10
11
12
13
14
15
16
17
18
19
20
21
22
23
24
25
26
27
28
29
30

Item 6 of 40
Question Id: 15346

Mark | Previous | Next | Full Screen | Tutorial | Lab Values | Notes | Calculator | Reverse Color | Text Zoom | Settings

Exhibit Display

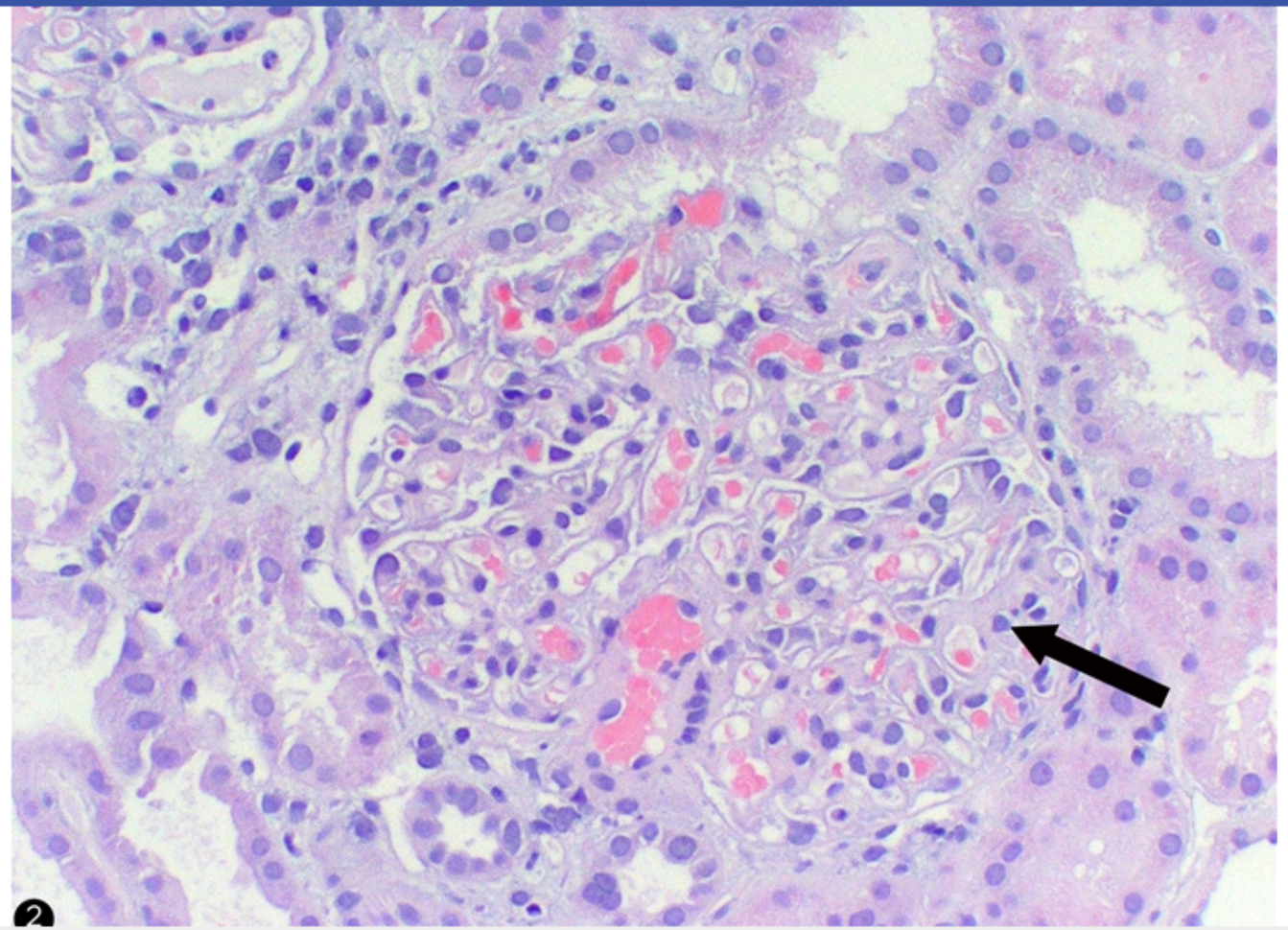

Zoom In | Zoom Out | Reset | Add To New Card | Existing Card

Block Time Remaining: 00:04:35
TUTOR

5 | Feedback | Suspend | End Block

Exhibit Display

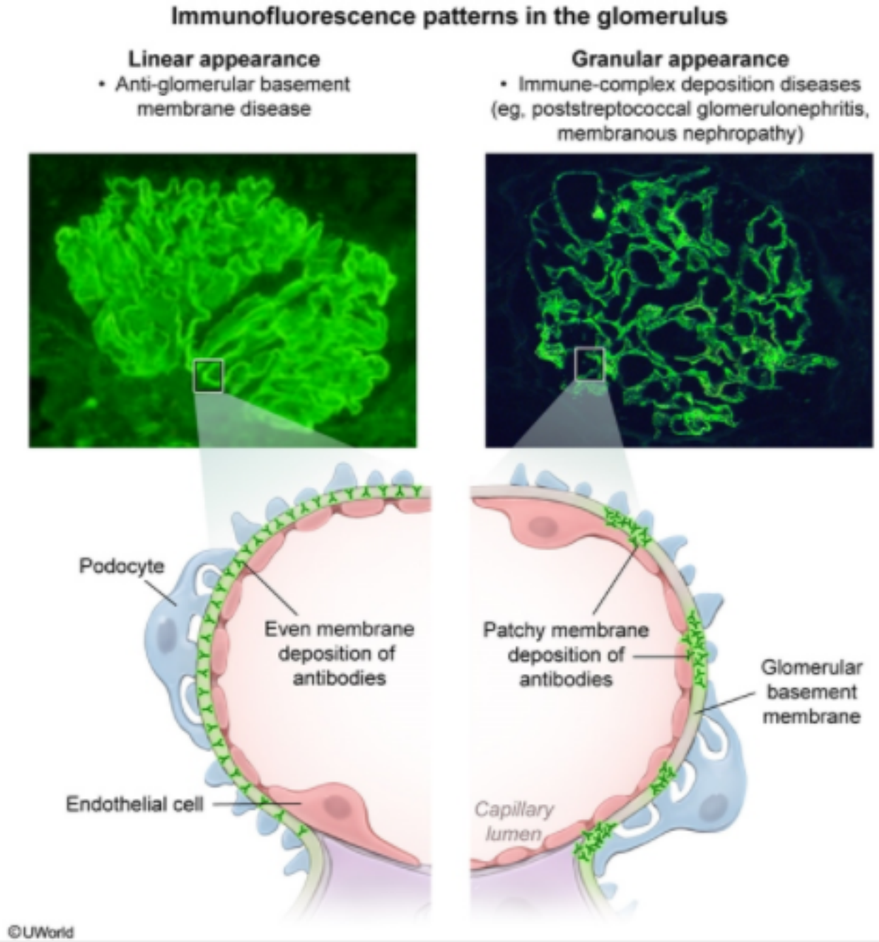

Zoom In | Zoom Out | Reset | Add To New Card | Existing Card

Settings

1
2
3
4
5
6
7
8
9
10
11
12
13
14
15
16
17
18
19
20
21
22
23
24
25
26
27
28
29
30

Item 6 of 40
Question Id: 15346

Mark | Previous | Next | Full Screen | Tutorial | Lab Values | Notes | Calculator | Reverse Color | Text Zoom | Settings

Exhibit Display

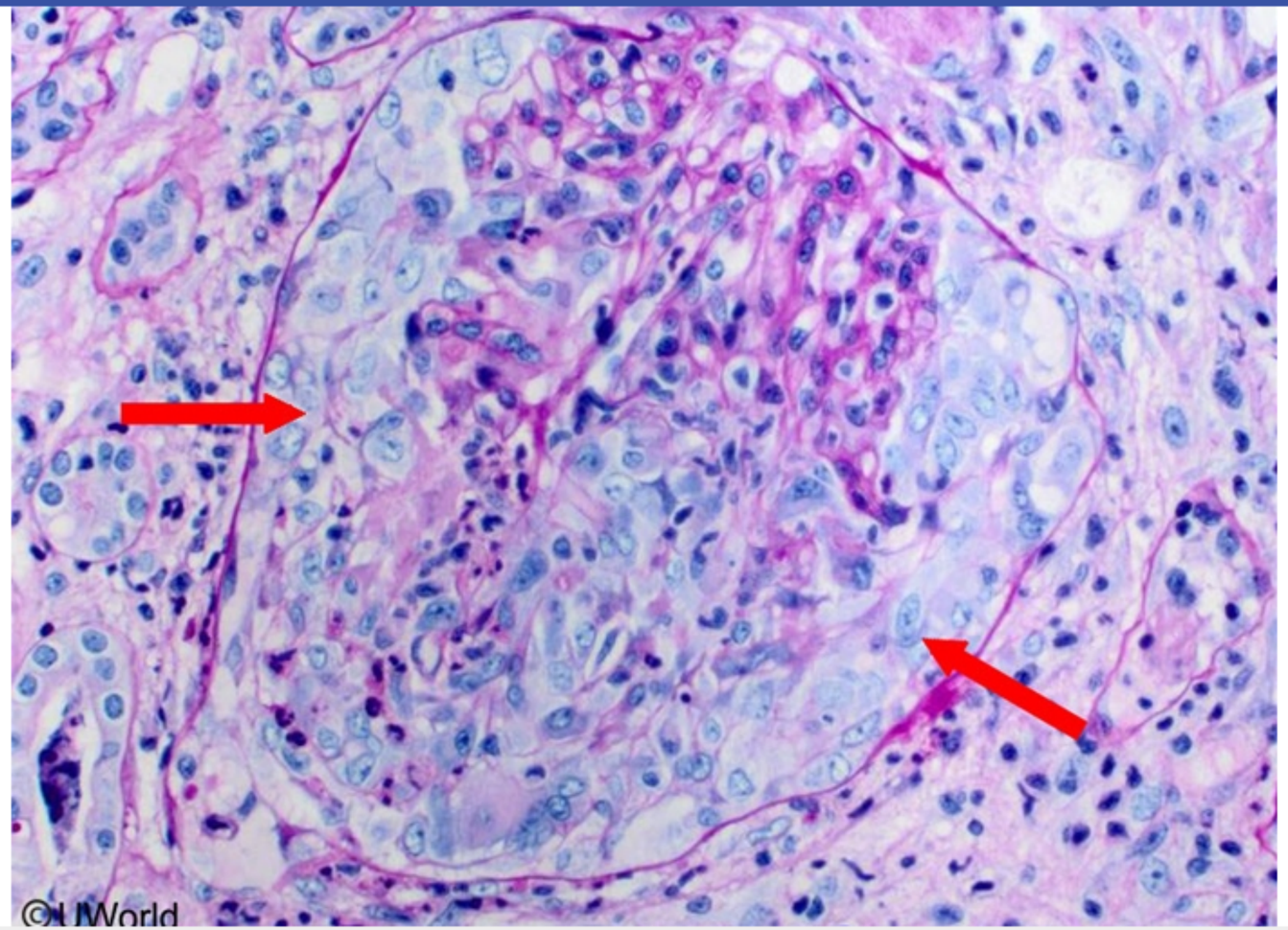

Zoom In | Zoom Out | Reset | Add To New Card | Existing Card

Block Time Remaining: 00:04:35
TUTOR

5 | Feedback | Suspend | End Block

Settings

1
2
3
4
5
6
7
8
9
10
11
12
13
14
15
16
17
18
19
20
21
22
23
24
25
26
27
28
29
30

Item 6 of 40
Question Id: 15346

Mark | Previous | Next | Full Screen | Tutorial | Lab Values | Notes | Calculator | Reverse Color | Text Zoom | Settings

Exhibit Display

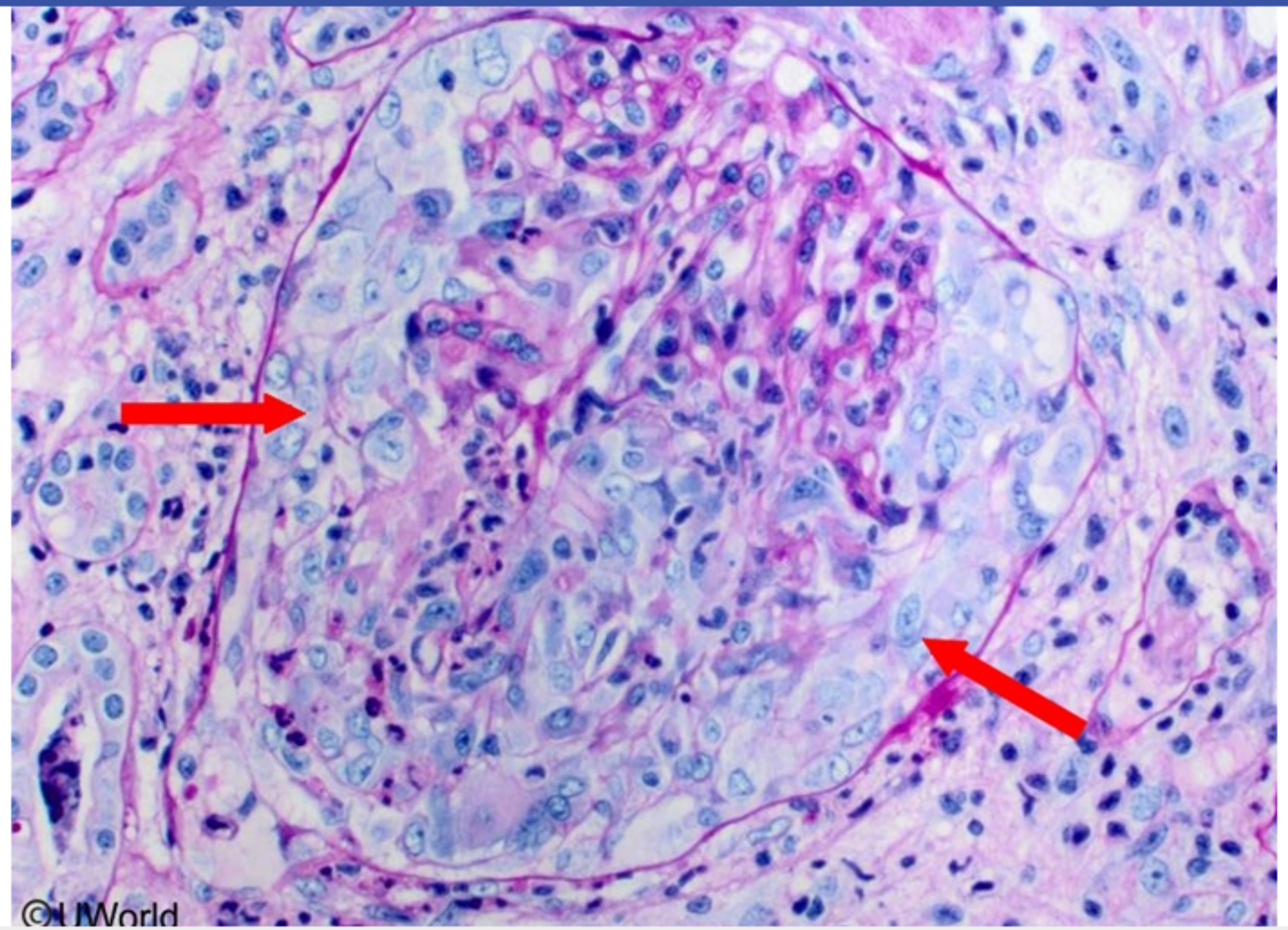

Zoom In | Zoom Out | Reset | Add To New Card | Existing Card

Block Time Remaining: 00:04:35
TUTOR

5 | Feedback | Suspend | End Block

Settings

1
2
3
4
5
6
7
8
9
10
11
12
13
14
15
16
17
18
19
20
21
22
23
24
25
26
27
28
29
30

Item 6 of 40
Question Id: 15346

Mark | Previous | Next | Full Screen | Tutorial | Lab Values | Notes | Calculator | Reverse Color | Text Zoom | Settings

Exhibit Display

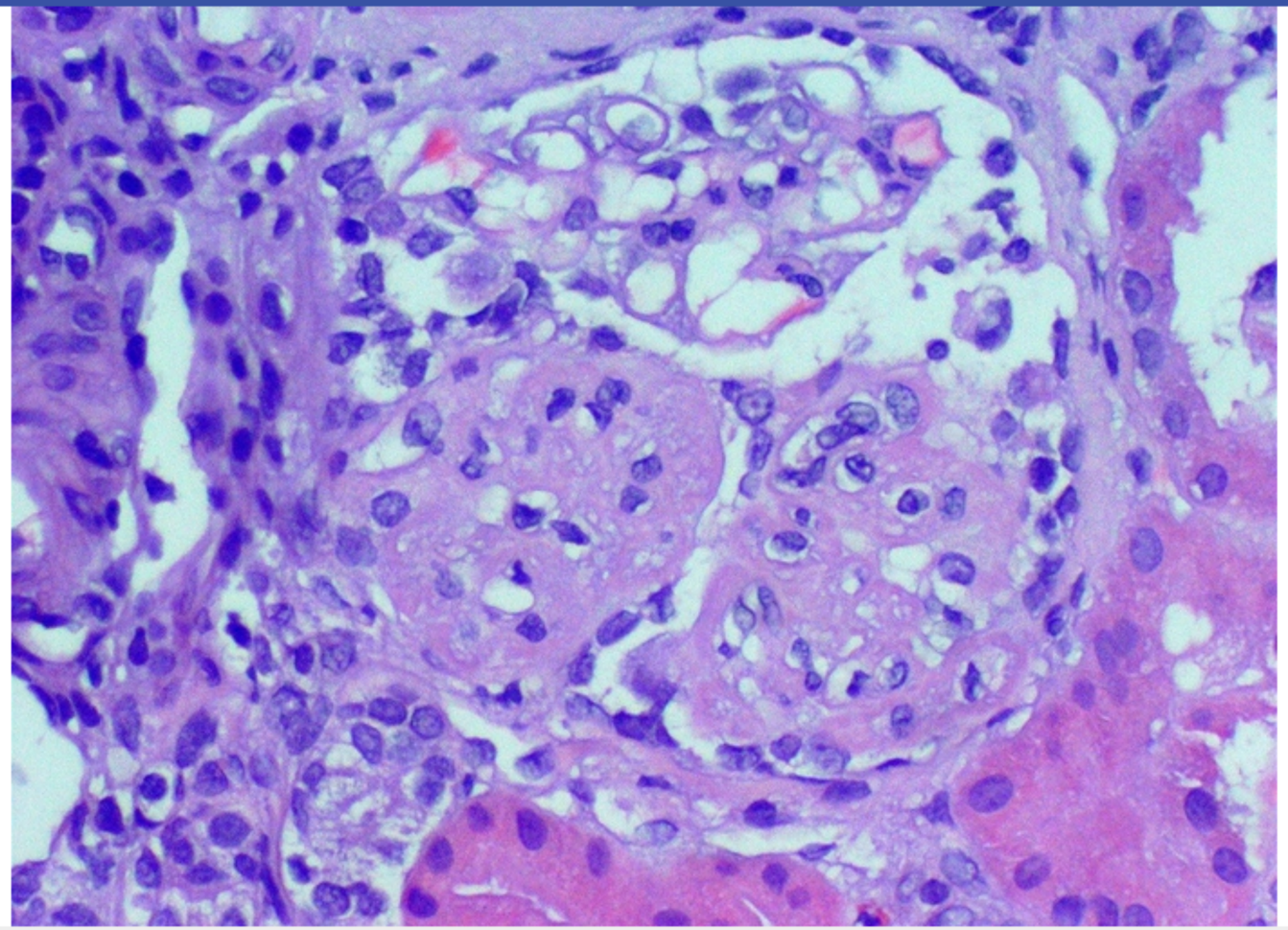

Zoom In | Zoom Out | Reset | Add To New Card | Existing Card

Block Time Remaining: 00:04:35
TUTOR

5 | Feedback | Suspend | End Block

thickening without hypercellularity, whereas silver staining reveals "**spikes and domes**" of GBM that protrude between the immune deposits (which do not stain). Immunofluorescence microscopy demonstrates a diffuse granular pattern of IgG and C3 along the capillary loops.

MN is one of the most common causes of nephrotic syndrome in adults. Primary (idiopathic) MN is thought to be caused by autoantibodies directed at the phospholipase A2 receptor, whereas secondary MN can be associated with a variety of conditions including systemic lupus erythematosus, viral hepatitis, and solid tumors.

(Choices A and E) Crescentic glomerulonephritis (GN) and poststreptococcal GN are nephritic diseases that are characterized by hematuria, red blood cell casts, and hypertension, not heavy proteinuria. Poststreptococcal GN typically occurs in children two to four weeks after a group A streptococcal infection, and EM demonstrates large, subepithelial immune-complex "humps." Crescentic (rapidly progressive) GN can occur in a number of diseases (eg, anti-GBM disease, antineutrophil cytoplasmic antibody vasculitis). Proliferative crescents are visible on light microscopy, and EM may demonstrate rupture of the GBM.

(Choice B) Focal segmental glomerulosclerosis also causes nephrotic syndrome but is characterized by sclerosis and hyalinosis of portions of some, but not all, glomeruli. EM demonstrates diffuse foot process effacement; however, immune deposits (if present) typically occur in the sclerotic region of the glomerulus, not along the GBM.

(Choice D) Minimal change disease causes nephrotic syndrome but occurs more commonly in children. EM demonstrates extensive, diffuse effacement of the foot processes, and immune complexes are not seen.

Educational objective:
Membranous nephropathy is a common cause of nephrotic syndrome in adults. Electron microscopy of the glomerular capillary demonstrates irregular, subepithelial, electron-dense immune deposits on the glomerular basement membrane with moderate effacement of the podocyte foot processes; immunofluorescence microscopy demonstrates a diffuse granular pattern of IgG along the capillary loops.

Pathology	Renal, Urinary Systems & Electrolytes	Membranous nephropathy
Subject	System	Topic

Copyright © UWorld. All rights reserved.

1 2 3 4 5 6 7 8 9 10 11 12 13 14 15 16 17 18 19 20 21 22 23 24 25 26 27 28 29 30

A 21-year-old man comes to the emergency department due to 1 day of left flank pain and gross hematuria. He reports passage of small blood clots in urine but has had no dysuria or similar symptoms in the past. The patient has no other medical problems and does not take any medications. He does not use tobacco, alcohol, or illicit drugs. His younger sister has sickle cell disease. His temperature is 36.7 C (98 F), blood pressure is 126/70 mm Hg, and pulse is 100/min. Abdominal and genitourinary examination is unremarkable. There is no costovertebral angle tenderness. Which of the following is the most likely cause of this patient's hematuria?

- A. Acute pyelonephritis
- B. Amyloidosis
- C. Fanconi syndrome
- D. Hemolytic-uremic syndrome
- E. Hypersensitivity interstitial nephritis
- F. Ischemic tubular necrosis
- G. Lead nephropathy
- H. Papillary necrosis
- I. Renal artery stenosis
- J. Urate nephropathy

Submit

A 21-year-old man comes to the emergency department due to 1 day of left flank pain and gross hematuria. He reports passage of small blood clots in urine but has had no dysuria or similar symptoms in the past. The patient has no other medical problems and does not take any medications. He does not use tobacco, alcohol, or illicit drugs. His younger sister has sickle cell disease. His temperature is 36.7 C (98 F), blood pressure is 126/70 mm Hg, and pulse is 100/min. Abdominal and genitourinary examination is unremarkable. There is no costovertebral angle tenderness. Which of the following is the most likely cause of this patient's hematuria?

- A. Acute pyelonephritis (5%)
- B. Amyloidosis (1%)
- C. Fanconi syndrome (4%)
- D. Hemolytic-uremic syndrome (9%)
- E. Hypersensitivity interstitial nephritis (4%)
- F. Ischemic tubular necrosis (17%)
- G. Lead nephropathy (0%)
- ✓ H. Papillary necrosis (49%)
- I. Renal artery stenosis (1%)
- J. Urate nephropathy (7%)

Omitted
Correct answer
H

49%
Answered correctly

02 secs
Time Spent

05/07/2020
Last Updated

Abrupt-onset gross hematuria in an otherwise healthy patient with a family history of sickle cell disease suggests **renal papillary necrosis (RPN)** due to underlying sickle cell trait. Conditions associated with RPN include:

- **Sickle cell** disease or trait: Sickled cells cause obstruction of small kidney vessels, predisposing to ischemia.
- **Analgesic nephropathy**: Many nonsteroidal anti-inflammatory drugs inhibit renal blood flow by decreasing prostaglandin synthesis and vasoconstricting the afferent arterioles. Certain analgesics can cause ischemia in patients predisposed to renal hypoperfusion.
- Diabetes mellitus: Diabetic metabolic abnormalities (eg, nonenzymatic glycosylation) cause changes in vascular walls, leading to renal vasculopathy and subsequent hypoperfusion.
- Pyelonephritis and urinary tract obstruction: The edematous interstitium of the pyelonephritic kidney compresses the medullary vasculature, leading to ischemia. In this patient, acute pyelonephritis is unlikely in the absence of fever or costovertebral angle tenderness **(Choice A)**.

Gray-white or yellow necrosis of the distal two-thirds of the renal pyramids is seen macroscopically and corresponds microscopically to coagulation necrosis with preserved tubule outlines; cortical surface scars can develop subsequently as inflammatory foci are replaced by fibrous depressions. Symptoms are due to sloughed papillae (sometimes visible in urine as tissue flecks) and include dark or **bloody urine** and colicky **flank pain** (due to ureteral obstruction).

(Choices B and J) Amyloidosis and uric acid nephropathy rarely cause hematuria. Amyloidosis occurs most frequently in the elderly and uric acid nephropathy typically occurs in patients with malignancy (leukemia) or gout.

(Choices C, E, F, G, and I) Fanconi syndrome (polyuria, acidosis, hypophosphatemia), lead nephropathy (Fanconi-like syndrome), hypersensitivity interstitial nephritis (fever, rash, and renal dysfunction due to drug reaction), renal artery stenosis (hypertension in older patients), and acute tubular necrosis (acute kidney injury due to ischemia or nephrotoxins) are not typically characterized by gross hematuria.

(Choice D) Hemolytic-uremic syndrome (microangiopathic hemolytic anemia, thrombocytopenia, acute renal failure) generally occurs 1-2 weeks after a diarrheal illness (classically due to *Escherichia coli* O157:H7).

Educational objective:
Renal papillary necrosis classically presents with gross hematuria, acute flank pain, and passage of tissue fragments in urine. It is most commonly seen in patients with sickle cell disease or trait, diabetes mellitus, analgesic nephropathy, or severe obstructive pyelonephritis.

References

vasculopathy and subsequent hypoperfusion.

- Pyelonephritis and urinary tract obstruction: The edematous interstitium of the pyelonephritic kidney compresses the medullary vasculature, leading to ischemia. In this patient, acute pyelonephritis is unlikely in the absence of fever or costovertebral angle tenderness **(Choice A)**.

Gray-white or yellow necrosis of the distal two-thirds of the renal pyramids is seen macroscopically and corresponds microscopically to coagulation necrosis with preserved tubule outlines; cortical surface scars can develop subsequently as inflammatory foci are replaced by fibrous depressions. Symptoms are due to sloughed papillae (sometimes visible in urine as tissue flecks) and include dark or **bloody urine** and colicky **flank pain** (due to ureteral obstruction).

(Choices B and J) Amyloidosis and uric acid nephropathy rarely cause hematuria. Amyloidosis occurs most frequently in the elderly and uric acid nephropathy typically occurs in patients with malignancy (leukemia) or gout.

(Choices C, E, F, G, and I) Fanconi syndrome (polyuria, acidosis, hypophosphatemia), lead nephropathy (Fanconi-like syndrome), hypersensitivity interstitial nephritis (fever, rash, and renal dysfunction due to drug reaction), renal artery stenosis (hypertension in older patients), and acute tubular necrosis (acute kidney injury due to ischemia or nephrotoxins) are not typically characterized by gross hematuria.

(Choice D) Hemolytic-uremic syndrome (microangiopathic hemolytic anemia, thrombocytopenia, acute renal failure) generally occurs 1-2 weeks after a diarrheal illness (classically due to *Escherichia coli* O157:H7).

Educational objective:
Renal papillary necrosis classically presents with gross hematuria, acute flank pain, and passage of tissue fragments in urine. It is most commonly seen in patients with sickle cell disease or trait, diabetes mellitus, analgesic nephropathy, or severe obstructive pyelonephritis.

References

- Sickle cell trait and renal papillary necrosis.

Pathology	Renal, Urinary Systems & Electrolytes	Renal papillary necrosis
Subject	System	Topic

Copyright © UWorld. All rights reserved.

1 2 3 4 5 6 7 8 9 10 11 12 13 14 15 16 17 18 19 20 21 22 23 24 25 26 27 28 29 30

vasculopathy and subsequent hypoperfusion.

Exhibit Display

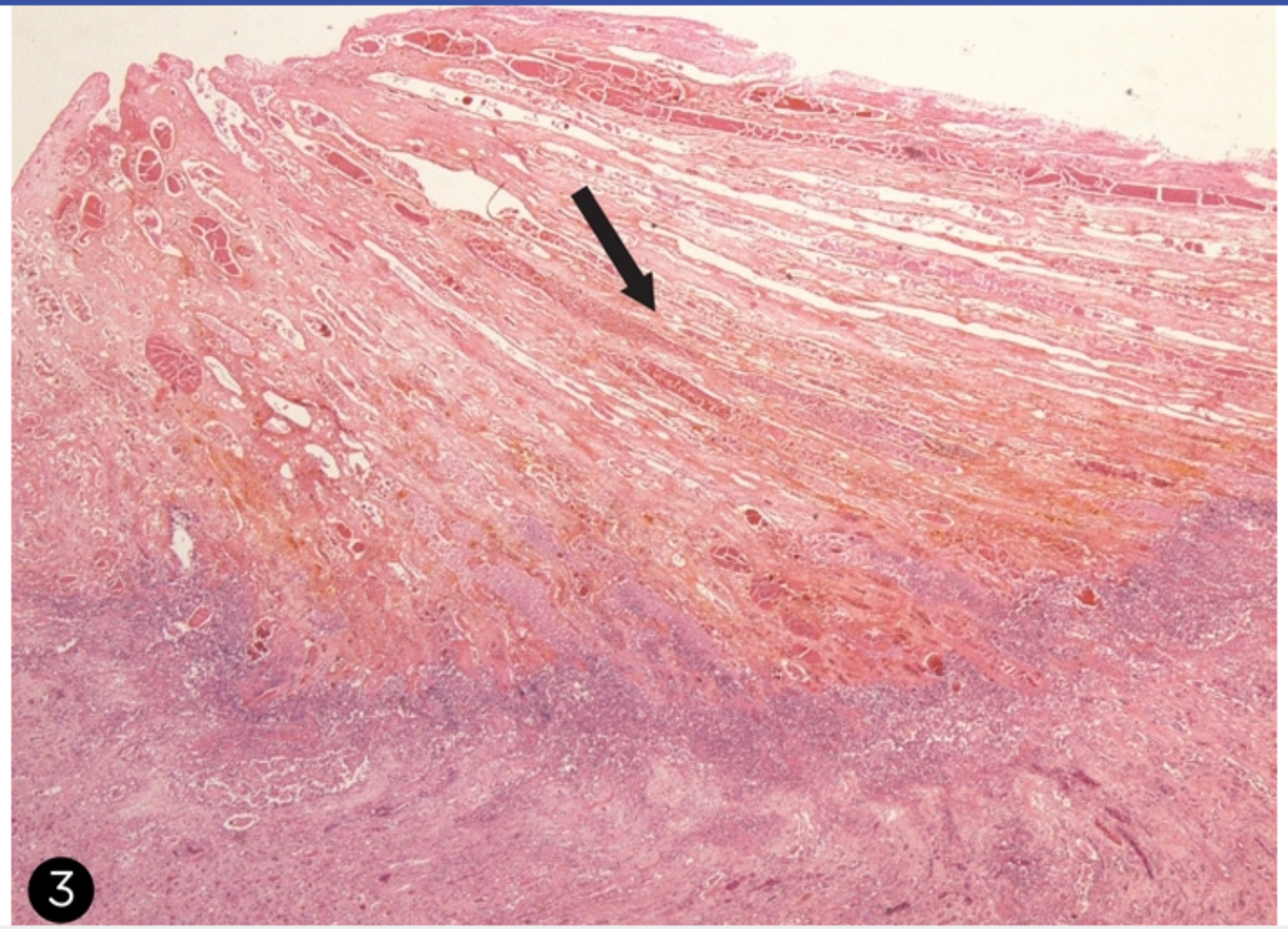

Zoom In | Zoom Out | Reset | Add To New Card | Existing Card

Settings

1 2 3 4 5 6 7 8 9 10 11 12 13 14 15 16 17 18 19 20 21 22 23 24 25 26 27 28 29 30

Item 8 of 40
Question Id: 833

Mark | Previous | Next | Full Screen | Tutorial | Lab Values | Notes | Calculator | Reverse Color | Text Zoom | Settings

A 12-year-old girl is brought to the clinic by her parents after she is found to have hypertension by her school nurse. The patient has no symptoms and reads a book during the office visit. The girl had not received routine well-child care until immigrating to the United States several months ago. She has had several episodes of fever and abdominal pain, which her parents have been able to treat with over-the-counter antibiotics. The patient's blood pressure is elevated on several readings in the office. There is no family history of hypertension. Renal ultrasound reveals dilated calyces with overlying cortical atrophy bilaterally, mostly in the upper and lower poles. Which of the following is the most likely cause of this patient's condition?

A. Autosomal dominant polycystic kidney disease

B. Malignant hypertension

C. Multicystic dysplastic kidneys

D. Posterior urethral valves

E. Reflux nephropathy

Submit

Block Time Remaining: 00:04:38
TUTOR

4 | Feedback | Suspend | End Block

1 2 3 4 5 6 7 8 9 10 11 12 13 14 15 16 17 18 19 20 21 22 23 24 25 26 27 28 29 30

A 12-year-old girl is brought to the clinic by her parents after she is found to have hypertension by her school nurse. The patient has no symptoms and reads a book during the office visit. The girl had not received routine well-child care until immigrating to the United States several months ago. She has had several episodes of fever and abdominal pain, which her parents have been able to treat with over-the-counter antibiotics. The patient's blood pressure is elevated on several readings in the office. There is no family history of hypertension. Renal ultrasound reveals dilated calyces with overlying cortical atrophy bilaterally, mostly in the upper and lower poles. Which of the following is the most likely cause of this patient's condition?

A. Autosomal dominant polycystic kidney disease (8%)

B. Malignant hypertension (2%)

C. Multicystic dysplastic kidneys (21%)

D. Posterior urethral valves (19%)

✓ E. Reflux nephropathy (47%)

Omitted
Correct answer
E

47%
Answered correctly

02 secs
Time Spent

04/08/2020
Last Updated

Explanation

Vesicoureteral reflux

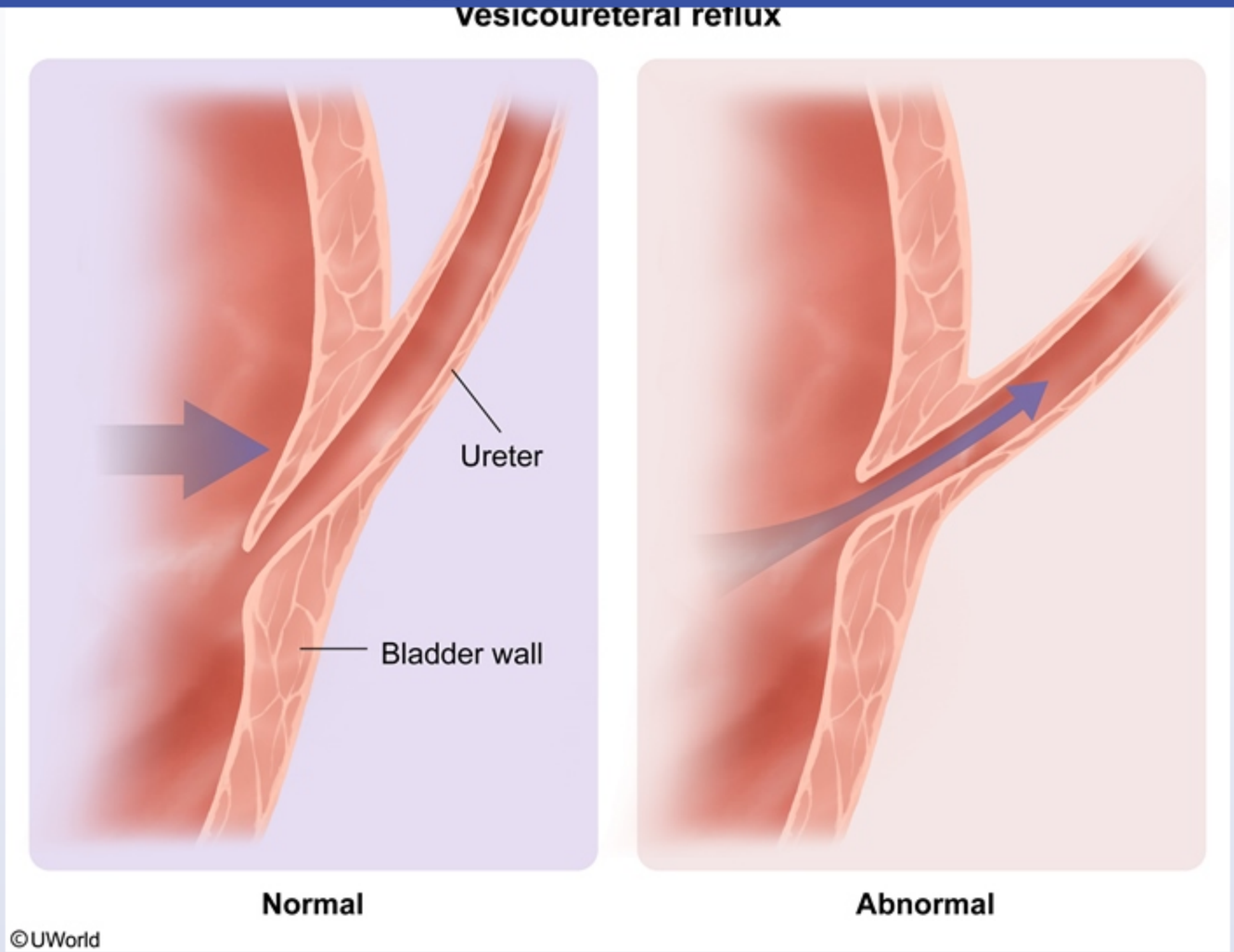

This patient's history of recurrent fever and abdominal pain along with imaging findings consistent with renal scarring indicate **recurrent pyelonephritis**. Pyelonephritis results from retrograde flow of infected urine from the bladder into the ureter. Normally, the ureters travel through the bladder wall at an **oblique** angle. When the bladder fills, the intramural ureter becomes compressed. This flap-valve mechanism prevents

©UWorld

This patient's history of recurrent fever and abdominal pain along with imaging findings consistent with renal scarring indicate **recurrent pyelonephritis**. Pyelonephritis results from retrograde flow of infected urine from the bladder into the ureter. Normally, the ureters travel through the bladder wall at an **oblique** angle. When the bladder fills, the intramural ureter becomes compressed. This flap-valve mechanism prevents retrograde flow of urine. However, this mechanism does not work correctly if the ureter enters the bladder wall at a more perpendicular angle, a condition known as **vesicoureteral reflux** (VUR).

Patients with VUR are at much higher risk for chronic pyelonephritis. Inflammation can occur from pyelonephritis or from VUR itself due to hydrostatic pressure on the papillae. Ongoing injury leads to **renal scarring**, most commonly at the upper and lower poles of the kidney in which compound papillae are found. Compound papillae are always open, unlike simple papillae in the mid kidney, and are therefore much more susceptible to dilation and subsequent injury. If uncorrected, VUR can lead to loss of nephrons and **secondary hypertension**.

(Choice A) Autosomal dominant polycystic kidney disease generally presents in adulthood with hematuria, hypertension, and renal insufficiency. Symptomatic patients will have nephromegaly and diffuse parenchymal cysts on ultrasonography.

(Choice B) Malignant hypertension refers to very high blood pressure that develops rapidly and causes end-organ damage. Affected patients can present with vision changes, encephalopathy, and renal failure. This patient has no evidence of acute end-organ dysfunction, and her imaging is more consistent with VUR and chronic pyelonephritis.

(Choice C) Multicystic dysplastic kidney (MCDK) is a nonhereditary renal malformation characterized by multiple noncommunicating cysts with intervening dysplastic tissue. Unilateral MCDK may be clinically silent, but bilateral MCDK presents with early, severe renal insufficiency due to absence of functional renal tissue.

(Choice D) Posterior urethral valves can present with bilateral hydronephrosis and calyceal dilation due to obstruction of urine flow in the urethra. However, posterior urethral valves result from a malformation of the Wolffian duct, and therefore only occur in males.

Educational objective:
Vesicoureteral reflux is caused by retrograde urine flow from the bladder into the ureter. The hydrostatic pressure of refluxing urine along with infections due to ascending bacteria causes inflammation. The compound papillae in the upper and lower poles of the kidney are most susceptible to reflux-induced damage, which appears as dilated calyces with overlying renal cortical scarring.

Patients with VUR are at much higher risk for chronic pyelonephritis. Inflammation can occur from pyelonephritis or from VUR itself due to hydrostatic pressure on the papillae. Ongoing injury leads to **renal scarring**, most commonly at the upper and lower poles of the kidney in which compound papillae are found. Compound papillae are always open, unlike simple papillae in the mid kidney, and are therefore much more susceptible to dilation and subsequent injury. If uncorrected, VUR can lead to loss of nephrons and **secondary hypertension**.

(Choice A) Autosomal dominant polycystic kidney disease generally presents in adulthood with hematuria, hypertension, and renal insufficiency. Symptomatic patients will have nephromegaly and diffuse parenchymal cysts on ultrasonography.

(Choice B) Malignant hypertension refers to very high blood pressure that develops rapidly and causes end-organ damage. Affected patients can present with vision changes, encephalopathy, and renal failure. This patient has no evidence of acute end-organ dysfunction, and her imaging is more consistent with VUR and chronic pyelonephritis.

(Choice C) Multicystic dysplastic kidney (MCDK) is a nonhereditary renal malformation characterized by multiple noncommunicating cysts with intervening dysplastic tissue. Unilateral MCDK may be clinically silent, but bilateral MCDK presents with early, severe renal insufficiency due to absence of functional renal tissue.

(Choice D) Posterior urethral valves can present with bilateral hydronephrosis and calyceal dilation due to obstruction of urine flow in the urethra. However, posterior urethral valves result from a malformation of the Wolffian duct, and therefore only occur in males.

Educational objective:
Vesicoureteral reflux is caused by retrograde urine flow from the bladder into the ureter. The hydrostatic pressure of refluxing urine along with infections due to ascending bacteria causes inflammation. The compound papillae in the upper and lower poles of the kidney are most susceptible to reflux-induced damage, which appears as dilated calyces with overlying renal cortical scarring.

References

- Vesicoureteral reflux: Current management in children.

Pathology	Renal, Urinary Systems & Electrolytes	Vesicoureteral reflux
Subject	System	Topic

Copyright © UWorld. All rights reserved.

Patients with VUR are at much higher risk for chronic pyelonephritis. Inflammation can occur from pyelonephritis or from VUR itself due to

Exhibit Display

Posterior urethral valves

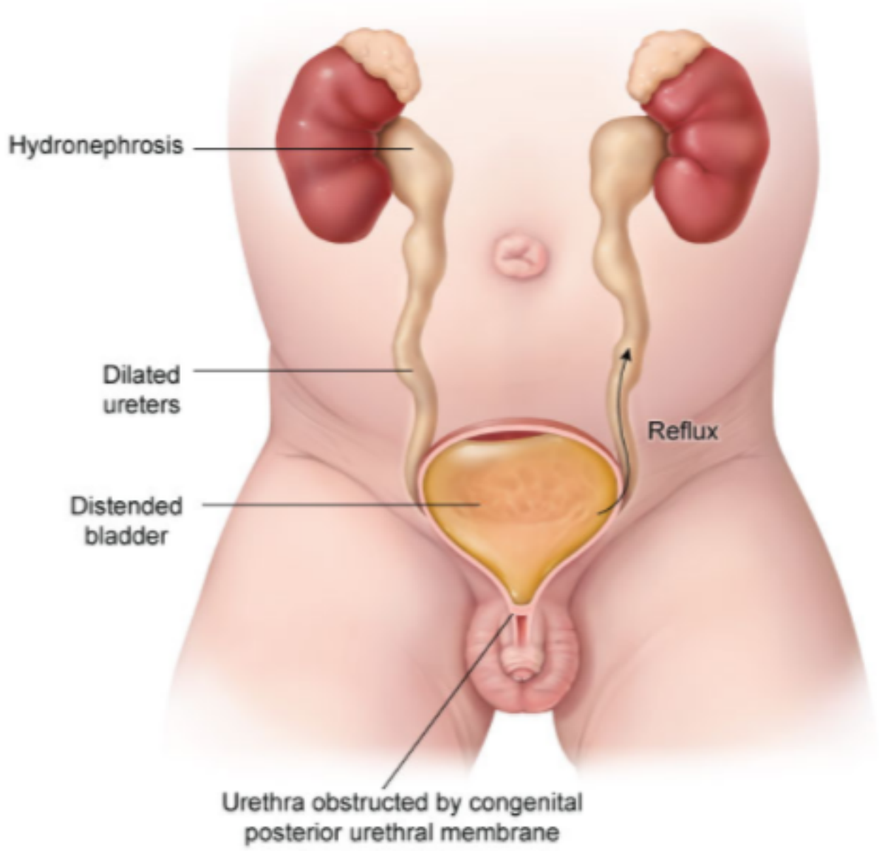

©UWorld

Zoom In Zoom Out Reset Add To New Card | Existing Card

Copyright © UWorld. All rights reserved.

Four children and 2 adults are currently being followed in a nephrology clinic for poststreptococcal glomerulonephritis. Three patients initially had gross hematuria and edema requiring diuretic administration. The remaining 3 patients had microscopic hematuria and hypertension. C3 levels were decreased in all patients, and antistreptolysin O titer was elevated in 4 of them. None of the patients have preexisting renal disease. Which of the following patient characteristics is most likely to indicate a poor long-term prognosis?

A. Adult onset

B. Decreased C3 level

C. Delay in corticosteroid treatment

D. Elevated antistreptolysin titer

E. Gross hematuria

Submit

Four children and 2 adults are currently being followed in a nephrology clinic for poststreptococcal glomerulonephritis. Three patients initially had gross hematuria and edema requiring diuretic administration. The remaining 3 patients had microscopic hematuria and hypertension. C3 levels were decreased in all patients, and antistreptolysin O titer was elevated in 4 of them. None of the patients have preexisting renal disease. Which of the following patient characteristics is most likely to indicate a poor long-term prognosis?

- ✓ A. Adult onset (66%)
- B. Decreased C3 level (8%)
- C. Delay in corticosteroid treatment (11%)
- D. Elevated antistreptolysin titer (5%)
- E. Gross hematuria (7%)

Omitted
Correct answer
A

66%
Answered correctly

02 secs
Time Spent

03/28/2020
Last Updated

Explanation

Poststreptococcal glomerulonephritis (PSGN) is the most common cause of acute pediatric glomerulonephritis (GN) and presents with acute onset of malaise, periorbital **edema**, **hypertension**, and either microscopic or gross **hematuria**. Symptoms generally occur 1-3 weeks following group A streptococcal pharyngitis or skin infection (eg, impetigo). The lag in symptoms corresponds to formation and deposition of the streptococcal antigen and antibody complex within the glomerular basement membrane and the subsequent activation of complement.

PSGN most commonly affects children age 5-12, and >95% recover completely. **Increased age**, conversely, is the most important **poor**

Explanation

Poststreptococcal glomerulonephritis (PSGN) is the most common cause of acute pediatric glomerulonephritis (GN) and presents with acute onset of malaise, periorbital **edema**, **hypertension**, and either microscopic or gross **hematuria**. Symptoms generally occur 1-3 weeks following group A streptococcal pharyngitis or skin infection (eg, impetigo). The lag in symptoms corresponds to formation and deposition of the streptococcal antigen and antibody complex within the glomerular basement membrane and the subsequent activation of complement.

PSGN most commonly affects children age 5-12, and >95% recover completely. **Increased age**, conversely, is the most important **poor prognostic factor**; only 60% of adult cases resolve completely, and many of the remainder have residual hypertension, recurrent proteinuria, chronic renal insufficiency, or rapidly progressive GN resulting in end-stage renal disease.

(Choices B, D, and E) Elevated antistreptolysin O (ASO) titers and low C3 levels are present in the vast majority of patients with PSGN. ASO titers indicate recent streptococcal (usually pharyngeal) infection. C3 is decreased due to complement activation with deposition in the glomerulus. Initial urinalysis may show hematuria, proteinuria, and red blood cell casts, but none of these findings affect prognosis.

(Choice C) Corticosteroids are used in minimal change disease (the most common cause of nephrotic syndrome in children) but not in PSGN.

Educational objective:
Poststreptococcal glomerulonephritis presents with edema, hypertension, and hematuria after a streptococcal infection. Most children recover completely, but adult patients have a relatively poor prognosis and higher risk of chronic hypertension and renal insufficiency.

References

- Post-streptococcal glomerulonephritis.

Pathology	Renal, Urinary Systems & Electrolytes	Poststreptococcal Glomerulonephritis
Subject	System	Topic

Copyright © UWorld. All rights reserved.

A 68-year-old male presents to your office complaining of difficulty urinating. His past medical history is significant for prostate cancer treated with radiation therapy one year ago. Ultrasonography reveals bilateral dilation of the ureters and renal calyces. If related to the previous therapy, which of the following is the most likely cause of this patient's current condition?

- A. Granuloma formation
- B. Radiation mucositis
- C. Fibrosis
- D. Mucosal ulceration
- E. Mucosal hyperplasia

Submit

A 68-year-old male presents to your office complaining of difficulty urinating. His past medical history is significant for prostate cancer treated with radiation therapy one year ago. Ultrasonography reveals bilateral dilation of the ureters and renal calyces. If related to the previous therapy, which of the following is the most likely cause of this patient's current condition?

- A. Granuloma formation (1%)
- B. Radiation mucositis (9%)
- ✓ C. Fibrosis (75%)
- D. Mucosal ulceration (1%)
- E. Mucosal hyperplasia (12%)

Omitted
Correct answer
C

75%
Answered correctly

02 secs
Time Spent

03/29/2020
Last Updated

Explanation

Radiotherapy has applications as primary, adjuvant, or more commonly palliative therapy for many types of cancer. Tumor sensitivity to radiation depends on the rate of cell turnover, with rapidly growing tumors being more sensitive. In the same way, rapidly dividing normal body tissues such as blood cell precursors, epithelial surfaces in the skin, GI tract, and urinary tract, and the gonads (gametes) are also at risk for damage. **Fibrosis** and **strictures** due to diffuse scarring of the damaged tissues often occurs as a late complication of radiotherapy for prostate cancer, and may lead to **obstructive uropathy**.

(Choice A) Granuloma formation occurs in diseases such as sarcoidosis (sterile, non-caseating granulomas), tuberculosis (caseating necrosis

C

Explanation

Radiotherapy has applications as primary, adjuvant, or more commonly palliative therapy for many types of cancer. Tumor sensitivity to radiation depends on the rate of cell turnover, with rapidly growing tumors being more sensitive. In the same way, rapidly dividing normal body tissues such as blood cell precursors, epithelial surfaces in the skin, GI tract, and urinary tract, and the gonads (gametes) are also at risk for damage. **Fibrosis** and **strictures** due to diffuse scarring of the damaged tissues often occurs as a late complication of radiotherapy for prostate cancer, and may lead to **obstructive uropathy**.

(Choice A) Granuloma formation occurs in diseases such as sarcoidosis (sterile, non-caseating granulomas), tuberculosis (caseating necrosis with Langhans giant cells and acid-fast bacilli), and in foreign body reactions (foreign body giant cells, sometimes surrounding an identifiable foreign body).

(Choices B & D) Radiation mucositis and mucosal ulceration occur after radiotherapy for gastrointestinal tumors and head and neck malignancies. These early effects resolve soon after discontinuation of treatment.

(Choice E) Mucosal hyperplasia is seen in patients treated with phenytoin (gingivae) and can also be seen in states where there is hypersecretion of a hormone that is trophic for a mucosal surface as occurs in the gastric mucosa with gastrinoma.

Educational objective:
Fibrosis and strictures are late effects of radiation therapy. Radiotherapy for prostate cancer may lead to urethral fibrosis and result in obstructive uropathy.

Pathology	Renal, Urinary Systems & Electrolytes	Prostate cancer
Subject	System	Topic

Copyright © UWorld. All rights reserved.

Settings

1 2 3 4 5 6 7 8 9 10 11 12 13 14 15 16 17 18 19 20 21 22 23 24 25 26 27 28 29 30

Item 11 of 40
Question Id: 229

Mark | Previous | Next | Full Screen | Tutorial | Lab Values | Notes | Calculator | Reverse Color | Text Zoom | Settings

A 23-year-old man comes to the office due to 3 weeks of malaise and fatigue. He says, "I've been sick with the flu for the last 3 weeks. I don't know why I'm not getting better." The patient also has profound fatigue causing difficulty with day-to-day activities. His temperature is 38.4 C (101.2 F). Cardiac auscultation reveals an apical holosystolic murmur radiating to the axilla, which was not heard during previous office visits. Laboratory evaluation shows serum creatinine of 2.3 mg/dL. Mild proteinuria and microscopic hematuria with red cell casts are present on urinalysis. Which of the following is the most likely pathogenesis of this patient's renal findings?

A. Anti-glomerular basement membrane antibodies

B. Circulating immune complex-mediated injury

C. Endotoxin-induced renal tubular injury

D. Hematogenous metastatic infection focus

E. Thromboembolic event

Submit

Block Time Remaining: 00:04:44
TUTOR

2 | Feedback | Suspend | End Block

A 23-year-old man comes to the office due to 3 weeks of malaise and fatigue. He says, "I've been sick with the flu for the last 3 weeks. I don't know why I'm not getting better." The patient also has profound fatigue causing difficulty with day-to-day activities. His temperature is 38.4 C (101.2 F). Cardiac auscultation reveals an apical holosystolic murmur radiating to the axilla, which was not heard during previous office visits. Laboratory evaluation shows serum creatinine of 2.3 mg/dL. Mild proteinuria and microscopic hematuria with red cell casts are present on urinalysis. Which of the following is the most likely pathogenesis of this patient's renal findings?

- A. Anti-glomerular basement membrane antibodies (8%)
- ✓ B. Circulating immune complex-mediated injury (75%)
- C. Endotoxin-induced renal tubular injury (6%)
- D. Hematogenous metastatic infection focus (5%)
- E. Thromboembolic event (4%)

Omitted
Correct answer
B

75%
Answered correctly

02 secs
Time Spent

05/16/2020
Last Updated

Explanation

This young patient's constitutional (flulike) symptoms, fever, and a new systolic murmur suggest **infective endocarditis** (IE). Elevated serum creatinine with hematuria and proteinuria further suggest renal insufficiency due to a nephritic syndrome. In some patients, IE may be complicated by deposition of circulating immune complexes in the glomerular capillary wall, resulting in glomerulonephritis. This can be seen as capillary wall thickening with subendothelial and subepithelial deposit formation. Hypercellularity similar to that seen in poststreptococcal glomerulonephritis or membranoproliferative glomerulonephritis is revealed on light microscopy.

Explanation

This young patient's constitutional (flulike) symptoms, fever, and a new systolic murmur suggest **infective endocarditis** (IE). Elevated serum creatinine with hematuria and proteinuria further suggest renal insufficiency due to a nephritic syndrome. In some patients, IE may be complicated by deposition of circulating immune complexes in the glomerular capillary wall, resulting in glomerulonephritis. This can be seen as capillary wall thickening with subendothelial and subepithelial deposit formation. Hypercellularity similar to that seen in poststreptococcal glomerulonephritis or membranoproliferative glomerulonephritis is revealed on light microscopy.

(Choice A) Anti-glomerular basement membrane (anti-GBM) autoantibodies can also cause an acute nephritic syndrome. However, these antibodies do not affect cardiac tissues and would not cause a new cardiac murmur. Anti-GBM antibodies may target the pulmonary alveolar basement membrane, causing hemoptysis (Goodpasture syndrome).

(Choice C) IE is rarely caused by gram-negative organisms, the producers of endotoxin. Furthermore, endotoxin production can cause acute tubular necrosis as part of sepsis but is unlikely to cause glomerulonephritis.

(Choices D and E) Emboli from infected endocardial vegetations may metastasize via the hematogenous route to cause infarcts in the brain, kidneys, myocardium, and other tissues (eg, Janeway lesions on palms and soles). Emboli are usually small and do not cause acute renal failure. Renal failure may be seen if the infectious embolic focus develops into an abscess or the embolus is large enough to cause a sizeable infarct. However, both renal infarct and abscess present with flank pain.

Educational objective:
The most likely cause of fever and fatigue with new-onset cardiac murmur is infective endocarditis (IE). Diffuse, proliferative glomerulonephritis secondary to circulating immune complex deposition may complicate IE and can result in acute renal insufficiency.

Pathology	Renal, Urinary Systems & Electrolytes	Endocarditis
Subject	System	Topic

Copyright © UWorld. All rights reserved.

A 26-year-old previously healthy man comes to the office with a 3-week history of shortness of breath, cough, and hemoptysis preceded by an upper respiratory tract infection. He has no fever, night sweats, or weight loss. His blood pressure is 150/85 mm Hg and pulse is 86/min and regular. Physical examination reveals bilateral inspiratory crackles and lower extremity edema. His creatinine is 4.1 mg/dL. Urinalysis shows proteinuria and hematuria with dysmorphic red blood cells. Bilateral pulmonary infiltrates are seen on chest x-ray. He is also found to have an increased carbon monoxide diffusing capacity (DLCO) on pulmonary function testing. Antibodies directed against which of the following is most likely to be associated with this patient's condition?

A. Alpha 3 chain of type IV collagen

B. Beta-hemolytic streptococci

C. Cardiolipin phospholipid

D. Double-stranded DNA

E. Topoisomerase I

Submit

A 26-year-old previously healthy man comes to the office with a 3-week history of shortness of breath, cough, and hemoptysis preceded by an upper respiratory tract infection. He has no fever, night sweats, or weight loss. His blood pressure is 150/85 mm Hg and pulse is 86/min and regular. Physical examination reveals bilateral inspiratory crackles and lower extremity edema. His creatinine is 4.1 mg/dL. Urinalysis shows proteinuria and hematuria with dysmorphic red blood cells. Bilateral pulmonary infiltrates are seen on chest x-ray. He is also found to have an increased carbon monoxide diffusing capacity (DLCO) on pulmonary function testing. Antibodies directed against which of the following is most likely to be associated with this patient's condition?

- ✓ A. Alpha 3 chain of type IV collagen (70%)
- B. Beta-hemolytic streptococci (16%)
- C. Cardiolipin phospholipid (6%)
- D. Double-stranded DNA (4%)
- E. Topoisomerase I (2%)

Omitted
Correct answer
A

70%
Answered correctly

02 secs
Time Spent

06/18/2020
Last Updated

Explanation

This patient has **Goodpasture syndrome**, which is caused by autoantibodies against the **alpha 3 chain of type IV collagen** found in the glomerular basement membrane (GBM) and pulmonary capillary membrane (**anti-GBM antibodies**). Antibody formation may be triggered by an antecedent viral respiratory infection, although most cases are idiopathic. These antibodies promote inflammatory injury of the glomerular and alveolar basement membranes, resulting in rapidly progressive glomerulonephritis and alveolar hemorrhage, respectively.

This patient has **Goodpasture syndrome**, which is caused by autoantibodies against the **alpha 3 chain of type IV collagen** found in the glomerular basement membrane (GBM) and pulmonary capillary membrane (**anti-GBM antibodies**). Antibody formation may be triggered by an antecedent viral respiratory infection, although most cases are idiopathic. These antibodies promote inflammatory injury of the glomerular and alveolar basement membranes, resulting in rapidly progressive glomerulonephritis and alveolar hemorrhage, respectively.

Rapidly progressive glomerulonephritis results in nephritic syndrome, characterized by hypertension, edema, acute renal failure, hematuria (eg, dysmorphic red cells and red cell casts), and proteinuria. On renal biopsy, light microscopy shows glomerular crescent formation and immunofluorescence shows linear deposition of IgG and C3 on the GBM. **Alveolar hemorrhage** manifests with shortness of breath and hemoptysis with infiltrates on chest x-ray. Hemoglobin in the alveoli leads to increased alveolar oxygen absorption and high carbon monoxide diffusing capacity (DLCO).

(Choice B) Patients with beta-hemolytic streptococci infection of the pharynx or skin can develop glomerular immune complex deposition resulting in poststreptococcal glomerulonephritis and nephritic syndrome; however, this usually occurs in children and pulmonary involvement with alveolar hemorrhage is not characteristic.

(Choice C) Anticardiolipin antibodies are characteristic of antiphospholipid antibody syndrome, which typically presents with unprovoked/recurrent arterial and venous thrombosis or recurrent spontaneous abortions.

(Choice D) Antibodies to double-stranded DNA (dsDNA) are typically seen in systemic lupus erythematosus (SLE), particularly in individuals with active lupus nephritis. Although this patient has findings of glomerulonephritis, other features of SLE such as constitutional symptoms (eg, fatigue, fever, weight loss), malar rash, arthritis, serositis, and cytopenias are not evident. Pulmonary hemorrhage is also not characteristic of SLE.

(Choice E) Anti-topoisomerase I (anti-Scl-70) antibodies are found in patients with systemic sclerosis, which typically presents with diffuse thickening/hardening of the skin, Raynaud phenomenon, and esophageal dysfunction. Acute renal failure and hypertension may occur during scleroderma renal crisis; however, glomerulonephritis is not characteristic. Lung involvement typically leads to pulmonary fibrosis and pulmonary arterial hypertension as opposed to pulmonary hemorrhage.

Educational objective:
Goodpasture syndrome is caused by autoantibodies against the alpha 3 chain of type IV collagen in glomerular and alveolar basement membranes (anti-GBM antibodies). Patients typically present with rapidly progressive glomerulonephritis (nephritic syndrome) and alveolar

Settings

1
2
3
4
5
6
7
8
9
10
11
12
13
14
15
16
17
18
19
20
21
22
23
24
25
26
27
28
29
30

Item 12 of 40
Question Id: 7

Mark | Previous | Next | Full Screen | Tutorial | Lab Values | Notes | Calculator | Reverse Color | Text Zoom | Settings

Exhibit Display

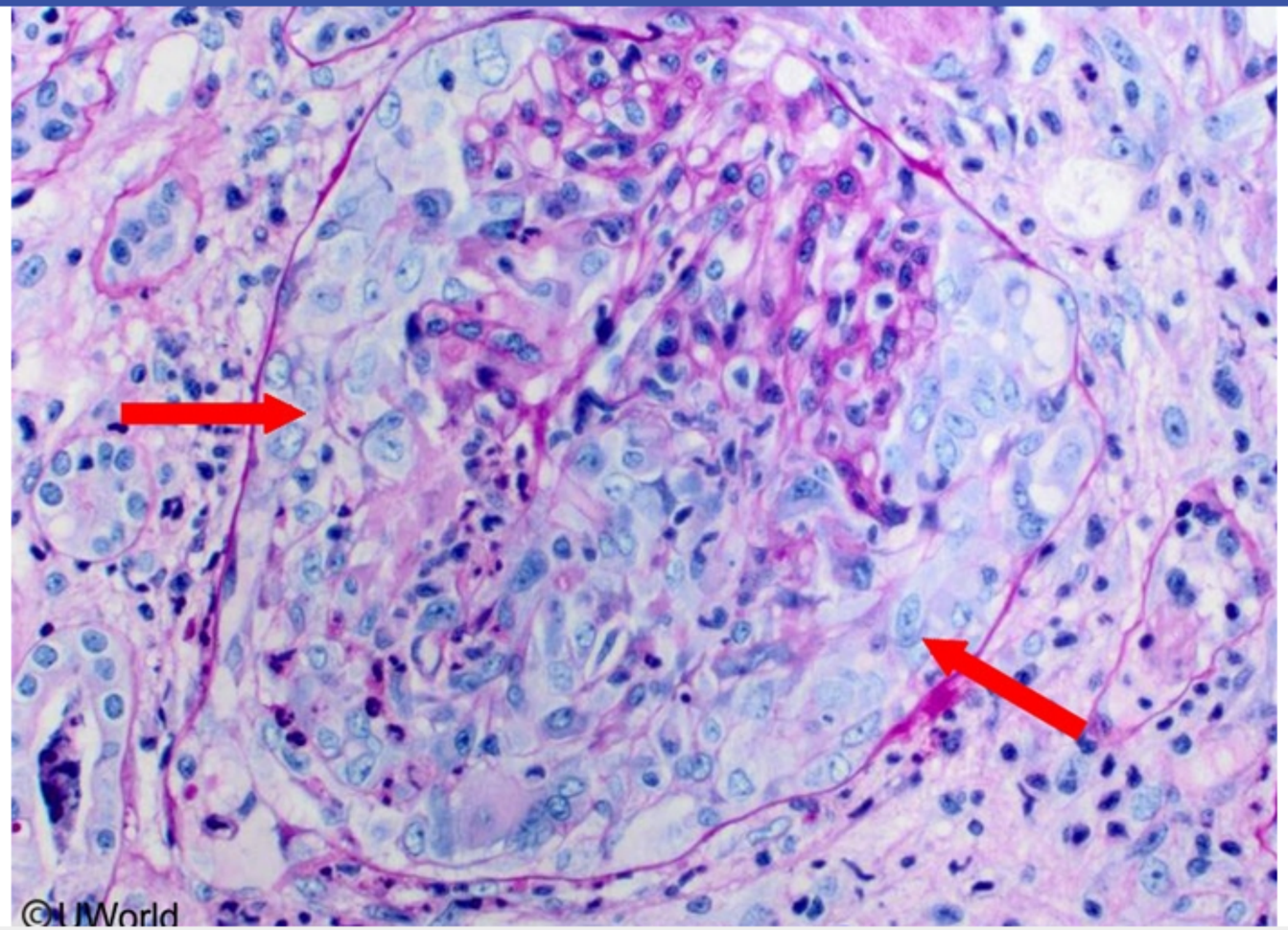

Zoom In | Zoom Out | Reset | Add To New Card | Existing Card

Block Time Remaining: 00:04:47
TUTOR

4 | Feedback | Suspend | End Block

Settings

1
2
3
4
5
6
7
8
9
10
11
12
13
14
15
16
17
18
19
20
21
22
23
24
25
26
27
28
29
30

Item 12 of 40
Question Id: 7

Mark | Previous | Next | Full Screen | Tutorial | Lab Values | Notes | Calculator | Reverse Color | Text Zoom | Settings

Exhibit Display

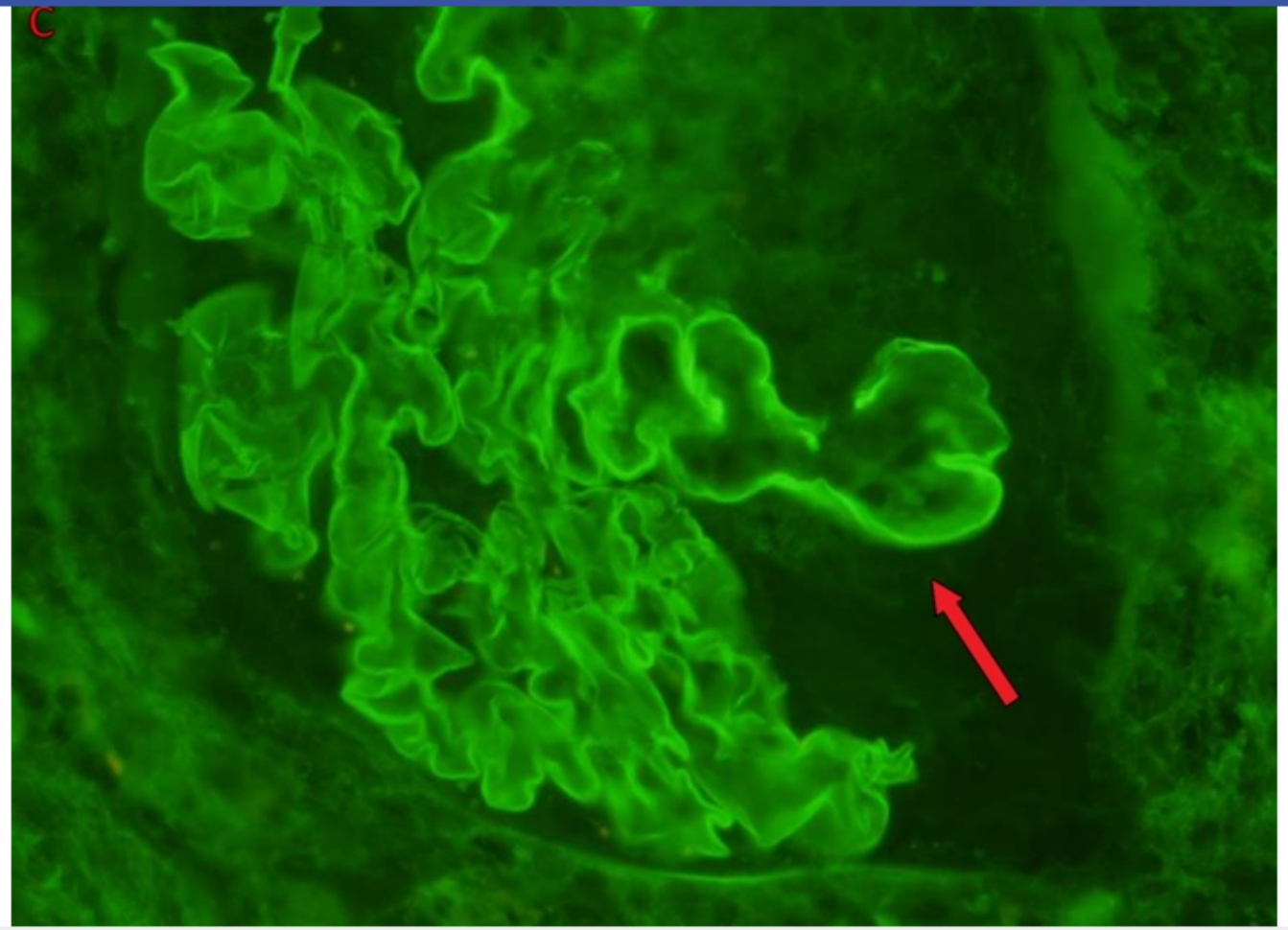

Zoom In | Zoom Out | Reset | Add To New Card | Existing Card

Block Time Remaining: 00:04:47
TUTOR

4 | Feedback | Suspend | End Block

(Choice B) Patients with beta-hemolytic streptococci infection of the pharynx or skin can develop glomerular immune complex deposition resulting in poststreptococcal glomerulonephritis and nephritic syndrome; however, this usually occurs in children and pulmonary involvement with alveolar hemorrhage is not characteristic.

(Choice C) Anticardiolipin antibodies are characteristic of antiphospholipid antibody syndrome, which typically presents with unprovoked/recurrent arterial and venous thrombosis or recurrent spontaneous abortions.

(Choice D) Antibodies to double-stranded DNA (dsDNA) are typically seen in systemic lupus erythematosus (SLE), particularly in individuals with active lupus nephritis. Although this patient has findings of glomerulonephritis, other features of SLE such as constitutional symptoms (eg, fatigue, fever, weight loss), malar rash, arthritis, serositis, and cytopenias are not evident. Pulmonary hemorrhage is also not characteristic of SLE.

(Choice E) Anti-topoisomerase I (anti-Scl-70) antibodies are found in patients with systemic sclerosis, which typically presents with diffuse thickening/hardening of the skin, Raynaud phenomenon, and esophageal dysfunction. Acute renal failure and hypertension may occur during scleroderma renal crisis; however, glomerulonephritis is not characteristic. Lung involvement typically leads to pulmonary fibrosis and pulmonary arterial hypertension as opposed to pulmonary hemorrhage.

Educational objective:

Goodpasture syndrome is caused by autoantibodies against the alpha 3 chain of type IV collagen in glomerular and alveolar basement membranes (anti-GBM antibodies). Patients typically present with rapidly progressive glomerulonephritis (nephritic syndrome) and alveolar hemorrhage (shortness of breath, hemoptysis).

References

- Specificity of circulating and tissue-bound autoantibodies in Goodpasture syndrome.
- Goodpasture's disease: a report of ten cases and a review of the literature.

Pathology	Renal, Urinary Systems & Electrolytes	Anti GBM disease
Subject	System	Topic

Copyright © UWorld. All rights reserved.

A 46-year-old woman being evaluated for irregular vaginal bleeding is found to have invasive cervical carcinoma. She undergoes total abdominal hysterectomy and bilateral salpingo-oophorectomy. Pelvic lymphadenectomy was also performed, during which several enlarged nodes around the pelvic vessels were resected. A week after the surgery, the patient begins to experience left-sided flank pain that radiates to the groin. Her temperature is 36.1 C (97 F), blood pressure is 120/70 mm Hg, and pulse is 84/min. On physical examination, there is a ballotable left flank mass. Which of the following most likely accounts for this physical examination finding?

- A. Hydronephrosis
- B. Interstitial nephritis
- C. Renal cell carcinoma
- D. Renal cystic disease
- E. Renal vein thrombosis
- F. Vesicoureteral reflux

Submit

A 46-year-old woman being evaluated for irregular vaginal bleeding is found to have invasive cervical carcinoma. She undergoes total abdominal hysterectomy and bilateral salpingo-oophorectomy. Pelvic lymphadenectomy was also performed, during which several enlarged nodes around the pelvic vessels were resected. A week after the surgery, the patient begins to experience left-sided flank pain that radiates to the groin. Her temperature is 36.1 C (97 F), blood pressure is 120/70 mm Hg, and pulse is 84/min. On physical examination, there is a ballotable left flank mass. Which of the following most likely accounts for this physical examination finding?

- ✓ A. Hydronephrosis (72%)
- B. Interstitial nephritis (1%)
- C. Renal cell carcinoma (5%)
- D. Renal cystic disease (2%)
- E. Renal vein thrombosis (11%)
- F. Vesicoureteral reflux (6%)

Omitted
Correct answer
A

72%
Answered correctly

01 sec
Time Spent

06/06/2020
Last Updated

Explanation

Ureteral anatomy

Settings

1
2
3
4
5
6
7
8
9
10
11
12
13
14
15
16
17
18
19
20
21
22
23
24
25
26
27
28
29
30

Item 13 of 40
Question Id: 1916

Mark

Previous | Next | Full Screen | Tutorial | Lab Values | Notes | Calculator | Reverse Color | Text Zoom | Settings

Ureteral anatomy

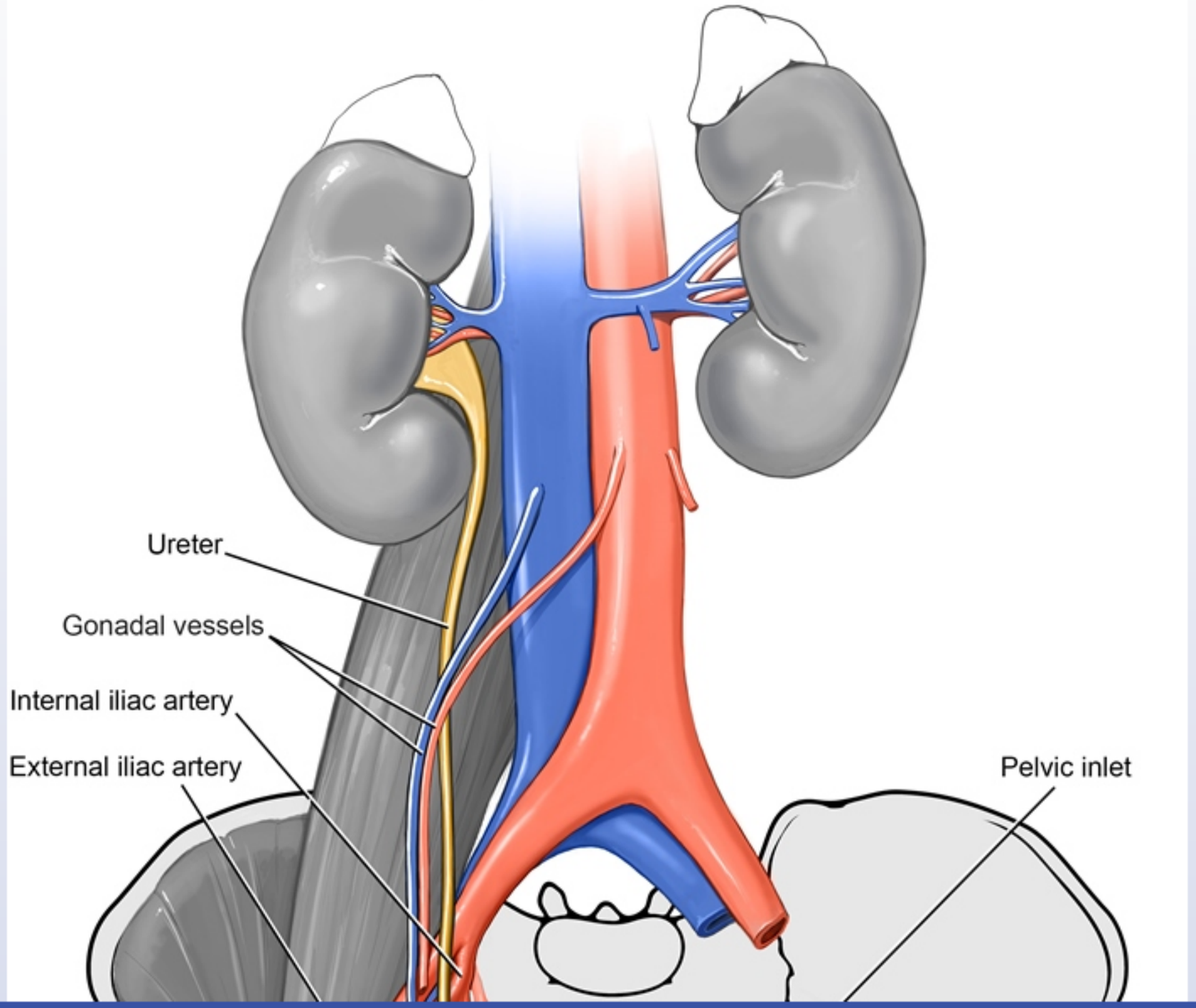

Block Time Remaining: 00:04:48
TUTOR

3 | Feedback | Suspend | End Block

Settings

1 2 3 4 5 6 7 8 9 10 11 12 13 14 15 16 17 18 19 20 21 22 23 24 25 26 27 28 29 30

Item 13 of 40
Question Id: 1916

Mark | Previous | Next | Full Screen | Tutorial | Lab Values | Notes | Calculator | Reverse Color | Text Zoom | Settings

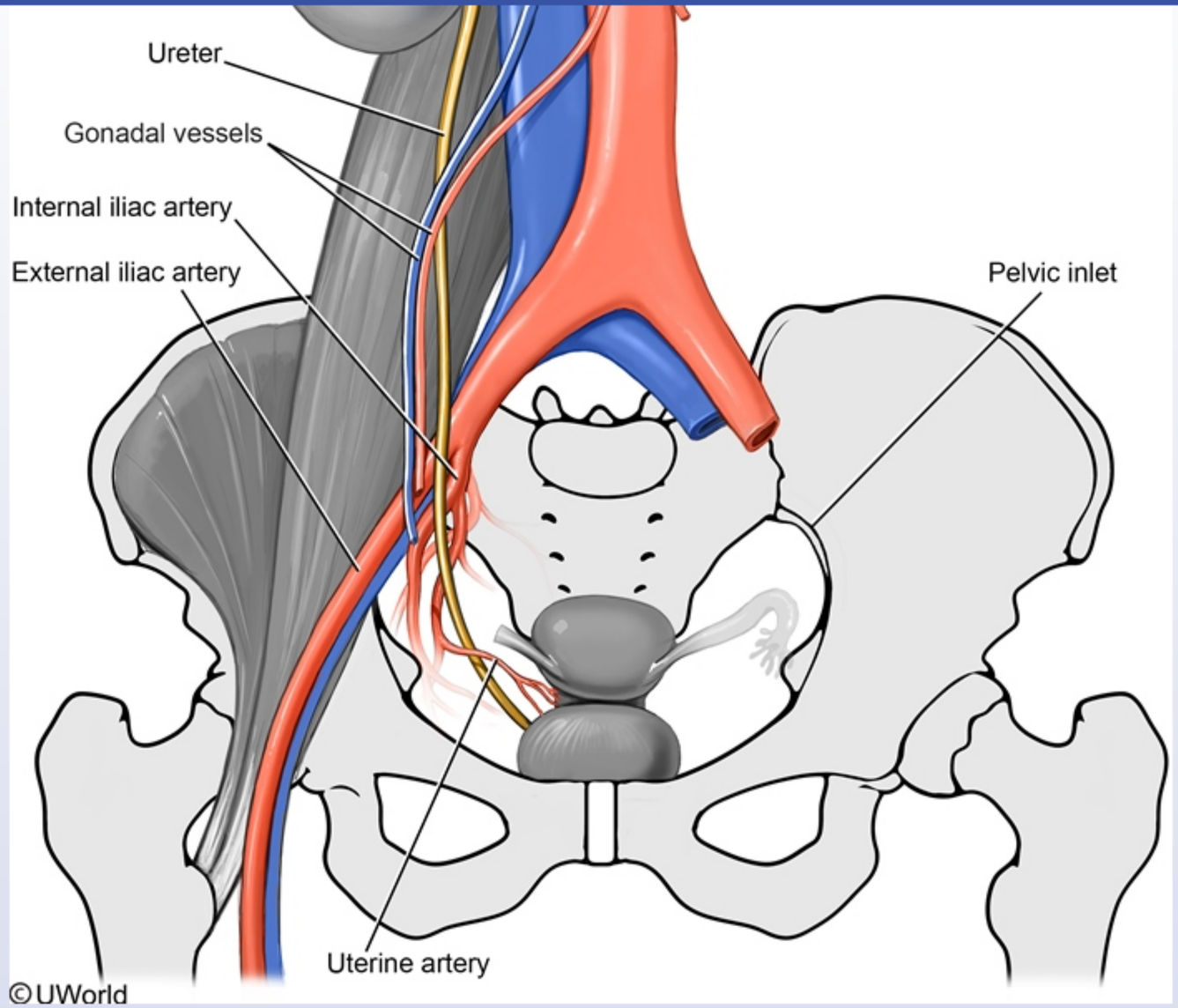

Block Time Remaining: 00:04:48
TUTOR

3 | Feedback | Suspend | End Block

Flank pain radiating to the groin with a ballotable flank mass that develops within a week of pelvic surgery suggests **ureteric obstruction**. The ureter runs in close proximity to the pelvic vessels. It courses anterior to the iliac vessels (area of resection of the pelvic nodes, which drain the uterus and cervix) and just posterior to the uterine artery near the lateral fornix of the vagina. It is vulnerable to injury during **pelvic surgery**, such as that involved in hysterectomy with pelvic lymphadenectomy. Unintentional ureteral ligation causes obstruction with hydronephrosis and flank pain due to distension of the ureter and renal pelvis. Urine output and serum creatinine remain within normal limits in most individuals with unilateral obstruction because the contralateral kidney functions normally and compensates for decreased functioning of the affected kidney.

(Choice B) Acute interstitial nephritis is classically medication induced. Signs and symptoms include fever, transient rash, and acute renal failure.

(Choices C and D) Renal cell carcinoma classically causes hematuria, flank pain, and a palpable mass. Adult polycystic kidney disease is an autosomal dominant condition characterized by multiple renal, pancreatic, and hepatic cysts. This patient had no evidence of a renal mass prior to surgery, and these conditions would not develop over a period of a week.

(Choice E) Postsurgical patients are at increased risk for deep venous thrombosis, mostly in the lower extremities or pulmonary vasculature. Renal vein thrombosis is unusual postoperatively but may be seen in patients with nephrotic syndrome.

(Choice F) Vesicoureteral reflux can be a complication of prostatectomy or bladder surgery. It predisposes to pyelonephritis and hydroureteronephrosis.

Educational objective:
The ureters run in close proximity to the pelvic lymph nodes and the uterine artery in the female pelvis, which predisposes them to injury during pelvic surgery.

References

- Complications of hysterectomy.

Pathology	Renal, Urinary Systems & Electrolytes	Urinary tract obstruction
Subject	System	Topic

Copyright © UWorld. All rights reserved.

1 2 3 4 5 6 7 8 9 10 11 12 13 14 15 16 17 18 19 20 21 22 23 24 25 26 27 28 29 30

A 5-year-old boy is brought to the office by his mother, who notes that her son's eyes and feet have looked puffy over the last several weeks. She is unaware of exactly when this began but says the patient had a mild upper respiratory tract infection several weeks ago. The boy has no pain but mentions that his shoes seem to fit tightly and bother him, especially when he runs outside during recess at school. The mother also remarks that the boy's urine has been excessively foamy recently. On further questioning, the mother states that she has seasonal allergies and asks whether her child also has allergies. Physical examination is remarkable for periorbital edema and lower extremity edema. Urinalysis shows 4+ proteinuria but is otherwise unremarkable. Which of the following secondary changes is most likely in this patient?

A. Decreased liver albumin synthesis

B. Decreased plasma aldosterone level

C. Increased capillary oncotic pressure

D. Increased liver lipoprotein synthesis

E. Increased renal sodium wasting

Submit

A 5-year-old boy is brought to the office by his mother, who notes that her son's eyes and feet have looked puffy over the last several weeks. She is unaware of exactly when this began but says the patient had a mild upper respiratory tract infection several weeks ago. The boy has no pain but mentions that his shoes seem to fit tightly and bother him, especially when he runs outside during recess at school. The mother also remarks that the boy's urine has been excessively foamy recently. On further questioning, the mother states that she has seasonal allergies and asks whether her child also has allergies. Physical examination is remarkable for periorbital edema and lower extremity edema. Urinalysis shows 4+ proteinuria but is otherwise unremarkable. Which of the following secondary changes is most likely in this patient?

A. Decreased liver albumin synthesis (8%)

B. Decreased plasma aldosterone level (4%)

C. Increased capillary oncotic pressure (12%)

✓ D. Increased liver lipoprotein synthesis (65%)

E. Increased renal sodium wasting (8%)

Omitted
Correct answer
D

65%
Answered correctly

01 sec
Time Spent

01/26/2020
Last Updated

Explanation

Overview of nephrotic syndrome

Glomerular injury

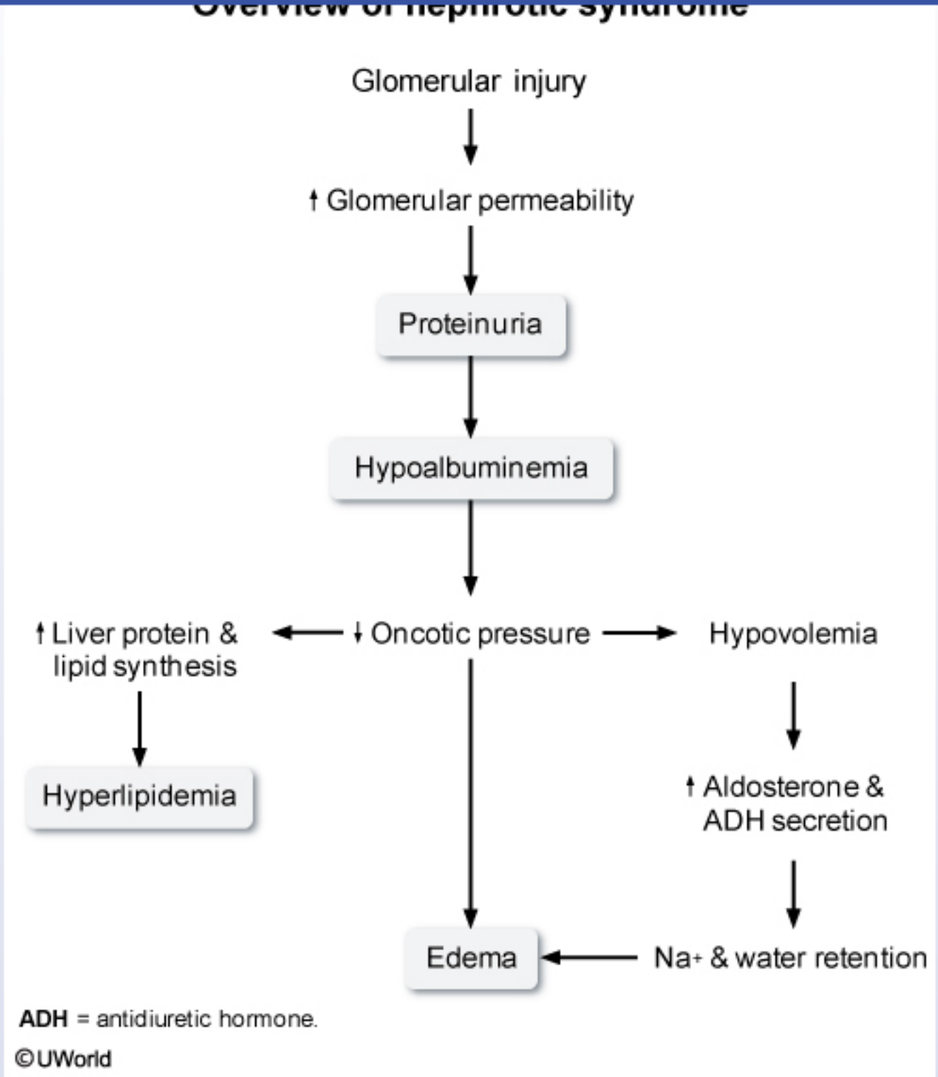

This child most likely has minimal change disease, the most common cause of **nephrotic syndrome** in children. It typically presents suddenly after an upper respiratory infection. The classic features of nephrotic syndrome are **heavy proteinuria** (>3.5 g/day in adults and >50 mg/kg/day in

1 2 3 4 5 6 7 8 9 10 11 12 13 14 15 16 17 18 19 20 21 22 23 24 25 26 27 28 29 30

This child most likely has minimal change disease, the most common cause of **nephrotic syndrome** in children. It typically presents suddenly after an upper respiratory infection. The classic features of nephrotic syndrome are **heavy proteinuria** (>3.5 g/day in adults and >50 mg/kg/day in children), **hypoalbuminemia** (<3 g/dL), **generalized edema**, and **hyperlipidemia**. Two mechanisms, underfilling and overfilling, contribute to the pathogenesis of edema in nephrotic syndrome. The underfilling mechanism is particularly significant in minimal change disease in children and presents as follows:

1. **Increased glomerular capillary permeability** to plasma proteins leads to massive **loss of protein** (predominantly albumin) in the urine.
2. The large decrease in serum albumin causes a **drop in intravascular oncotic pressure**, which results in fluid moving into the interstitial space and edema formation **(Choice C)**.
3. The fluid shift results in intravascular volume depletion (ie, underfilling), which triggers the renin-angiotensin-aldosterone system to increase aldosterone synthesis (secondary hyperaldosteronism) and antidiuretic hormone secretion **(Choice B)**. The result is intravascular **sodium and water retention (Choice E)**. This fluid leaks back out into the interstitial space due to the low oncotic pressure, exacerbating the edema.
4. Low intravascular oncotic pressure stimulates **increased lipoprotein production** in the liver. Impaired lipid catabolism due to decreased lipoprotein lipase and abnormal transport of circulating lipid particles also contributes to hyperlipidemia.

(Choice A) When the serum albumin level decreases due to its massive loss in the urine, the liver responds by increasing albumin synthesis. However, the amount of renal albumin loss exceeds the liver synthetic capacity.

Educational objective:

Minimal change disease is the most common childhood nephrotic syndrome. Increased glomerular capillary permeability causes massive protein (eg, albumin) loss in the urine. Hypoalbuminemia reduces plasma oncotic pressure, which causes a fluid shift into the interstitial space, resulting in edema. Low oncotic pressure also triggers increased lipoprotein production in the liver (ie, hyperlipidemia).

References

- Pathophysiology, evaluation, and management of edema in childhood nephrotic syndrome.
- The pathophysiology of edema formation in the nephrotic syndrome.

Exhibit Display

Mechanism of edema formation in nephrotic syndrome

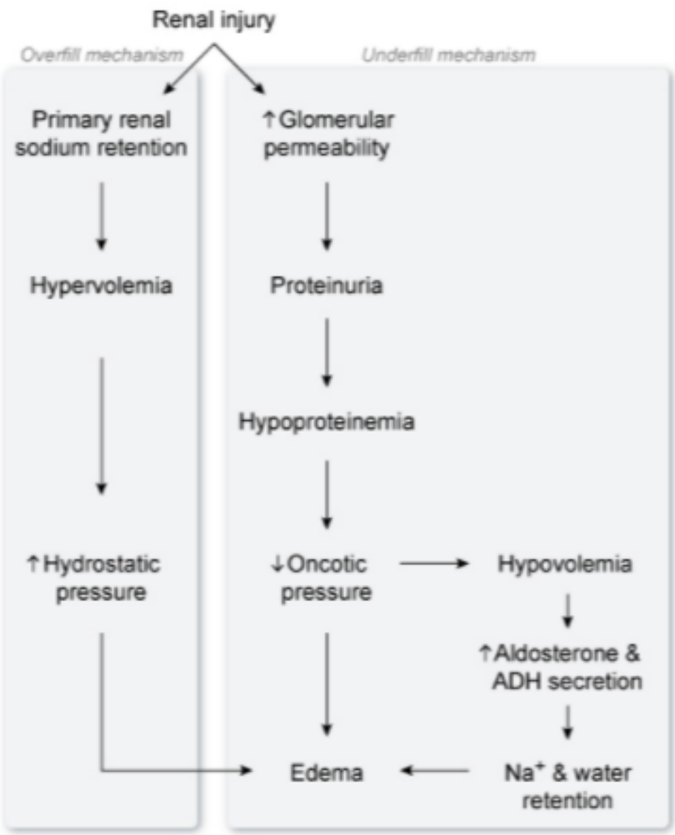

Contribution of each is variable over time & per patient.

©UWorld

Zoom In | Zoom Out | Reset | Add To New Card | Existing Card

1 2 3 4 5 6 7 8 9 10 11 12 13 14 15 16 17 18 19 20 21 22 23 24 25 26 27 28 29 30

presents as follows:

1. **Increased glomerular capillary permeability** to plasma proteins leads to massive **loss of protein** (predominantly albumin) in the urine.
2. The large decrease in serum albumin causes a **drop in intravascular oncotic pressure**, which results in fluid moving into the interstitial space and edema formation **(Choice C)**.
3. The fluid shift results in intravascular volume depletion (ie, underfilling), which triggers the renin-angiotensin-aldosterone system to increase aldosterone synthesis (secondary hyperaldosteronism) and antidiuretic hormone secretion **(Choice B)**. The result is intravascular **sodium and water retention (Choice E)**. This fluid leaks back out into the interstitial space due to the low oncotic pressure, exacerbating the edema.
4. Low intravascular oncotic pressure stimulates **increased lipoprotein production** in the liver. Impaired lipid catabolism due to decreased lipoprotein lipase and abnormal transport of circulating lipid particles also contributes to hyperlipidemia.

(Choice A) When the serum albumin level decreases due to its massive loss in the urine, the liver responds by increasing albumin synthesis. However, the amount of renal albumin loss exceeds the liver synthetic capacity.

Educational objective:

Minimal change disease is the most common childhood nephrotic syndrome. Increased glomerular capillary permeability causes massive protein (eg, albumin) loss in the urine. Hypoalbuminemia reduces plasma oncotic pressure, which causes a fluid shift into the interstitial space, resulting in edema. Low oncotic pressure also triggers increased lipoprotein production in the liver (ie, hyperlipidemia).

References

- Pathophysiology, evaluation, and management of edema in childhood nephrotic syndrome.
- The pathophysiology of edema formation in the nephrotic syndrome.

Pathology	Renal, Urinary Systems & Electrolytes	Glomerular disorders
Subject	System	Topic

Copyright © UWorld. All rights reserved.

A 54-year-old man comes to the hospital due to acute-onset right flank pain associated with nausea. Five years ago, the patient had nephrolithiasis; the renal calculi passed spontaneously with intravenous fluids. Review of systems is positive for occasional palpitations. Other medical problems include hypertension, obesity, and obstructive sleep apnea. Temperature is 38 C (100.4 F), blood pressure is 170/98 mm Hg, pulse is 90/min, and respirations are 18/min. Cardiopulmonary examination shows no abnormalities. Right flank tenderness is present. Urinalysis demonstrates 2+ red blood cells and no white blood cells or protein. A representative sample of a kidney from another patient is shown below:

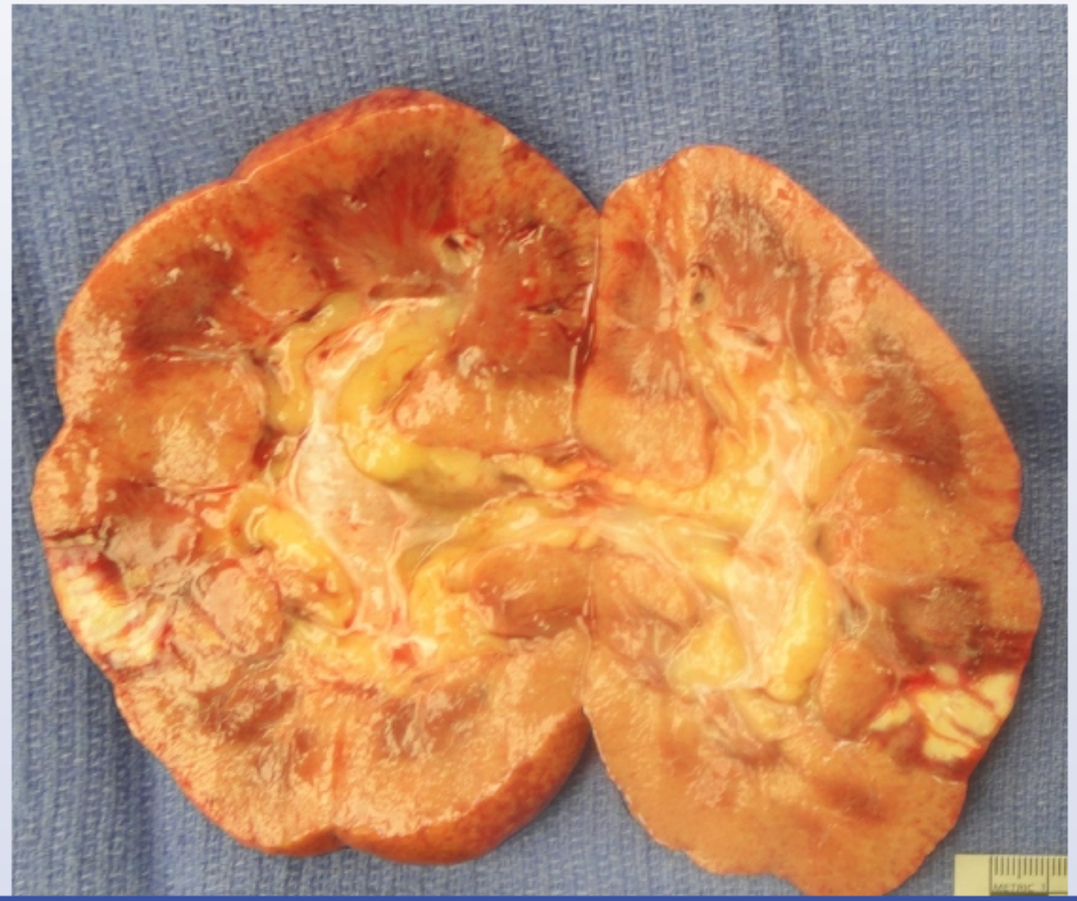

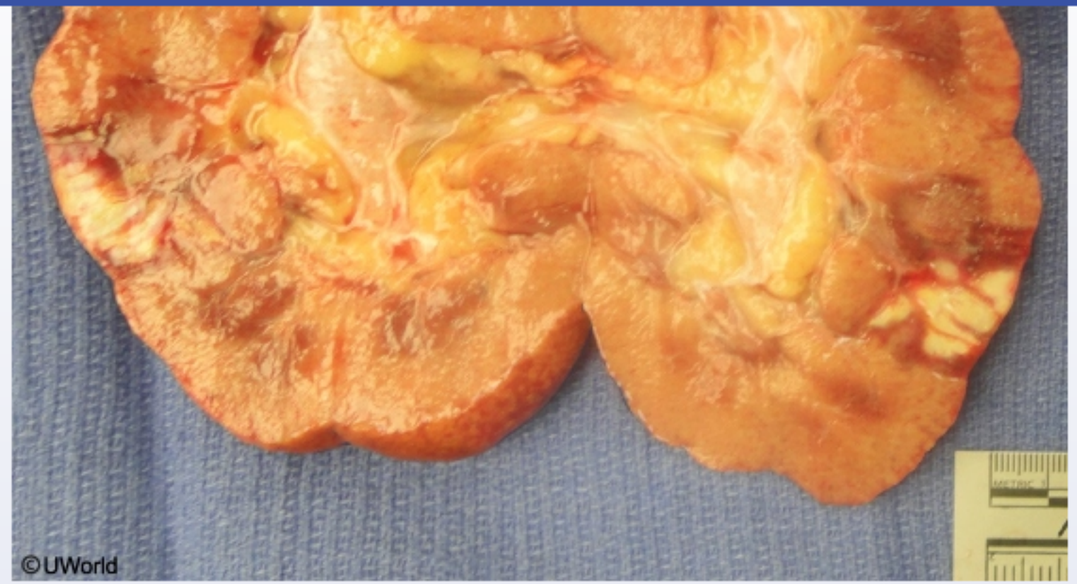

What is the diagnosis for this patient?

- A. Nephrolithiasis
- B. Pyelonephritis
- C. Renal cell carcinoma
- D. Renal infarction
- E. Renal papillary necrosis

Submit

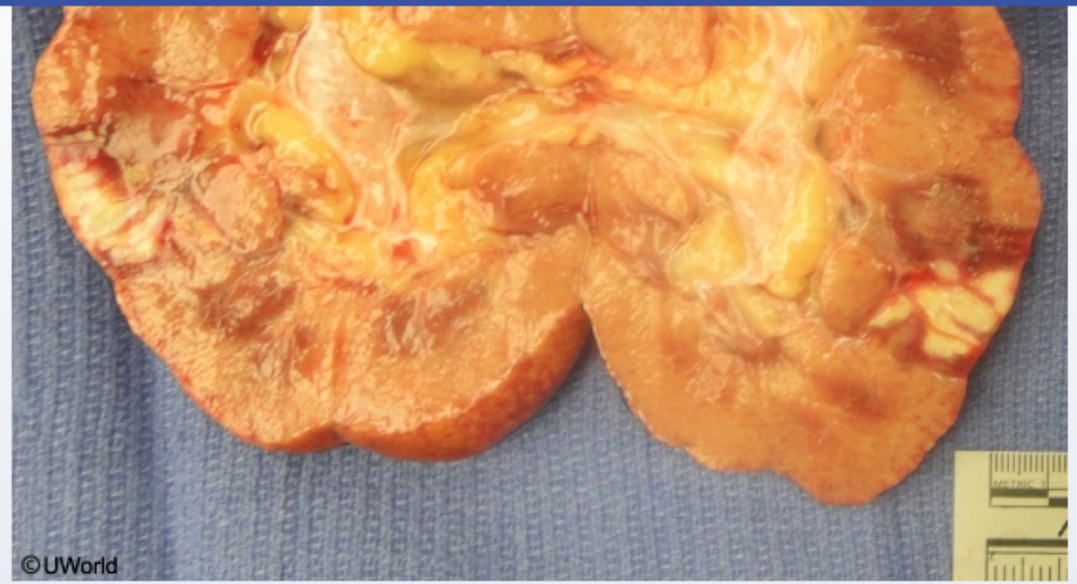

What is the diagnosis for this patient?

- A. Nephrolithiasis (5%)
- B. Pyelonephritis (10%)
- C. Renal cell carcinoma (14%)
- ✓ D. Renal infarction (50%)
- E. Renal papillary necrosis (18%)

Omitted
Correct answer

50%
Answered correctly

04 secs
Time Spent

02/19/2020
Last Updated

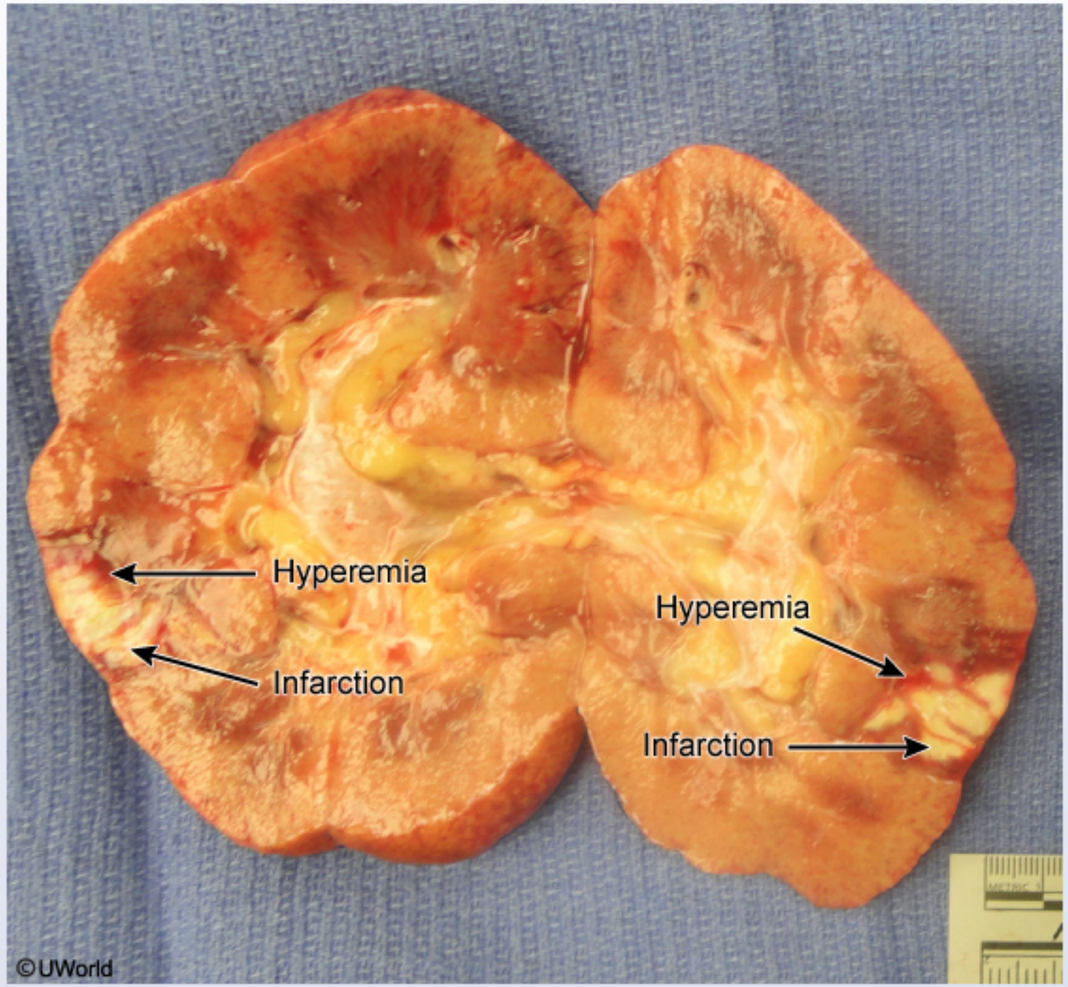

This patient with flank pain, low-grade fever, and hematuria likely had a **renal infarction**. Renal infarctions are most commonly caused by **cardioembolic disease** (ie, originating from the left atrium or ventricle). **Atrial fibrillation**, suggested by this patient's intermittent palpitations and history of sleep apnea, is the greatest risk factor, although emboli from mural thrombi (following myocardial infarction), prosthetic valves, or valvular vegetations (ie, endocarditis) are also implicated. Complete occlusion of the renal artery can occur more rarely due to direct arterial injury

This patient with flank pain, low-grade fever, and hematuria likely had a **renal infarction**. Renal infarctions are most commonly caused by **cardioembolic disease** (ie, originating from the left atrium or ventricle). **Atrial fibrillation**, suggested by this patient's intermittent palpitations and history of sleep apnea, is the greatest risk factor, although emboli from mural thrombi (following myocardial infarction), prosthetic valves, or valvular vegetations (ie, endocarditis) are also implicated. Complete occlusion of the renal artery can occur more rarely due to direct arterial injury (eg, dissection, vasculitis) or hypercoagulable states (eg, antiphospholipid syndrome). The kidneys are predisposed to embolic infarctions due to their high perfusion rates and limited collateral circulation.

Typical presenting symptoms include **flank pain**, **nausea**, vomiting, and low-grade fever. **Hypertension** can occur due to renin release from hypoxic tissue. Common laboratory abnormalities include elevated lactate dehydrogenase (suggesting cell necrosis), hematuria, and mild leukocytosis; however, serum creatinine is often normal unless bilateral or massive unilateral disease is present. Gross pathology shows sharply demarcated, yellow-white, **wedge-shaped infarcts** surrounded by hyperemic tissue.

(Choice A) Nephrolithiasis can cause flank pain and hematuria, but renal injury is typically due to obstruction, causing hydronephrosis. Renal calyces and ureters are dilated, and infarctions do not occur.

(Choice B) Pyelonephritis can also cause flank pain and nausea, and a focal abscess can be seen. However, pyuria is expected on urinalysis and patients typically have dysuria.

(Choice C) Renal cell carcinoma can cause flank pain and hematuria, but gross pathology demonstrates yellow, well-circumscribed, fungating lesions with areas of focal hemorrhage.

(Choice E) Papillary necrosis, often caused by excessive chronic analgesic use, demonstrates cortical atrophy with necrotic, sloughing papillae. Focal, wedge-shaped necrosis is not seen.

Educational objective:
Renal infarctions are most commonly caused by cardioembolic disease; atrial fibrillation is the greatest risk factor. Clinical features include flank pain, nausea, vomiting, low-grade fever, and hypertension (due to renin release from hypoxic tissue). Gross pathology demonstrates sharply demarcated, yellow-white, wedge-shaped areas with surrounding hyperemia.

Settings

1 2 3 4 5 6 7 8 9 10 11 12 13 14 15 16 17 18 19 20 21 22 23 24 25 26 27 28 29 30

Item 15 of 40
Question Id: 15288

Mark | Previous | Next | Full Screen | Tutorial | Lab Values | Notes | Calculator | Reverse Color | Text Zoom | Settings

Exhibit Display

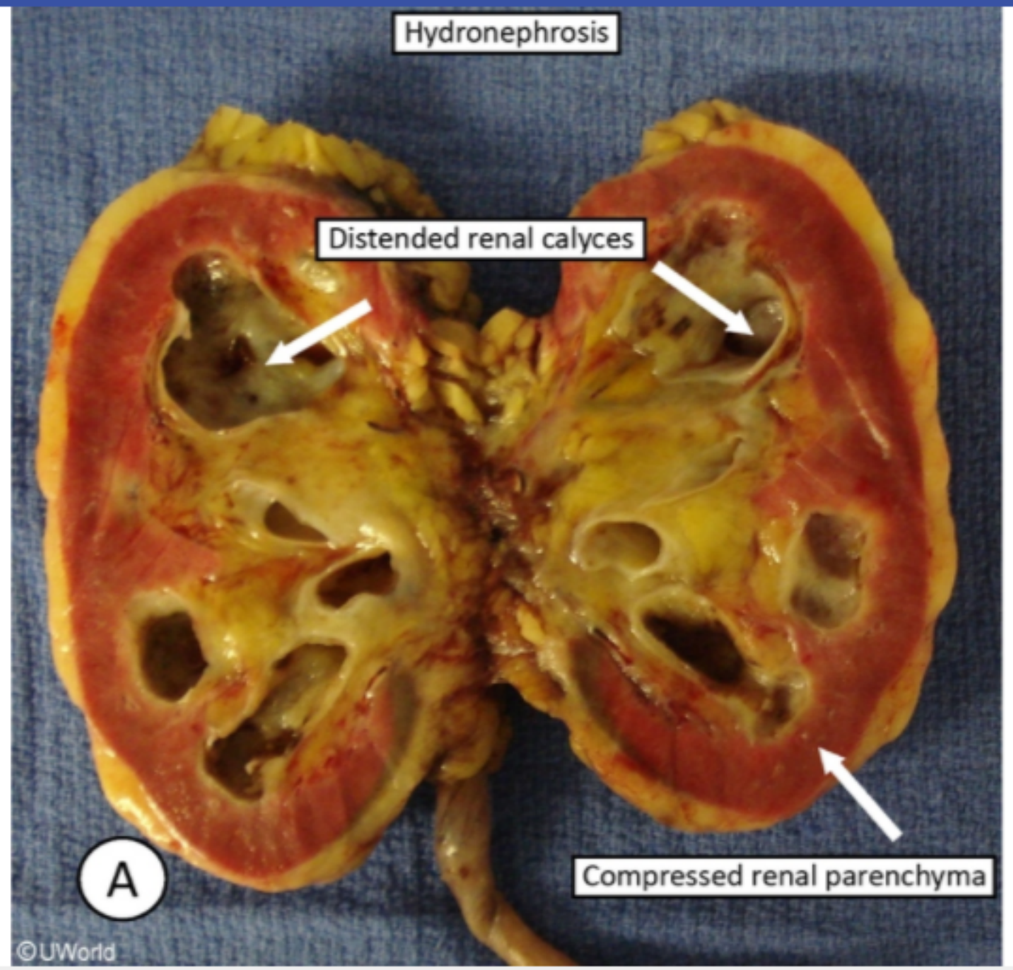

Zoom In | Zoom Out | Reset | Add To New Card | Existing Card

Block Time Remaining: 00:04:53
TUTOR

5 | Feedback | Suspend | End Block

Settings

1 2 3 4 5 6 7 8 9 10 11 12 13 14 15 16 17 18 19 20 21 22 23 24 25 26 27 28 29 30

Item 15 of 40
Question Id: 15288

Mark | Previous | Next | Full Screen | Tutorial | Lab Values | Notes | Calculator | Reverse Color | Text Zoom | Settings

Exhibit Display

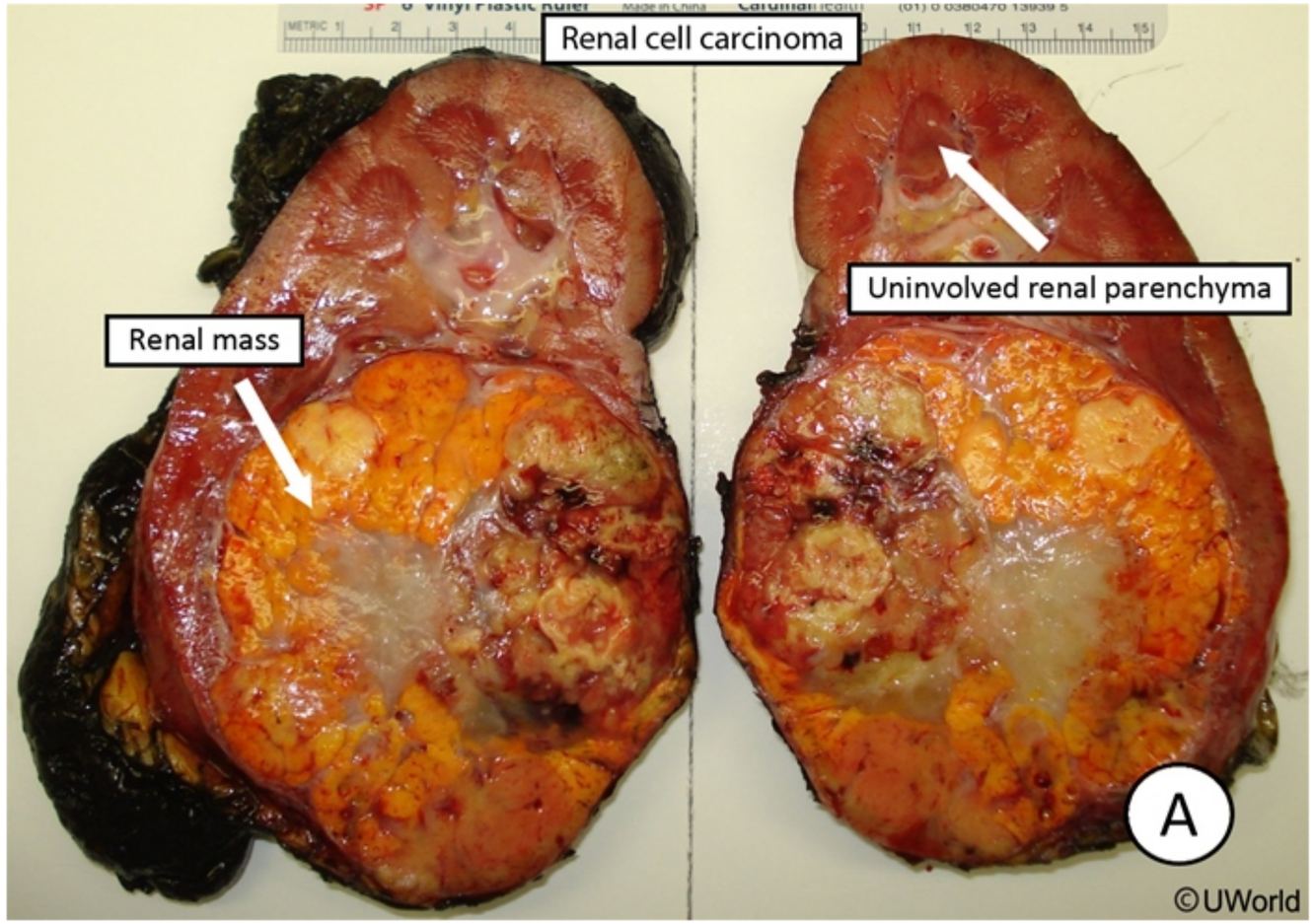

Zoom In | Zoom Out | Reset | Add To New Card | Existing Card

Block Time Remaining: 00:04:53
TUTOR

5 | Feedback | Suspend | End Block

1 2 3 4 5 6 7 8 9 10 11 12 13 14 15 16 17 18 19 20 21 22 23 24 25 26 27 28 29 30

A 32-year-old woman comes to the emergency department with sudden-onset left flank pain and nausea. The pain radiates to the left groin and she is unable to find a comfortable position on the examination table. The pain is intermittent and waxes and wanes in severity. Temperature is 36.7 C (98 F), blood pressure is 140/90 mm Hg, and pulse is 92/min. She has mild tenderness to percussion over the left flank. Bowel sounds are hypoactive. Which of the following recommendations would most likely prevent a recurrence of this patient's condition?

- A. Avoid alcohol use
- B. Complete a course of antibiotics
- C. Drink plenty of water daily
- D. Follow a high-fiber diet
- E. Follow a high-sodium diet
- F. Follow a low-calcium diet
- G. Follow safe sexual practices

Submit

A 32-year-old woman comes to the emergency department with sudden-onset left flank pain and nausea. The pain radiates to the left groin and she is unable to find a comfortable position on the examination table. The pain is intermittent and waxes and wanes in severity. Temperature is 36.7 C (98 F), blood pressure is 140/90 mm Hg, and pulse is 92/min. She has mild tenderness to percussion over the left flank. Bowel sounds are hypoactive. Which of the following recommendations would most likely prevent a recurrence of this patient's condition?

- A. Avoid alcohol use (1%)
- B. Complete a course of antibiotics (2%)
- ✓ C. Drink plenty of water daily (82%)
- D. Follow a high-fiber diet (6%)
- E. Follow a high-sodium diet (0%)
- F. Follow a low-calcium diet (5%)
- G. Follow safe sexual practices (2%)

Omitted
Correct answer
C

82%
Answered correctly

02 secs
Time Spent

05/26/2020
Last Updated

Explanation

Risk & prevention of kidney stones		

Risk & prevention of kidney stones

Stone type	Risk factors	Prevention
Calcium stones (oxalate, phosphate)	• Hypercalciuria (eg, hyperparathyroidism) • Hyperoxaluria (eg, malabsorption, low-calcium diet) • Hypocitraturia (eg, distal RTA) • Diet: ↑ sodium, ↑ protein, ↑ oxalate, ↓ calcium	• Reduce sodium, animal protein, oxalate intake • Increase potassium intake; moderate calcium intake • Thiazide diuretics
Uric acid	• Gout • Myeloproliferative disorders	• Urine alkalinization • Allopurinol
Magnesium ammonium phosphate (struvite)	• Recurrent upper urinary infection (eg, *Klebsiella*, *Proteus*)	• Stone removal • Suppressive antibiotics
All types	• Dehydration	• Increase fluid intake

RTA = renal tubular acidosis.

This patient has acute flank pain and tenderness consistent with **nephrolithiasis**. The pain associated with nephrolithiasis (renal colic) is often severe and, although it may wax and wane, is generally not positional. The pain commonly radiates to the groin, especially as the stone passes down the ureter to the ureterovesical junction. Nausea and vomiting are common, and bowel sounds are often diminished due to an associated ileus. Hematuria is usually present but may not be grossly visible.

Most kidney stones are calcium-based (calcium oxalate, calcium phosphate). But regardless of chemical composition, low fluid intake can lead to **supersaturation** of urine with crystalline material and promote stone formation. **Increasing fluid intake** can reduce the risk of all types of stones.

(Choice A) Excessive alcohol intake can trigger acute pancreatitis. The pain associated with pancreatitis is typically located in the epigastric area rather than the flank and radiates to the back rather than the groin.

This patient has acute flank pain and tenderness consistent with **nephrolithiasis**. The pain associated with nephrolithiasis (renal colic) is often severe and, although it may wax and wane, is generally not positional. The pain commonly radiates to the groin, especially as the stone passes down the ureter to the ureterovesical junction. Nausea and vomiting are common, and bowel sounds are often diminished due to an associated ileus. Hematuria is usually present but may not be grossly visible.

Most kidney stones are calcium-based (calcium oxalate, calcium phosphate). But regardless of chemical composition, low fluid intake can lead to **supersaturation** of urine with crystalline material and promote stone formation. **Increasing fluid intake** can reduce the risk of all types of stones.

(Choice A) Excessive alcohol intake can trigger acute pancreatitis. The pain associated with pancreatitis is typically located in the epigastric area rather than the flank and radiates to the back rather than the groin.

(Choice B) Recurrent infections of the upper urinary tract with urease-producing organisms (eg, *Klebsiella*, *Proteus*) can lead to formation of magnesium ammonium phosphate (struvite) stones. These stones are often large and may fill the renal pelvis. Although patients may have mild flank pain due to recurrent infection, acute renal colic is uncommon as these large stones do not travel down the ureter.

(Choice D) A high-fiber diet is associated with a decreased risk of diverticulitis. This condition typically presents over a few days (not suddenly, as in this patient) with lower abdominal pain and tenderness in the left lower quadrant.

(Choice E) Calcium passively follows the reabsorption of sodium and water in the renal tubules. Increased dietary sodium intake leads to reduced sodium reabsorption in the proximal tubule and lowers calcium reabsorption (leading to hypercalciuria).

(Choice F) Dietary calcium binds oxalate in the gut to form unabsorbable calcium oxalate. Low-calcium diets lead to increased absorption of free oxalate, which is then excreted in the urine; the resulting hyperoxaluria promotes the formation of calcium oxalate stones. Low-calcium diets are therefore paradoxically associated with increased risk of stone formation.

(Choice G) Untreated infection with chlamydia or gonorrhea can lead to pelvic inflammatory disease, presenting with lower abdominal pain and fever. Examination findings include mucopurulent cervical discharge and cervical motion tenderness.

Educational objective:
Urine supersaturation is the main mechanism underlying all types of renal stones. Low fluid intake increases the concentration of stone-forming agents, thereby promoting stone formation. All patients with nephrolithiasis should be advised to maintain adequate fluid intake.

1 2 3 4 5 6 7 8 9 10 11 12 13 14 15 16 17 18 19 20 21 22 23 24 25 26 27 28 29 30

rather than the flank and radiates to the back rather than the groin.

(Choice B) Recurrent infections of the upper urinary tract with urease-producing organisms (eg, *Klebsiella*, *Proteus*) can lead to formation of magnesium ammonium phosphate (struvite) stones. These stones are often large and may fill the renal pelvis. Although patients may have mild flank pain due to recurrent infection, acute renal colic is uncommon as these large stones do not travel down the ureter.

(Choice D) A high-fiber diet is associated with a decreased risk of diverticulitis. This condition typically presents over a few days (not suddenly, as in this patient) with lower abdominal pain and tenderness in the left lower quadrant.

(Choice E) Calcium passively follows the reabsorption of sodium and water in the renal tubules. Increased dietary sodium intake leads to reduced sodium reabsorption in the proximal tubule and lowers calcium reabsorption (leading to hypercalciuria).

(Choice F) Dietary calcium binds oxalate in the gut to form unabsorbable calcium oxalate. Low-calcium diets lead to increased absorption of free oxalate, which is then excreted in the urine; the resulting hyperoxaluria promotes the formation of calcium oxalate stones. Low-calcium diets are therefore paradoxically associated with increased risk of stone formation.

(Choice G) Untreated infection with chlamydia or gonorrhea can lead to pelvic inflammatory disease, presenting with lower abdominal pain and fever. Examination findings include mucopurulent cervical discharge and cervical motion tenderness.

Educational objective:
Urine supersaturation is the main mechanism underlying all types of renal stones. Low fluid intake increases the concentration of stone-forming agents, thereby promoting stone formation. All patients with nephrolithiasis should be advised to maintain adequate fluid intake.

References

- Treatment and prevention of kidney stones: an update.

Pathology	Renal, Urinary Systems & Electrolytes	Renal calculi
Subject	System	Topic

Copyright © UWorld. All rights reserved.

A 44-year-old homeless man is brought to the hospital after being found unresponsive. Temperature is 35.6 C (96.1 F), blood pressure is 120/80 mm Hg, and pulse is 110/min. He is responsive only to pain and has dry mucous membranes. The patient's condition is initially treated with intravenous fluids, and his mental status slowly improves, but urine output decreases and flank pain develops. A renal biopsy reveals marked ballooning and vacuolar degeneration of proximal renal tubules; multiple oxalate crystals are observed in the tubular lumen. Which of the following is most likely responsible for this patient's acute kidney injury?

- A. Direct tubular injury due to exogenous toxin ingestion
- B. Direct tubular injury from filtered monoclonal light chains
- C. Increased endogenous parathyroid hormone production
- D. Microthrombosis of the glomerular capillaries
- E. Prerenal azotemia due to splanchnic vasodilation

Submit

A 44-year-old homeless man is brought to the hospital after being found unresponsive. Temperature is 35.6 C (96.1 F), blood pressure is 120/80 mm Hg, and pulse is 110/min. He is responsive only to pain and has dry mucous membranes. The patient's condition is initially treated with intravenous fluids, and his mental status slowly improves, but urine output decreases and flank pain develops. A renal biopsy reveals marked ballooning and vacuolar degeneration of proximal renal tubules; multiple oxalate crystals are observed in the tubular lumen. Which of the following is most likely responsible for this patient's acute kidney injury?

- ✓ A. Direct tubular injury due to exogenous toxin ingestion (61%)
- B. Direct tubular injury from filtered monoclonal light chains (4%)
- C. Increased endogenous parathyroid hormone production (9%)
- D. Microthrombosis of the glomerular capillaries (6%)
- E. Prerenal azotemia due to splanchnic vasodilation (17%)

Omitted
Correct answer
A

61%
Answered correctly

02 secs
Time Spent

01/25/2020
Last Updated

Explanation

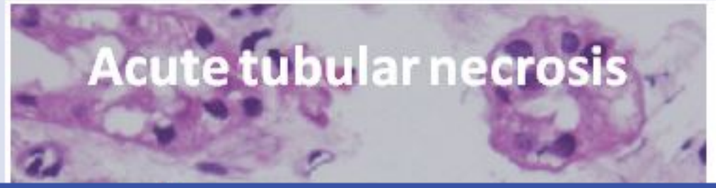

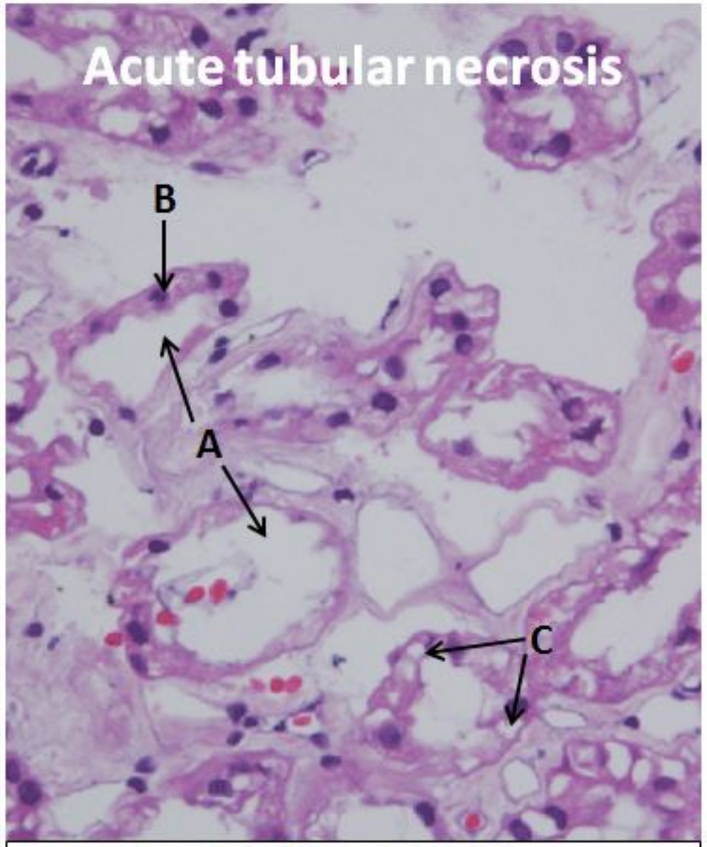

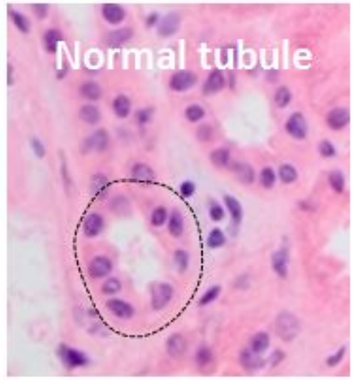

Outer medulla of the kidney (H&E stain)
(a) Patchy loss of proximal tubular epithelial cells with tubular dilation; (b) regenerating epithelial cells with hyperchromatic nuclei; (c) epithelial cell vacuolization.

This patient has altered mental status and acute renal failure. In conjunction with the oxalate crystals noted on renal biopsy, this presentation is consistent with **ethylene glycol poisoning**. Ethylene glycol is a toxic alcohol found in antifreeze, engine coolants, and brake fluids and may be accidentally or intentionally ingested (used as a substitute for alcohol). Patients initially have symptoms of ethanol intoxication; signs of acute

hyperchromatic nuclei; (c) epithelial cell vacuolization.

This patient has altered mental status and acute renal failure. In conjunction with the oxalate crystals noted on renal biopsy, this presentation is consistent with **ethylene glycol poisoning**. Ethylene glycol is a toxic alcohol found in antifreeze, engine coolants, and brake fluids and may be accidentally or intentionally ingested (used as a substitute for alcohol). Patients initially have symptoms of ethanol intoxication; signs of acute renal failure (oliguria, flank pain) develop approximately 24-72 hours after ingestion. Ethylene glycol itself is relatively nontoxic; however, it is metabolized to glycolic acid and oxalic acid, resulting in its various toxicities.

Acute kidney injury occurs due to both glycolic acid, which causes **direct tubular cytotoxicity**, and oxalic acid, which crystalizes and causes tubular obstruction. This results in **acute tubular necrosis** (ATN), demonstrated histologically by **proximal tubular** cell ballooning and vacuolar **degeneration** with morphologically normal glomeruli. Urinalysis shows tubular casts and oxalate crystals. Other common laboratory findings include a markedly elevated anion gap metabolic acidosis (due to acid metabolite formation) and an elevated osmolar gap (due to the uncharged parent alcohol).

(Choice B) Multiple myeloma can cause light-chain cast nephropathy due to obstruction of the proximal tubules. This causes ATN, but biopsy demonstrates eosinophilic (light-chain) casts, not oxalate crystals. It also typically occurs in older patients and presents with hypercalcemia and anemia; altered mentation is unexpected.

(Choice C) Hyperparathyroidism causes hypercalcemia, which predisposes patients to calcium stone (eg, calcium oxalate) formation. However, kidney stones typically cause postobstructive nephropathy with cortical atrophy and blunting of calyces; ATN would be unexpected.

(Choice D) Thrombotic microangiopathies (eg, hemolytic uremic syndrome) cause endothelial injury characterized by microthrombi in the glomerular capillaries and fibrinoid necrosis of the arterioles; schistocytes are commonly seen on microscopy. Proximal tubules are typically unaffected, and oxalate crystals would not be seen.

(Choice E) Advanced liver disease with portal hypertension and splanchnic vasodilation may lead to renal failure (hepatorenal syndrome). The hallmark of this condition is renal vasoconstriction, resulting in prerenal azotemia. The kidneys are histologically normal and resume function following liver transplantation.

Educational objective:
Ethylene glycol ingestion causes acute tubular necrosis with vacuolar degeneration and ballooning of the proximal tubular cells. Typical clinical

hyperchromatic nuclei; (c) epithelial cell vacuolization.

Exhibit Display

Crystals causing kidney stones Urinary calcium oxalate & triple phosphate crystal

Calcium oxalate
(dihydrate)



©UWorld

Zoom In | Zoom Out | Reset | Add To New Card | Existing Card

Ethylene glycol ingestion causes acute tubular necrosis with vacuolar degeneration and ballooning of the proximal tubular cells. Typical clinical

hyperchromatic nuclei; (c) epithelial cell vacuolization.

Exhibit Display

Crystals causing kidney stones Urinary calcium oxalate & triple phosphate crystal

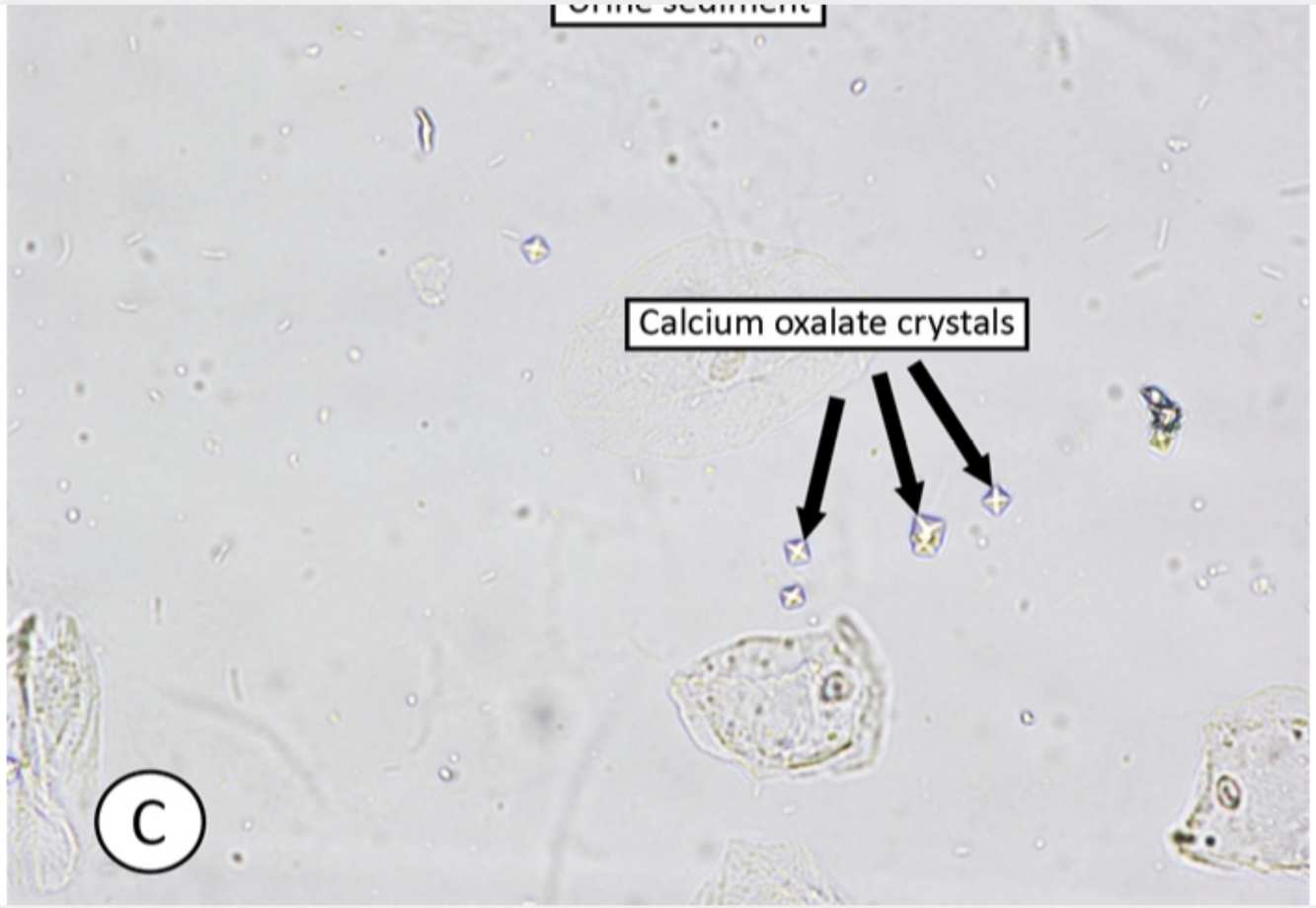

Zoom In | Zoom Out | Reset | Add To New Card | Existing Card

Ethylene glycol ingestion causes acute tubular necrosis with vacuolar degeneration and ballooning of the proximal tubular cells. Typical clinical

include a markedly elevated anion gap metabolic acidosis (due to acid metabolite formation) and an elevated osmolar gap (due to the uncharged parent alcohol).

(Choice B) Multiple myeloma can cause light-chain cast nephropathy due to obstruction of the proximal tubules. This causes ATN, but biopsy demonstrates eosinophilic (light-chain) casts, not oxalate crystals. It also typically occurs in older patients and presents with hypercalcemia and anemia; altered mentation is unexpected.

(Choice C) Hyperparathyroidism causes hypercalcemia, which predisposes patients to calcium stone (eg, calcium oxalate) formation. However, kidney stones typically cause postobstructive nephropathy with cortical atrophy and blunting of calyces; ATN would be unexpected.

(Choice D) Thrombotic microangiopathies (eg, hemolytic uremic syndrome) cause endothelial injury characterized by microthrombi in the glomerular capillaries and fibrinoid necrosis of the arterioles; schistocytes are commonly seen on microscopy. Proximal tubules are typically unaffected, and oxalate crystals would not be seen.

(Choice E) Advanced liver disease with portal hypertension and splanchnic vasodilation may lead to renal failure (hepatorenal syndrome). The hallmark of this condition is renal vasoconstriction, resulting in prerenal azotemia. The kidneys are histologically normal and resume function following liver transplantation.

Educational objective:
Ethylene glycol ingestion causes acute tubular necrosis with vacuolar degeneration and ballooning of the proximal tubular cells. Typical clinical findings include altered mentation, renal failure, high anion gap metabolic acidosis, increased osmolar gap, and calcium oxalate crystals in the urine.

References

- Toxic alcohol ingestions: clinical features, diagnosis, and management.

Pathology	Renal, Urinary Systems & Electrolytes	Acute kidney injury
Subject	System	Topic

Copyright © UWorld. All rights reserved.

include a markedly elevated anion gap metabolic acidosis (due to acid metabolite formation) and an elevated osmolar gap (due to the uncharged

Exhibit Display

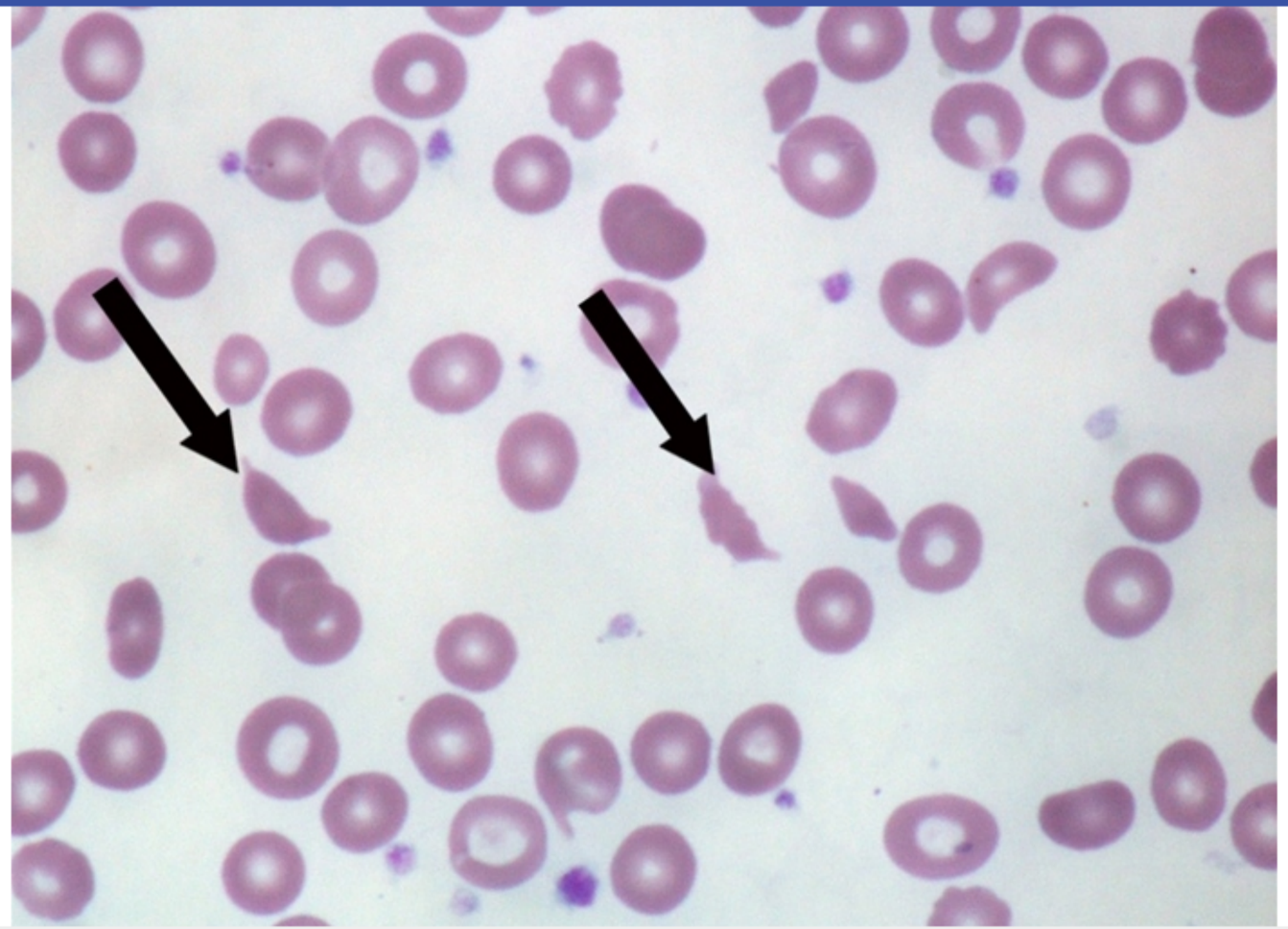

Zoom In | Zoom Out | Reset | Add To New Card | Existing Card

1 2 3 4 5 6 7 8 9 10 11 12 13 14 15 16 17 18 19 20 21 22 23 24 25 26 27 28 29 30

A 26-year-old woman dies shortly after a sudden-onset, severe headache. She was recently diagnosed with hypertension but otherwise had no medical problems. The patient was a lifetime nonsmoker and did not use illicit drugs. Autopsy reveals evidence of intracranial hemorrhage. Both carotid arteries appear tortuous distally with alternating areas of fibrotic webs and aneurysmal dilation. On microscopic examination, the aneurysmal segments of the carotid arteries lack an internal elastic lamina. Which of the following is the most likely additional finding in this patient?

A. Adrenal tumor

B. Coarctation of the aorta

C. Hypertrophic cardiomyopathy

D. Renal artery stenosis

E. Thyroid follicular hyperplasia

Submit

A 26-year-old woman dies shortly after a sudden-onset, severe headache. She was recently diagnosed with hypertension but otherwise had no medical problems. The patient was a lifetime nonsmoker and did not use illicit drugs. Autopsy reveals evidence of intracranial hemorrhage. Both carotid arteries appear tortuous distally with alternating areas of fibrotic webs and aneurysmal dilation. On microscopic examination, the aneurysmal segments of the carotid arteries lack an internal elastic lamina. Which of the following is the most likely additional finding in this patient?

- A. Adrenal tumor (6%)
- B. Coarctation of the aorta (33%)
- C. Hypertrophic cardiomyopathy (6%)
- ✓ D. Renal artery stenosis (51%)
- E. Thyroid follicular hyperplasia (1%)

Omitted
Correct answer
D

51%
Answered correctly

02 secs
Time Spent

05/02/2020
Last Updated

Explanation

Fibromuscular dysplasia	
Manifestations	• Fibromuscular webs (luminal stenosis) alternating with areas of aneurysmal dilation • Loss of the internal elastic lamina

Explanation

Fibromuscular dysplasia	
Manifestations	• Fibromuscular webs (luminal stenosis) alternating with areas of aneurysmal dilation • Loss of the internal elastic lamina • Most common in women, age <55
Presentation	• Resistant hypertension (RAS) • CNS involvement: Headache, TIA, stroke, ruptured aneurysm
Diagnosis	• Angiography (CT, MRI, percutaneous) • String-of-beads appearance (multifocal disease)

RAS = renal artery stenosis; **TIA** = transient ischemic attack.

This young woman with recent-onset hypertension died of an intracranial hemorrhage, likely from a ruptured aneurysm. This, in conjunction with the characteristic pathology findings of **fibromuscular webs** alternating with **aneurysmal dilation** and loss of the internal elastic lamina, is consistent with **fibromuscular dysplasia** (FMD). FMD is a nonatherosclerotic disease characterized by abnormal tissue growth within arterial walls, leading to arterial stenosis, tortuosity, aneurysms, or dissections. FMD typically occurs in women age <55. Angiography (ie, percutaneous, CT, MRI) is diagnostic and typically demonstrates a **string-of-beads** appearance in multifocal disease.

FMD can involve any artery but most commonly the renal, cerebral (eg, carotid, vertebral), and visceral arteries. Up to 80% of patients develop **renal artery stenosis**, which limits renal perfusion and leads to activation of the renin-angiotensin-aldosterone system. The resultant **hypertension** is often the earliest sign of the disease. Other presentations are related to locations of the dysplastic artery; **cerebrovascular involvement** (ie, headache, stroke, aneurysm rupture), mesenteric ischemia, or extremity claudication may be seen.

(Choices A and B) Adrenal tumors that can present with severe hypertension include pheochromocytoma and aldosterone- or cortisol-secreting adrenocortical adenomas. Coarctation of the aorta also causes hypertension, with blood pressure higher in the upper versus lower extremities. Due to the elevated blood pressure, these diseases can cause headaches and intraparenchymal hemorrhage in predisposed individuals, but they

This young woman with recent-onset hypertension died of an intracranial hemorrhage, likely from a ruptured aneurysm. This, in conjunction with the characteristic pathology findings of **fibromuscular webs** alternating with **aneurysmal dilation** and loss of the internal elastic lamina, is consistent with **fibromuscular dysplasia** (FMD). FMD is a nonatherosclerotic disease characterized by abnormal tissue growth within arterial walls, leading to arterial stenosis, tortuosity, aneurysms, or dissections. FMD typically occurs in women age <55. Angiography (ie, percutaneous, CT, MRI) is diagnostic and typically demonstrates a **string-of-beads** appearance in multifocal disease.

FMD can involve any artery but most commonly the renal, cerebral (eg, carotid, vertebral), and visceral arteries. Up to 80% of patients develop **renal artery stenosis**, which limits renal perfusion and leads to activation of the renin-angiotensin-aldosterone system. The resultant **hypertension** is often the earliest sign of the disease. Other presentations are related to locations of the dysplastic artery; **cerebrovascular involvement** (ie, headache, stroke, aneurysm rupture), mesenteric ischemia, or extremity claudication may be seen.

(Choices A and B) Adrenal tumors that can present with severe hypertension include pheochromocytoma and aldosterone- or cortisol-secreting adrenocortical adenomas. Coarctation of the aorta also causes hypertension, with blood pressure higher in the upper versus lower extremities. Due to the elevated blood pressure, these diseases can cause headaches and intraparenchymal hemorrhage in predisposed individuals, but they are not associated with fibrotic webbing or aneurysm formation.

(Choice C) Hypertrophic cardiomyopathy may present with sudden death in young patients due to left ventricular outflow obstruction; histology demonstrates hypertrophied myocytes and interstitial fibrosis. However, hypertrophic cardiomyopathy is not associated with aneurysm formation.

(Choice E) Thyroid follicular hyperplasia can cause hyperthyroidism (eg, Graves disease, thyroid adenoma). This commonly causes tachycardia, tremor, and palpitations but would not cause aneurysm formation.

Educational objective:
Fibromuscular dysplasia is characterized by abnormal tissue growth within arterial walls, resulting in stenotic and tortuous arteries that can cause tissue ischemia and are prone to aneurysm formation. Pathology typically demonstrates alternating fibromuscular webs and aneurysmal dilation with absent internal elastic lamina (string-of-beads appearance). Renovascular hypertension occurs due to renal artery stenosis and activation of the renin-angiotensin-aldosterone system.

Pathology	Renal, Urinary Systems & Electrolytes	Renal artery stenosis
Subject	System	Topic

walls, leading to arterial stenosis, tortuosity, aneurysms, or dissections. FMD typically occurs in women age <55. Angiography (ie, percutaneous, CT, MRI) is diagnostic and typically demonstrates a **string-of-beads** appearance in multifocal disease.

FMD can involve any artery but most commonly the renal, cerebral (eg, carotid, vertebral), and visceral arteries. Up to 80% of patients develop **renal artery stenosis**, which limits renal perfusion and leads to activation of the renin-angiotensin-aldosterone system. The resultant **hypertension** is often the earliest sign of the disease. Other presentations are related to locations of the dysplastic artery; **cerebrovascular involvement** (ie, headache, stroke, aneurysm rupture), mesenteric ischemia, or extremity claudication may be seen.

(Choices A and B) Adrenal tumors that can present with severe hypertension include pheochromocytoma and aldosterone- or cortisol-secreting adrenocortical adenomas. Coarctation of the aorta also causes hypertension, with blood pressure higher in the upper versus lower extremities. Due to the elevated blood pressure, these diseases can cause headaches and intraparenchymal hemorrhage in predisposed individuals, but they are not associated with fibrotic webbing or aneurysm formation.

(Choice C) Hypertrophic cardiomyopathy may present with sudden death in young patients due to left ventricular outflow obstruction; histology demonstrates hypertrophied myocytes and interstitial fibrosis. However, hypertrophic cardiomyopathy is not associated with aneurysm formation.

(Choice E) Thyroid follicular hyperplasia can cause hyperthyroidism (eg, Graves disease, thyroid adenoma). This commonly causes tachycardia, tremor, and palpitations but would not cause aneurysm formation.

Educational objective:
Fibromuscular dysplasia is characterized by abnormal tissue growth within arterial walls, resulting in stenotic and tortuous arteries that can cause tissue ischemia and are prone to aneurysm formation. Pathology typically demonstrates alternating fibromuscular webs and aneurysmal dilation with absent internal elastic lamina (string-of-beads appearance). Renovascular hypertension occurs due to renal artery stenosis and activation of the renin-angiotensin-aldosterone system.

Pathology	Renal, Urinary Systems & Electrolytes	Renal artery stenosis
Subject	System	Topic

Copyright © UWorld. All rights reserved.

A 54-year-old woman is brought to the hospital due to fever, nausea, vomiting, and confusion. For the past 3 days, she has had dysuria and increased frequency of urination. Medical history is significant for recurrent urinary tract infections and primary (essential) hypertension. Family history is insignificant. Temperature is 39.2 C (102.6 F), blood pressure is 90/50 mm Hg, pulse is 102/min, and respirations are 24/min. Examination shows right flank tenderness. The patient subsequently undergoes nephrectomy, and the specimen is shown in the image below.

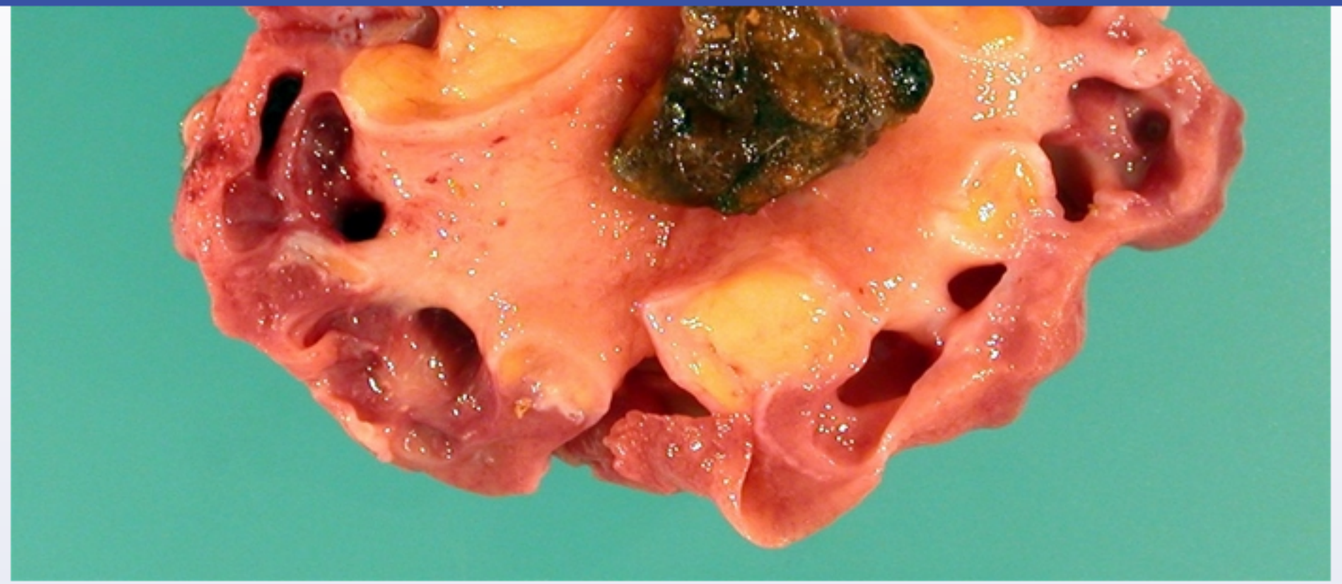

Further evaluation of this patient would most likely reveal which of the following?

- A. *Escherichia coli* infection
- B. High urinary cystine excretion
- C. *Klebsiella* infection
- D. Parathyroid tumor
- E. Persistently low urine pH

Submit

1 2 3 4 5 6 7 8 9 10 11 12 13 14 15 16 17 18 19 20 21 22 23 24 25 26 27 28 29 30

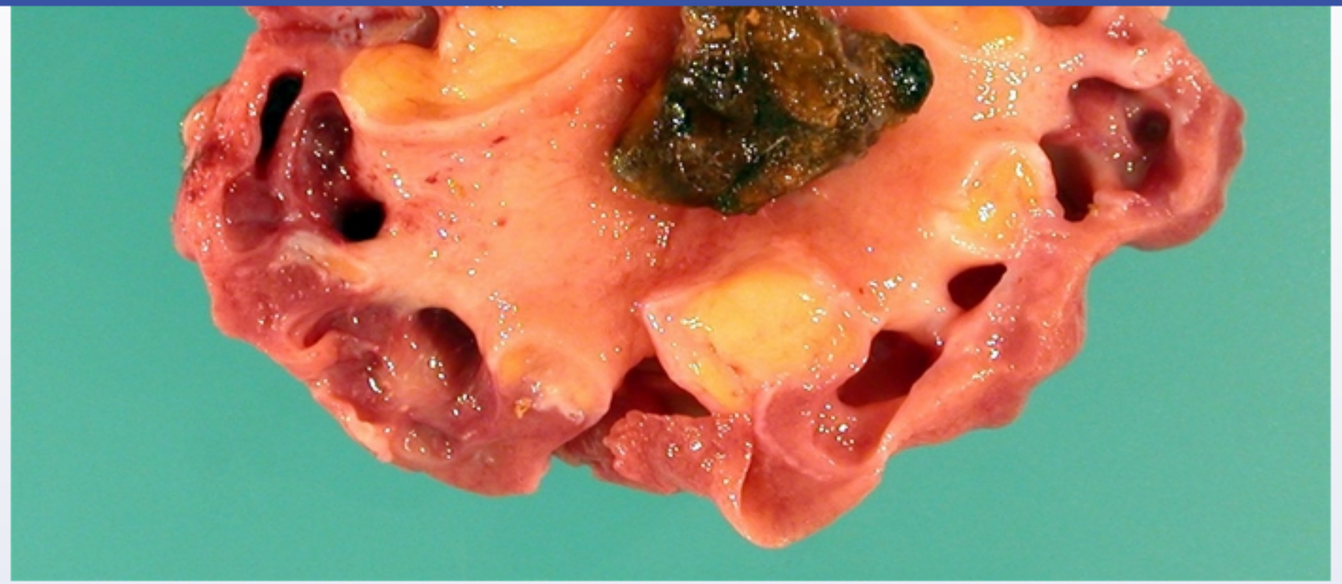

Further evaluation of this patient would most likely reveal which of the following?

A. *Escherichia coli* infection (17%)

B. High urinary cystine excretion (12%)

C. *Klebsiella* infection (48%) ✓

D. Parathyroid tumor (4%)

E. Persistently low urine pH (16%)

Omitted
Correct answer

48%
Answered correctly

04 secs
Time Spent

03/22/2020
Last Updated

Explanation

Struvite (magnesium ammonium phosphate) stones	
Risk factors	• Recurrent upper urinary tract infection • Urease-producing organisms (eg, *Klebsiella*, *Proteus*)
Pathogenesis	• Hydrolysis of urea to yield ammonia: Urea $\rightarrow 2\ NH_3 + CO_2$ $NH_3 + H_2O \rightarrow NH_4^+ + OH^-$ • Increased urine pH • Precipitation of magnesium ammonium phosphate salts
Clinical features	• Large staghorn calculi • Fever, mild flank pain due to infection • Obstruction of collecting system & atrophy of renal parenchyma

This patient has a large staghorn calculus in the renal pelvis associated with dilation of the collecting system, atrophy of the renal cortex, and xanthomatous changes (yellowish discoloration) in the renal parenchyma. **Staghorn calculi** are composed primarily of **struvite** (magnesium ammonium phosphate) and calcium salts (carbonate, oxalate, or phosphate). They are typically seen in patients with recurrent upper urinary infection caused by **urease-producing organisms** (eg, *Proteus*, *Klebsiella*); hydrolysis of urea yields **ammonia**, which **alkalinizes the urine** (pH usually >7) and facilitates precipitation of magnesium ammonium phosphate crystals **(Choice E)**.

Because of the large quantities of urea excreted in urine, these stones can grow very rapidly and fill the renal calyces, causing obstruction of renal outflow. The kidneys are often **atrophic** due to recurrent infection and/or chronic obstructive nephropathy. The large size of staghorn calculi prevents them from passing into the ureter, so symptoms are typically related to the associated infection (eg, fever, mild costovertebral pain, hematuria) rather than acute renal colic.

(Choice A) *Escherichia coli* is the most common cause of uncomplicated urinary tract infections but only rarely produces urease. It is not commonly associated with the formation of staghorn calculi.

	• Obstruction of collecting system & atrophy of renal parenchyma

This patient has a large staghorn calculus in the renal pelvis associated with dilation of the collecting system, atrophy of the renal cortex, and xanthomatous changes (yellowish discoloration) in the renal parenchyma. **Staghorn calculi** are composed primarily of **struvite** (magnesium ammonium phosphate) and calcium salts (carbonate, oxalate, or phosphate). They are typically seen in patients with recurrent upper urinary infection caused by **urease-producing organisms** (eg, *Proteus*, *Klebsiella*); hydrolysis of urea yields **ammonia**, which **alkalinizes the urine** (pH usually >7) and facilitates precipitation of magnesium ammonium phosphate crystals **(Choice E)**.

Because of the large quantities of urea excreted in urine, these stones can grow very rapidly and fill the renal calyces, causing obstruction of renal outflow. The kidneys are often **atrophic** due to recurrent infection and/or chronic obstructive nephropathy. The large size of staghorn calculi prevents them from passing into the ureter, so symptoms are typically related to the associated infection (eg, fever, mild costovertebral pain, hematuria) rather than acute renal colic.

(Choice A) *Escherichia coli* is the most common cause of uncomplicated urinary tract infections but only rarely produces urease. It is not commonly associated with the formation of staghorn calculi.

(Choice B) Cystine stones are uncommon, yellow-brown calculi that precipitate in acidic urine. They usually develop in patients who have cystinuria secondary to genetic defects in the renal reabsorption of cystine and other amino acids.

(Choice D) Hyperparathyroidism due to a parathyroid adenoma can cause increased urinary excretion of calcium and lead to formation of calcium oxalate stones. These stones typically present with renal colic due to acute ureterolithiasis, and most patients do not have significant fever or a history of recurrent urinary tract infection.

Educational objective:
Staghorn calculi are large renal stones that take on the shape of the renal calyces. They are composed primarily of struvite (magnesium ammonium phosphate) and are associated with recurrent upper urinary tract infections by urease-producing organisms (eg, *Proteus*, *Klebsiella*). Hydrolysis of urea yields ammonia, which alkalinizes the urine and facilitates precipitation of struvite crystals.

References

- Renal struvite stones—pathogenesis, microbiology, and management strategies.

Settings

1 2 3 4 5 6 7 8 9 10 11 12 13 14 15 16 17 18 19 20 21 22 23 24 25 26 27 28 29 30

Item 19 of 40
Question Id: 6739

Mark | Previous | Next | Full Screen | Tutorial | Lab Values | Notes | Calculator | Reverse Color | Text Zoom | Settings

- Obstruction of collecting system & atrophy of renal parenchyma

Exhibit Display

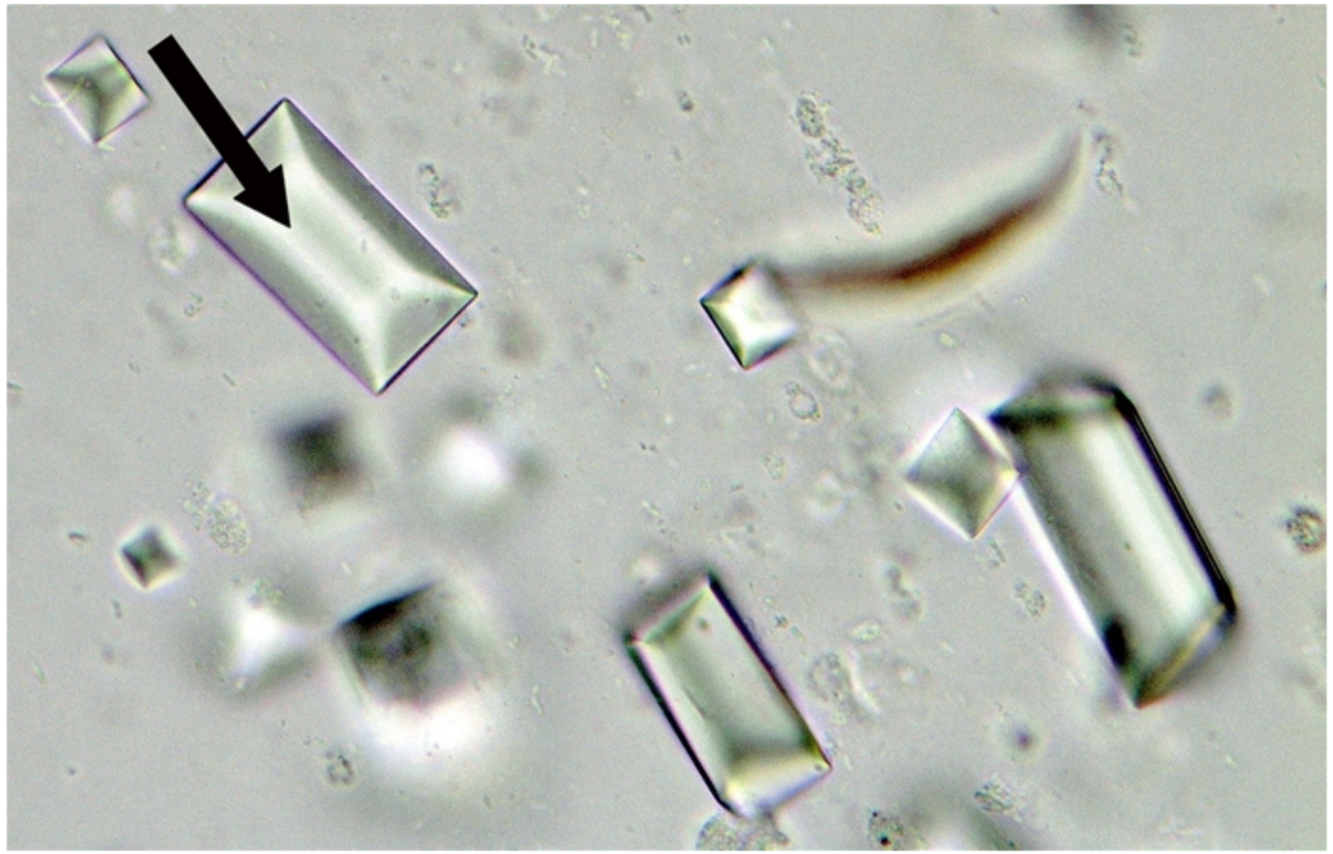

Zoom In | Zoom Out | Reset | Add To New Card | Existing Card

Block Time Remaining: 00:05:03
TUTOR

5 | Feedback | Suspend | End Block

infection caused by **urease-producing organisms** (eg, *Proteus*, *Klebsiella*); hydrolysis of urea yields **ammonia**, which **alkalinizes the urine** (pH usually >7) and facilitates precipitation of magnesium ammonium phosphate crystals **(Choice E)**.

Because of the large quantities of urea excreted in urine, these stones can grow very rapidly and fill the renal calyces, causing obstruction of renal outflow. The kidneys are often **atrophic** due to recurrent infection and/or chronic obstructive nephropathy. The large size of staghorn calculi prevents them from passing into the ureter, so symptoms are typically related to the associated infection (eg, fever, mild costovertebral pain, hematuria) rather than acute renal colic.

(Choice A) *Escherichia coli* is the most common cause of uncomplicated urinary tract infections but only rarely produces urease. It is not commonly associated with the formation of staghorn calculi.

(Choice B) Cystine stones are uncommon, yellow-brown calculi that precipitate in acidic urine. They usually develop in patients who have cystinuria secondary to genetic defects in the renal reabsorption of cystine and other amino acids.

(Choice D) Hyperparathyroidism due to a parathyroid adenoma can cause increased urinary excretion of calcium and lead to formation of calcium oxalate stones. These stones typically present with renal colic due to acute ureterolithiasis, and most patients do not have significant fever or a history of recurrent urinary tract infection.

Educational objective:
Staghorn calculi are large renal stones that take on the shape of the renal calyces. They are composed primarily of struvite (magnesium ammonium phosphate) and are associated with recurrent upper urinary tract infections by urease-producing organisms (eg, *Proteus*, *Klebsiella*). Hydrolysis of urea yields ammonia, which alkalinizes the urine and facilitates precipitation of struvite crystals.

References

- Renal struvite stones—pathogenesis, microbiology, and management strategies.

Pathology	Renal, Urinary Systems & Electrolytes	Renal calculi
Subject	System	Topic

Copyright © UWorld. All rights reserved.

A 4-year-old girl developed acute-onset colicky abdominal pain, vomiting, and loose bloody stools during a family vacation. She was treated with supportive care and began to feel better. A few days later, her parents bring her to the emergency department because she has urinated only once in the past 10 hours and the urine was red. Physical examination shows conjunctival pallor but is otherwise normal. Laboratory studies are as follows:

Hemoglobin	7.8 g/dL
Platelets	80,000/mm^3
Creatinine	1.7 mg/dL

Urinalysis shows proteinuria and hematuria. Which of the following mechanisms is the most likely cause of this patient's condition?

A. Microthrombi in small blood vessels

B. Streptococcal antigen-associated glomerular damage

C. Systemic IgA-mediated vasculitis

D. Vasculitis involving medium arteries

E. Widespread activation of the coagulation cascade

Submit

1 2 3 4 5 6 7 8 9 10 11 12 13 14 15 16 17 18 19 20 21 22 23 24 25 26 27 28 29 30

A 4-year-old girl developed acute-onset colicky abdominal pain, vomiting, and loose bloody stools during a family vacation. She was treated with supportive care and began to feel better. A few days later, her parents bring her to the emergency department because she has urinated only once in the past 10 hours and the urine was red. Physical examination shows conjunctival pallor but is otherwise normal. Laboratory studies are as follows:

Hemoglobin	7.8 g/dL
Platelets	80,000/mm^3
Creatinine	1.7 mg/dL

Urinalysis shows proteinuria and hematuria. Which of the following mechanisms is the most likely cause of this patient's condition?

A. Microthrombi in small blood vessels (48%)
B. Streptococcal antigen-associated glomerular damage (11%)
C. Systemic IgA-mediated vasculitis (27%)
D. Vasculitis involving medium arteries (3%)
E. Widespread activation of the coagulation cascade (9%)

Omitted
Correct answer
A

48%
Answered correctly

01 sec
Time Spent

02/01/2020
Last Updated

Explanation

Hemolytic uremic syndrome	
Etiology	Shiga toxin-producing bacteria • *Escherichia coli* O157:H7 • *Shigella*
Clinical features	• Antecedent diarrheal illness (often bloody) • Hemolytic anemia with schistocytes • Thrombocytopenia • Acute kidney injury

©UWorld

This patient has diarrhea-associated **hemolytic uremic syndrome (HUS)**, a major cause of acute renal failure in young children. Most cases are due to intestinal infection by **Shiga toxin (verotoxin)-producing organisms** (eg, *Escherichia coli* O157:H7, *Shigella dysenteriae*). These toxins injure the endothelium of preglomerular arterioles and glomerular capillaries, leading to platelet activation and aggregation and the formation of microthrombi. Platelet consumption causes **thrombocytopenia** (platelets <140,000/mm^3), but there is typically no purpura or active bleeding. Erythrocytes passing through the damaged capillaries suffer shear injury and are broken down to schistocytes, causing **microangiopathic hemolytic anemia** (conjunctival pallor). Extensive damage to the renal vasculature results in **acute kidney injury** (oliguria/anuria, hematuria, increased creatinine).

(Choice B) Poststreptococcal glomerulonephritis develops approximately 1-3 weeks following a cutaneous or pharyngeal infection by a nephritogenic strain of group A β-hemolytic streptococci. It is caused by an immune response against streptococcal antigens that deposit in the glomerulus. Patients have oliguria, hematuria, proteinuria, edema, and hypertension. Anemia is not commonly seen.

(Choice C) Henoch-Schönlein purpura (HSP) is a systemic leukocytoclastic vasculitis caused by IgA immune complex deposition within small blood vessels of the skin, kidneys, intestines, and joints. Symptoms include palpable purpura, abdominal pain, arthralgias, and acute glomerulonephritis. Platelet count and coagulation studies are normal in HSP. In addition, the absence of palpable purpura and joint symptoms

©UWorld

This patient has diarrhea-associated **hemolytic uremic syndrome (HUS)**, a major cause of acute renal failure in young children. Most cases are due to intestinal infection by **Shiga toxin (verotoxin)-producing organisms** (eg, *Escherichia coli* O157:H7, *Shigella dysenteriae*). These toxins injure the endothelium of preglomerular arterioles and glomerular capillaries, leading to platelet activation and aggregation and the formation of microthrombi. Platelet consumption causes **thrombocytopenia** (platelets <140,000/mm^3), but there is typically no purpura or active bleeding. Erythrocytes passing through the damaged capillaries suffer shear injury and are broken down to schistocytes, causing **microangiopathic hemolytic anemia** (conjunctival pallor). Extensive damage to the renal vasculature results in **acute kidney injury** (oliguria/anuria, hematuria, increased creatinine).

(Choice B) Poststreptococcal glomerulonephritis develops approximately 1-3 weeks following a cutaneous or pharyngeal infection by a nephritogenic strain of group A β-hemolytic streptococci. It is caused by an immune response against streptococcal antigens that deposit in the glomerulus. Patients have oliguria, hematuria, proteinuria, edema, and hypertension. Anemia is not commonly seen.

(Choice C) Henoch-Schönlein purpura (HSP) is a systemic leukocytoclastic vasculitis caused by IgA immune complex deposition within small blood vessels of the skin, kidneys, intestines, and joints. Symptoms include palpable purpura, abdominal pain, arthralgias, and acute glomerulonephritis. Platelet count and coagulation studies are normal in HSP. In addition, the absence of palpable purpura and joint symptoms makes HSP an unlikely diagnosis in this patient.

(Choice D) Kawasaki disease (mucocutaneous lymph node syndrome) is a vasculitis of medium arteries that classically affects young children. The main symptoms are high fever, conjunctivitis, cervical lymphadenopathy, periungual desquamation, and mucocutaneous changes (eg, strawberry tongue).

(Choice E) Disseminated intravascular coagulation refers to massive, widespread activation of the coagulation cascade due to release of procoagulant substances caused by sepsis, malignancy, or trauma. These patients usually have bleeding, petechiae, and bruising due to concomitant fibrinolysis and consumption of platelets and coagulation factors.

Educational objective:
Hemolytic uremic syndrome is a common cause of acute renal failure in children. It is characterized by the triad of microangiopathic hemolytic anemia, thrombocytopenia, and acute kidney injury. Most cases develop following a diarrheal illness caused by Shiga toxin-producing organisms (eg, *Escherichia coli* O157:H7, *Shigella dysenteriae*).

increased creatinine).

(Choice B) Poststreptococcal glomerulonephritis develops approximately 1-3 weeks following a cutaneous or pharyngeal infection by a nephritogenic strain of group A β-hemolytic streptococci. It is caused by an immune response against streptococcal antigens that deposit in the glomerulus. Patients have oliguria, hematuria, proteinuria, edema, and hypertension. Anemia is not commonly seen.

(Choice C) Henoch-Schönlein purpura (HSP) is a systemic leukocytoclastic vasculitis caused by IgA immune complex deposition within small blood vessels of the skin, kidneys, intestines, and joints. Symptoms include palpable purpura, abdominal pain, arthralgias, and acute glomerulonephritis. Platelet count and coagulation studies are normal in HSP. In addition, the absence of palpable purpura and joint symptoms makes HSP an unlikely diagnosis in this patient.

(Choice D) Kawasaki disease (mucocutaneous lymph node syndrome) is a vasculitis of medium arteries that classically affects young children. The main symptoms are high fever, conjunctivitis, cervical lymphadenopathy, periungual desquamation, and mucocutaneous changes (eg, strawberry tongue).

(Choice E) Disseminated intravascular coagulation refers to massive, widespread activation of the coagulation cascade due to release of procoagulant substances caused by sepsis, malignancy, or trauma. These patients usually have bleeding, petechiae, and bruising due to concomitant fibrinolysis and consumption of platelets and coagulation factors.

Educational objective:
Hemolytic uremic syndrome is a common cause of acute renal failure in children. It is characterized by the triad of microangiopathic hemolytic anemia, thrombocytopenia, and acute kidney injury. Most cases develop following a diarrheal illness caused by Shiga toxin-producing organisms (eg, *Escherichia coli* O157:H7, *Shigella dysenteriae*).

References

- Shiga toxins and the pathophysiology of hemolytic uremic syndrome in humans and animals.
- HUS and TTP in children.

Pathology	Renal, Urinary Systems & Electrolytes	Hemolytic uremic syndrome
Subject	System	Topic

Settings

1
2
3
4
5
6
7
8
9
10
11
12
13
14
15
16
17
18
19
20
21
22
23
24
25
26
27
28
29
30

Item 20 of 40
Question Id: 1849

Mark | Previous | Next | Full Screen | Tutorial | Lab Values | Notes | Calculator | Reverse Color | Text Zoom | Settings

increased creatinine).

Exhibit Display

Zoom In | Zoom Out | Reset | Add To New Card | Existing Card

Subject System Topic

Block Time Remaining: 00:05:04
TUTOR

5 | Feedback | Suspend | End Block

increased creatinine).

Exhibit Display

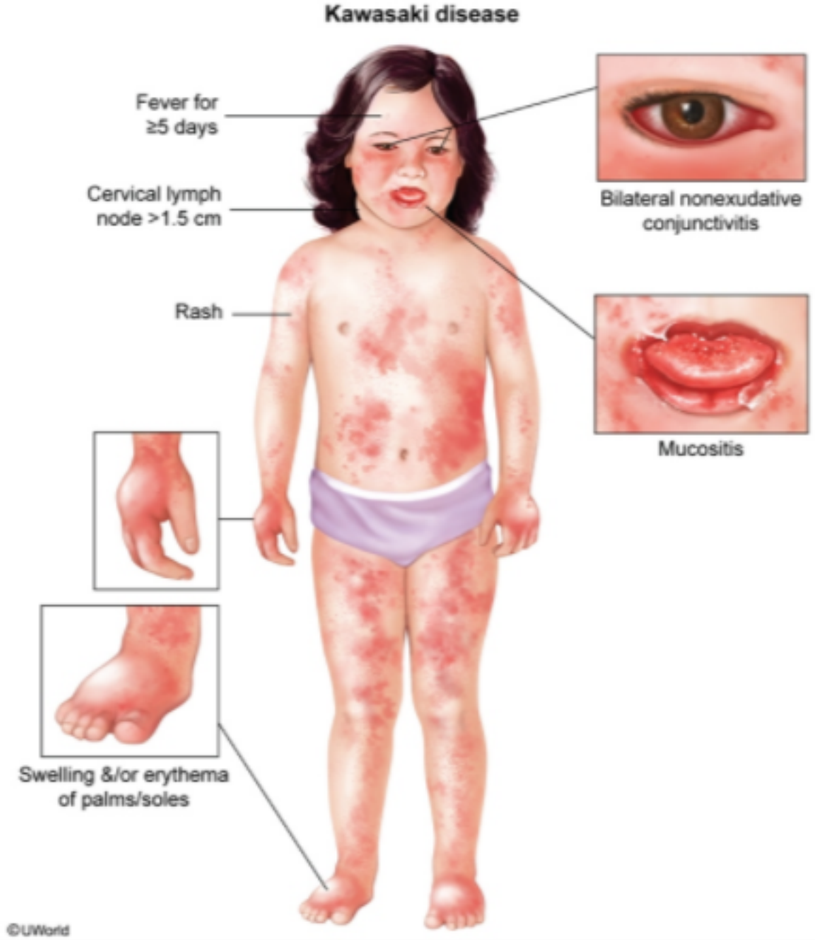

Zoom In | Zoom Out | Reset | Add To New Card | Existing Card

Subject System Topic

A 7-year-old boy is brought to the office due to swelling of the hands and feet. Two weeks ago, the patient was treated for anaphylaxis following a bee sting. During the past 10 days, he has had progressive hand and foot swelling, and his pants feel tighter than usual. The patient's urine has also become frothy. Examination shows periorbital edema and pitting edema of the hands and feet, as well as mild ascites. Lungs are clear to auscultation. Urinalysis results are as follows:

Protein	+4
Blood	negative
Glucose	negative
Ketones	negative
White blood cells	1-2/hpf
Red blood cells	1-2/hpf
Casts	hyaline casts

Renal biopsy of this patient would most likely show which of the following microscopy findings?

	Light microscopy	Immunofluorescence	Electron microscopy
A.	Cellular proliferation in segmental areas	Globular deposits of IgA	Mesangial deposits
B.	Cellular proliferation with increased neutrophils in capillaries	Granular deposits of complement and IgG	Subepithelial deposits
C.	Crescent formation	Linear deposits of IgG	Negative for deposits
D.	Diffuse thickening of	Granular deposits of	Subepithelial deposits

Ketones	negative
White blood cells	1-2/hpf
Red blood cells	1-2/hpf
Casts	hyaline casts

Renal biopsy of this patient would most likely show which of the following microscopy findings?

	Light microscopy	Immunofluorescence	Electron microscopy
A.	Cellular proliferation in segmental areas	Globular deposits of IgA	Mesangial deposits
B.	Cellular proliferation with increased neutrophils in capillaries	Granular deposits of complement and IgG	Subepithelial deposits
C.	Crescent formation	Linear deposits of IgG	Negative for deposits
D.	Diffuse thickening of glomerular basement membrane	Granular deposits of complement and IgG	Subepithelial deposits
E.	Normal histology	Negative for complement and IgG	Effacement of podocytes

Submit

Ketones	negative
White blood cells	1-2/hpf
Red blood cells	1-2/hpf
Casts	hyaline casts

Renal biopsy of this patient would most likely show which of the following microscopy findings?

	Light microscopy	Immunofluorescence	Electron microscopy
A.	Cellular proliferation in segmental areas (5%)	Globular deposits of IgA	Mesangial deposits
B.	Cellular proliferation with increased neutrophils in capillaries (6%)	Granular deposits of complement and IgG	Subepithelial deposits
C.	Crescent formation (2%)	Linear deposits of IgG	Negative for deposits
D.	Diffuse thickening of glomerular basement membrane (7%)	Granular deposits of complement and IgG	Subepithelial deposits
✓ E.	Normal histology (78%)	Negative for complement and IgG	Effacement of podocytes

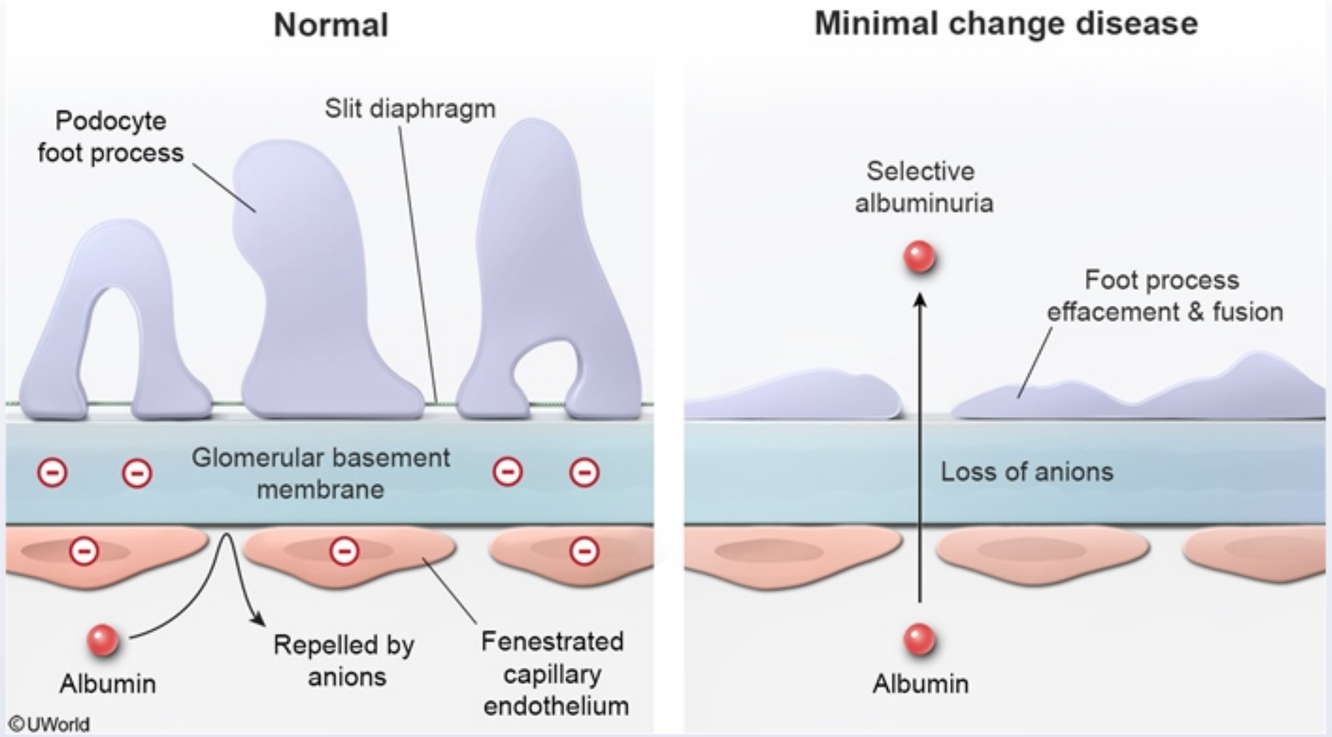

This pediatric patient developed **nephrotic syndrome** (ie, generalized edema, hyperlipidemia, hypoalbuminemia, massive proteinuria with resultant "frothy" urine) after a bee sting. This presentation suggests **minimal change disease** (MCD), the most common cause of nephrotic syndrome in **young children**. MCD is often idiopathic but can occur after an inciting event, including respiratory infections, immunizations, or insect sting/bite (as in this patient). Subsequent T-cell dysfunction leads to the production of a glomerular permeability factor, possibly IL-13, which damages podocytes and decreases the anionic properties of the glomerular basement membrane (GBM). Loss of negative charge results in the selective loss of albumin in the urine, which causes hypoalbuminemia and edema.

Most children with MCD can be diagnosed presumptively based on clinical presentation, and renal biopsy is usually unnecessary. If biopsy is performed, light microscopy (LM) shows **normal glomeruli**, and **no immunoglobulin** or complement deposits are seen with immunofluorescent staining. However, electron microscopy (EM) shows diffuse **podocyte foot process effacement** and fusion. These abnormal findings are

This pediatric patient developed **nephrotic syndrome** (ie, generalized edema, hyperlipidemia, hypoalbuminemia, massive proteinuria with resultant "frothy" urine) after a bee sting. This presentation suggests **minimal change disease** (MCD), the most common cause of nephrotic syndrome in **young children**. MCD is often idiopathic but can occur after an inciting event, including respiratory infections, immunizations, or insect sting/bite (as in this patient). Subsequent T-cell dysfunction leads to the production of a glomerular permeability factor, possibly IL-13, which damages podocytes and decreases the anionic properties of the glomerular basement membrane (GBM). Loss of negative charge results in the selective loss of albumin in the urine, which causes hypoalbuminemia and edema.

Most children with MCD can be diagnosed presumptively based on clinical presentation, and renal biopsy is usually unnecessary. If biopsy is performed, light microscopy (LM) shows **normal glomeruli**, and **no immunoglobulin** or complement deposits are seen with immunofluorescent staining. However, electron microscopy (EM) shows diffuse **podocyte foot process effacement** and fusion. These abnormal findings are generally reversible after corticosteroid therapy, and most children experience rapid resolution with an excellent long-term prognosis.

(Choice A) IgA nephropathy presents with nephritic syndrome; patients typically develop marked hematuria with red blood cell casts on urinalysis. Deposits of IgA are noted in the mesangium on EM and immunofluorescence microscopy (IF), whereas LM demonstrates resultant glomerular hypercellularity in affected segments.

(Choice B) Poststreptococcal glomerulonephritis is a nephritic syndrome that typically occurs 2-4 weeks after infection with group A Streptococcus. LM demonstrates hypercellular glomeruli, whereas IF shows a "lumpy-bumpy" pattern of granular IgG and C3 deposition on the GBM. EM also demonstrates subepithelial immune complex deposits.

(Choice C) Antiglomerular basement membrane disease causes a linear deposition of IgG and C3 on the GBM; it typically results in a crescentic glomerulonephritis (eg, nephritic syndrome; hematuria, red blood cell casts) visible on LM. EM demonstrates breakage of the GBM, but immune complex deposits are absent.

(Choice D) Membranous nephropathy causes a nephrotic syndrome but is rarer in children; it is often associated with viral hepatitis, solid tumors, or lupus. LM reveals diffuse GBM thickening on IM, which is due to the granular deposition of immune complexes (IgG and C3); EM demonstrates subepithelial deposits.

Educational objective:
Minimal change disease is the most common cause of nephrotic syndrome in children. Classic manifestations include proteinuria,

performed, light microscopy (LM) shows **normal glomeruli**, and **no immunoglobulin** or complement deposits are seen with immunofluorescent staining. However, electron microscopy (EM) shows diffuse **podocyte foot process effacement** and fusion. These abnormal findings are generally reversible after corticosteroid therapy, and most children experience rapid resolution with an excellent long-term prognosis.

(Choice A) IgA nephropathy presents with nephritic syndrome; patients typically develop marked hematuria with red blood cell casts on urinalysis. Deposits of IgA are noted in the mesangium on EM and immunofluorescence microscopy (IF), whereas LM demonstrates resultant glomerular hypercellularity in affected segments.

(Choice B) Poststreptococcal glomerulonephritis is a nephritic syndrome that typically occurs 2-4 weeks after infection with group A Streptococcus. LM demonstrates hypercellular glomeruli, whereas IF shows a "lumpy-bumpy" pattern of granular IgG and C3 deposition on the GBM. EM also demonstrates subepithelial immune complex deposits.

(Choice C) Antiglomerular basement membrane disease causes a linear deposition of IgG and C3 on the GBM; it typically results in a crescentic glomerulonephritis (eg, nephritic syndrome; hematuria, red blood cell casts) visible on LM. EM demonstrates breakage of the GBM, but immune complex deposits are absent.

(Choice D) Membranous nephropathy causes a nephrotic syndrome but is rarer in children; it is often associated with viral hepatitis, solid tumors, or lupus. LM reveals diffuse GBM thickening on IM, which is due to the granular deposition of immune complexes (IgG and C3); EM demonstrates subepithelial deposits.

Educational objective:
Minimal change disease is the most common cause of nephrotic syndrome in children. Classic manifestations include proteinuria, hypoalbuminemia, and edema that are usually reversible with corticosteroids. The principal lesion is a diffuse foot process effacement that can be seen on electron microscopy. Light and immunofluorescence microscopy are normal.

Pathology	Renal, Urinary Systems & Electrolytes	Glomerular disorders
Subject	System	Topic

Copyright © UWorld. All rights reserved.

Settings

1 2 3 4 5 6 7 8 9 10 11 12 13 14 15 16 17 18 19 20 21 22 23 24 25 26 27 28 29 30

Item 21 of 40
Question Id: 384

Mark | Previous | Next | Full Screen | Tutorial | Lab Values | Notes | Calculator | Reverse Color | Text Zoom | Settings

performed, light microscopy (LM) shows **normal glomeruli**, and **no immunoglobulin** or complement deposits are seen with immunofluorescent

Exhibit Display

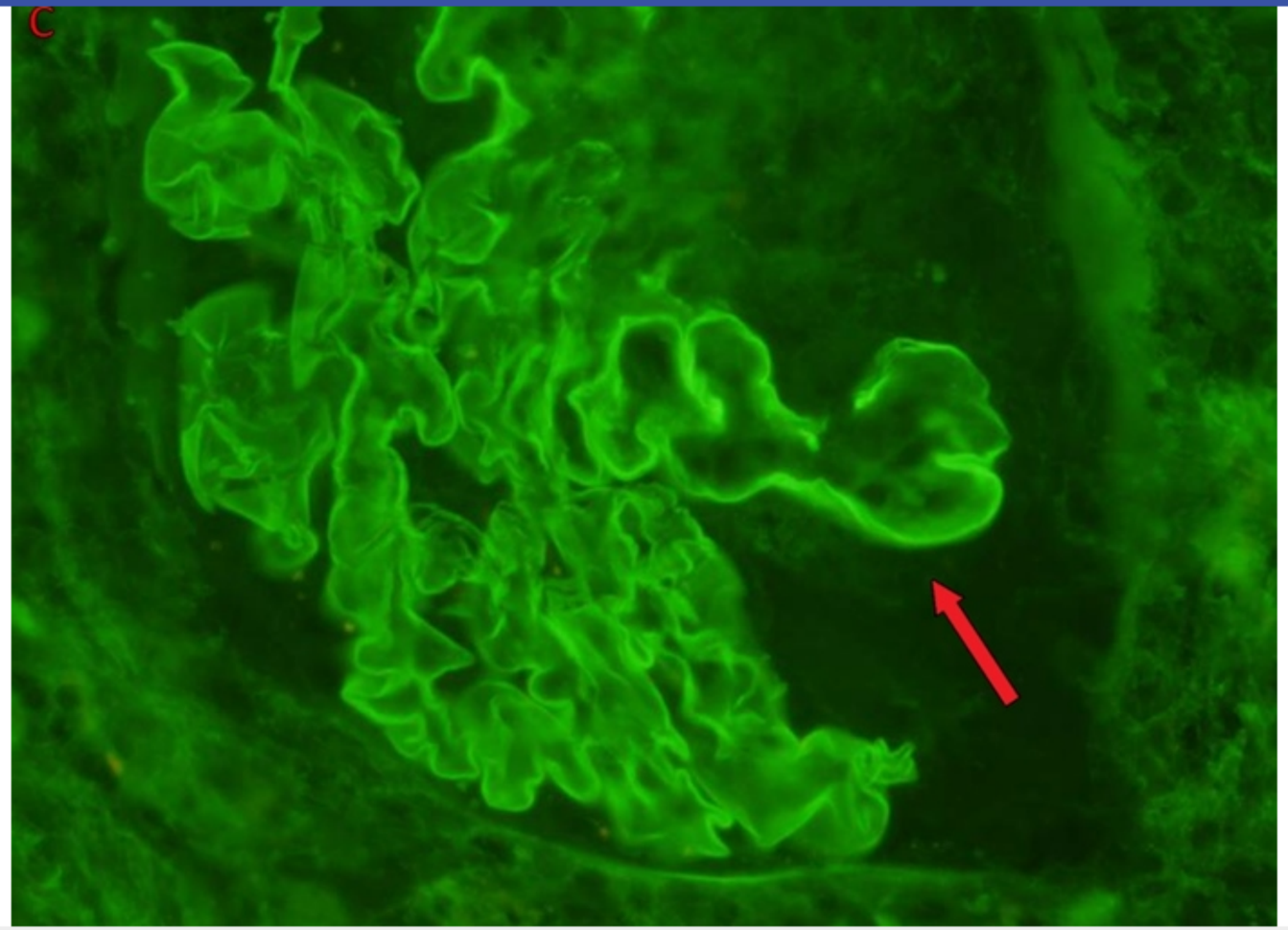

Zoom In | Zoom Out | Reset | Add To New Card | Existing Card

Block Time Remaining: 00:05:08
TUTOR

Feedback | Suspend | End Block

Settings

1
2
3
4
5
6
7
8
9
10
11
12
13
14
15
16
17
18
19
20
21
22
23
24
25
26
27
28
29
30

Item 21 of 40
Question Id: 384

Mark | Previous | Next | Full Screen | Tutorial | Lab Values | Notes | Calculator | Reverse Color | Text Zoom | Settings

performed, light microscopy (LM) shows **normal glomeruli**, and **no immunoglobulin** or complement deposits are seen with immunofluorescent

Exhibit Display

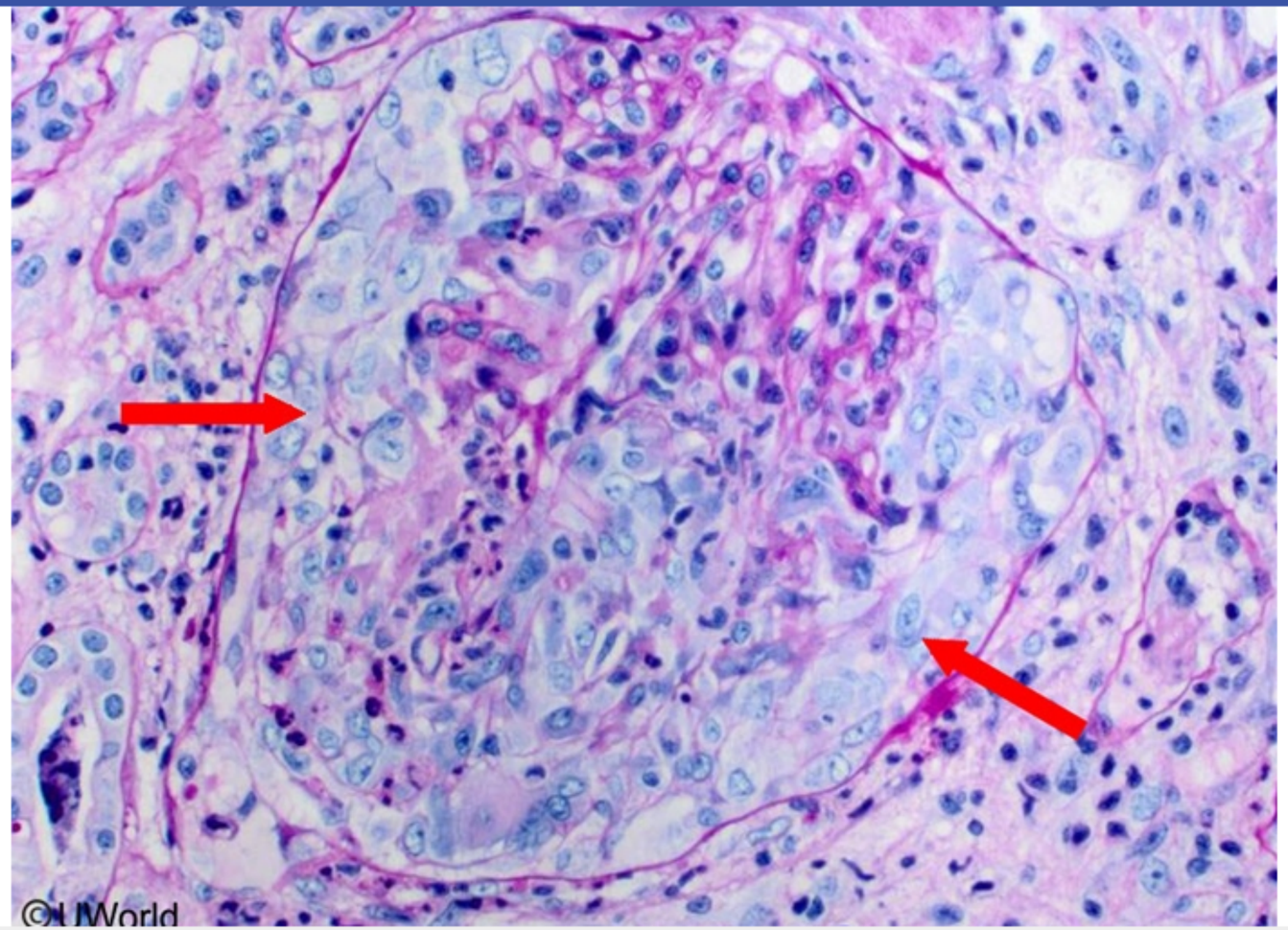

Zoom In | Zoom Out | Reset | Add To New Card | Existing Card

Block Time Remaining: 00:05:08
TUTOR

Feedback | Suspend | End Block

Settings

1
2
3
4
5
6
7
8
9
10
11
12
13
14
15
16
17
18
19
20
21
22
23
24
25
26
27
28
29
30

Item 21 of 40
Question Id: 384

Mark | Previous | Next | Full Screen | Tutorial | Lab Values | Notes | Calculator | Reverse Color | Text Zoom | Settings

performed, light microscopy (LM) shows **normal glomeruli**, and **no immunoglobulin** or complement deposits are seen with immunofluorescent

Exhibit Display

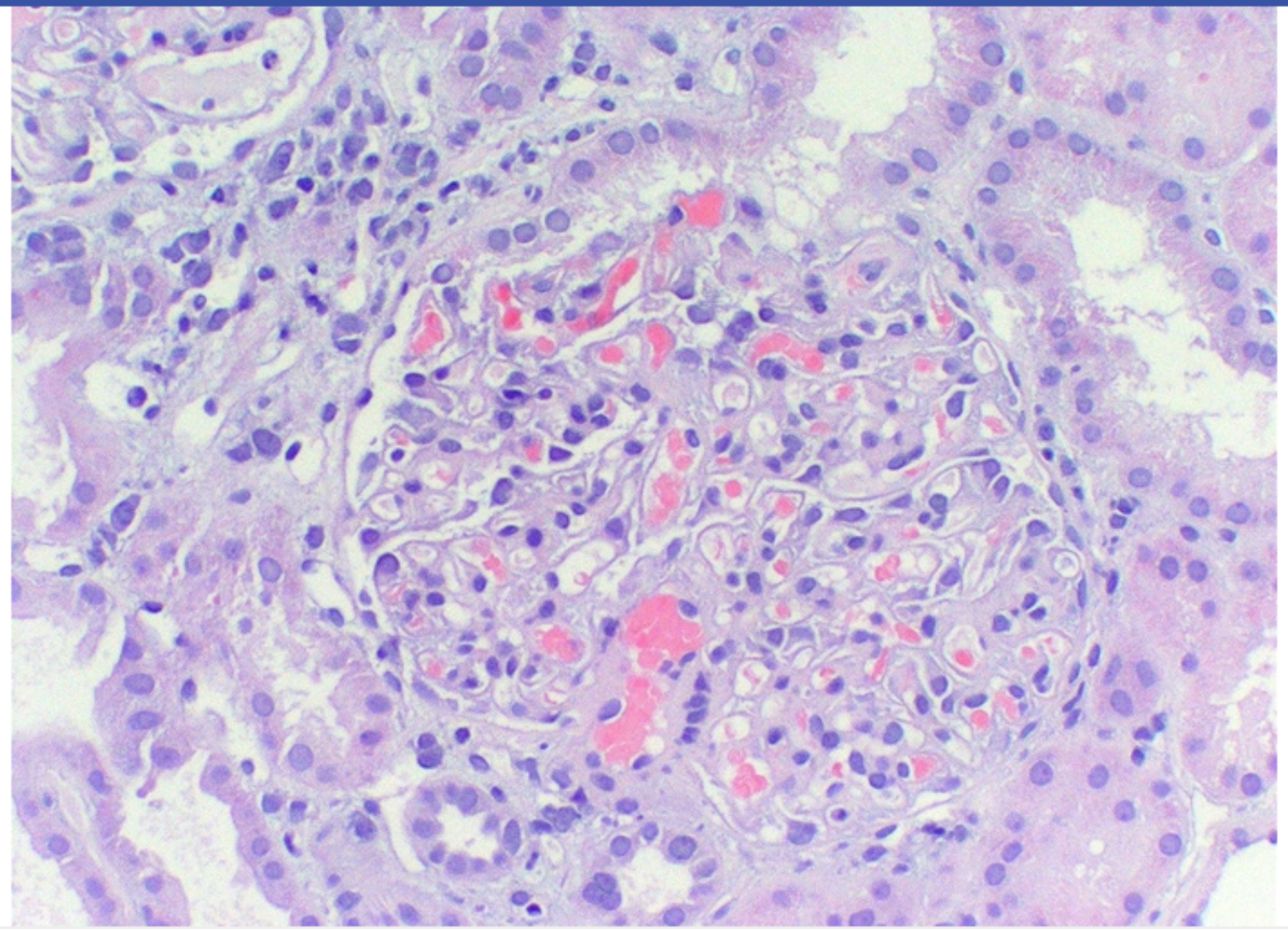

Zoom In | Zoom Out | Reset | Add To New Card | Existing Card

Block Time Remaining: 00:05:08
TUTOR

1 | Feedback | Suspend | End Block

1 2 3 4 5 6 7 8 9 10 11 12 13 14 15 16 17 18 19 20 21 22 23 24 25 26 27 28 29 30

performed, light microscopy (LM) shows **normal glomeruli**, and **no immunoglobulin** or complement deposits are seen with immunofluorescent

Exhibit Display

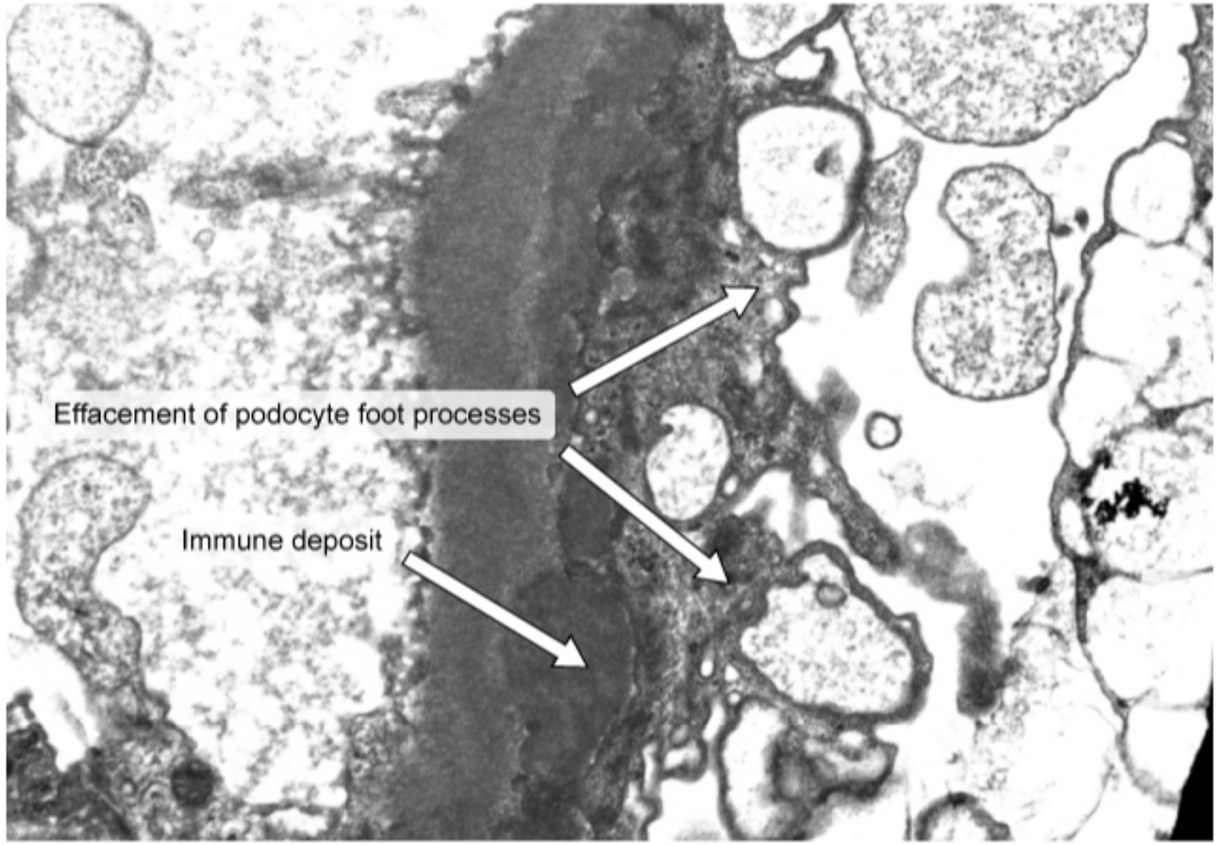

Zoom In | Zoom Out | Reset | Add To New Card | Existing Card

1 2 3 4 5 6 7 8 9 10 11 12 13 14 15 16 17 18 19 20 21 22 23 24 25 26 27 28 29 30

A 16-year-old boy is brought to the emergency department with sudden onset of left-sided abdominal pain and blood in his urine. The pain waxes and wanes in intensity and does not improve with rest or position changes. He has a lengthy history of similar pain episodes, but this is the first time he has had gross hematuria. Physical examination shows costovertebral angle tenderness on the left side. Microscopic examination of the urine is shown below.

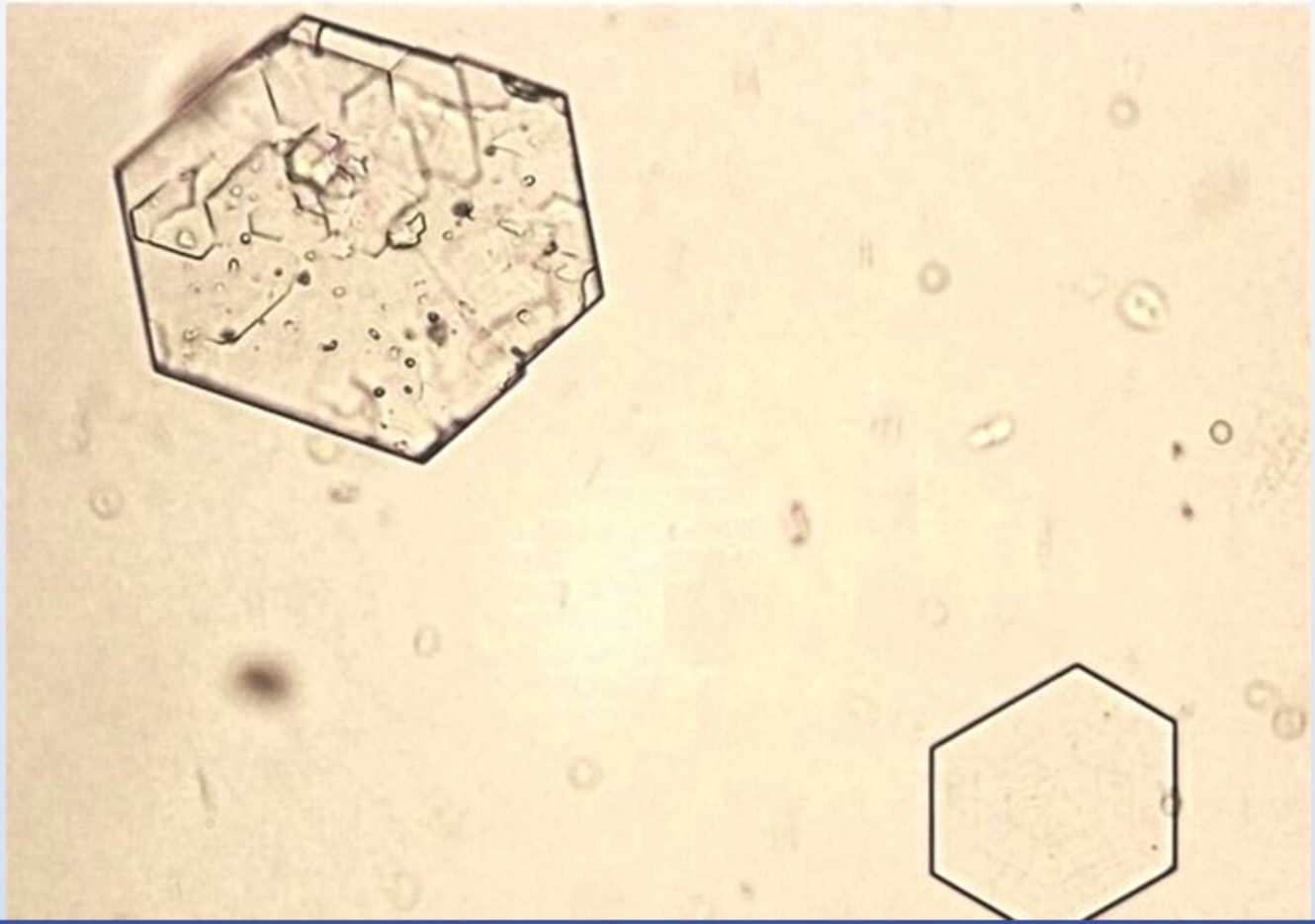

Further quantitative laboratory evaluation is most likely to detect which of the following abnormalities in this patient?

- A. Aminoaciduria
- B. Hypercalciuria
- C. Hyperoxaluria
- D. Hyperuricosuria
- E. Hypocitraturia

Submit

1 2 3 4 5 6 7 8 9 10 11 12 13 14 15 16 17 18 19 20 21 22 23 24 25 26 27 28 29 30

Further quantitative laboratory evaluation is most likely to detect which of the following abnormalities in this patient?

- ✓ A. Aminoaciduria (54%)
- B. Hypercalciuria (10%)
- C. Hyperoxaluria (13%)
- D. Hyperuricosuria (11%)
- E. Hypocitraturia (9%)

Omitted
Correct answer

54%
Answered correctly

05 secs
Time Spent

03/20/2020
Last Updated

Nephrolithiasis

Content	Frequency	Radiograph opacity	pH	Microscopic appearance
Calcium oxalate	70%-80%	↑↑	--	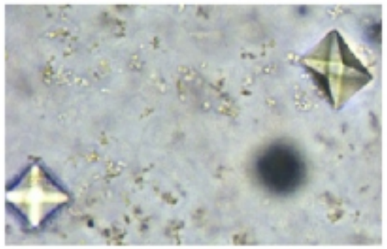 • Octahedron (square with an "X" in the center)
Calcium phosphate			>7.0	• Elongated, wedge-shaped • Forms rosettes
Magnesium ammonium phosphate (struvite or triple phosphate)	15%	↑	>7.0	 • Rectangular prism ("coffin lids")

phosphate			>7.0	• Forms rosettes
Magnesium ammonium phosphate (struvite or triple phosphate)	15%	↑	>7.0	 • Rectangular prism ("coffin lids")
Uric acid	5%	--	<7.0	• Yellow or red-brown, diamond or rhombus

Cystine	1%	↑	<7.0	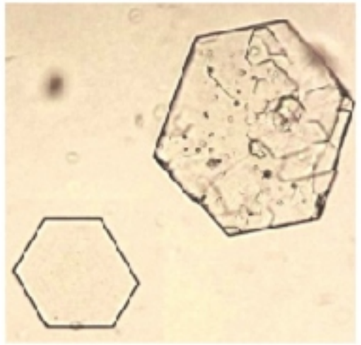 • Flat, yellow, **hexagonal**

©UWorld

Recurrent nephrolithiasis in a young patient should raise suspicion for **cystinuria**, which is confirmed by the pathognomonic finding of **hexagonal-shaped crystals** on urinalysis. Cystinuria is an autosomal recessive disorder affecting the high-affinity, sodium-independent dibasic amino acid transporter found on the apical membrane of intestinal and proximal renal tubular epithelial cells. This prevents dibasic amino acids (eg, cysteine, ornithine, lysine, and arginine) from being reabsorbed in the proximal renal tubules, leading to urine supersaturation with cystine and formation of **cystine stones** (ornithine, lysine, and arginine are relatively soluble in the urine and do not form stones).

Patients with suspected cystinuria without cystine crystals on urinalysis can be diagnosed by detecting **elevated urinary cysteine levels** (ie, aminoaciduria). The **sodium cyanide-nitroprusside test** is a qualitive screening test that detects the presence of urinary cystine. Cyanide is initially added to the urine, converting cystine to cysteine. Afterward, nitroprusside is added and reacts with the sulfhydryl group on free cysteine, causing a red-purple discoloration (positive test). Treatment of cystinuria involves increasing hydration and **urinary alkalinization** (eg, acetazolamide).

(Choices B, C, D, and E) Hypercalciuria (eg, sarcoidosis), hyperoxaluria (eg, Crohn disease), hyperuricosuria (eg, gout), and hypocitraturia (eg, distal renal tubular acidosis) are risk factors for recurrent calcium stone formation. These abnormalities are not typically found in patients with cystinuria.

Educational objective:

1 2 3 4 5 6 7 8 9 10 11 12 13 14 15 16 17 18 19 20 21 22 23 24 25 26 27 28 29 30

				• Flat, yellow, **hexagonal**

©UWorld

Recurrent nephrolithiasis in a young patient should raise suspicion for **cystinuria**, which is confirmed by the pathognomonic finding of **hexagonal-shaped crystals** on urinalysis. Cystinuria is an autosomal recessive disorder affecting the high-affinity, sodium-independent dibasic amino acid transporter found on the apical membrane of intestinal and proximal renal tubular epithelial cells. This prevents dibasic amino acids (eg, cysteine, ornithine, lysine, and arginine) from being reabsorbed in the proximal renal tubules, leading to urine supersaturation with cystine and formation of **cystine stones** (ornithine, lysine, and arginine are relatively soluble in the urine and do not form stones).

Patients with suspected cystinuria without cystine crystals on urinalysis can be diagnosed by detecting **elevated urinary cysteine levels** (ie, aminoaciduria). The **sodium cyanide-nitroprusside test** is a qualitive screening test that detects the presence of urinary cystine. Cyanide is initially added to the urine, converting cystine to cysteine. Afterward, nitroprusside is added and reacts with the sulfhydryl group on free cysteine, causing a red-purple discoloration (positive test). Treatment of cystinuria involves increasing hydration and **urinary alkalinization** (eg, acetazolamide).

(Choices B, C, D, and E) Hypercalciuria (eg, sarcoidosis), hyperoxaluria (eg, Crohn disease), hyperuricosuria (eg, gout), and hypocitraturia (eg, distal renal tubular acidosis) are risk factors for recurrent calcium stone formation. These abnormalities are not typically found in patients with cystinuria.

Educational objective:
Cystinuria results from defective dibasic amino acid transport in intestinal and proximal renal tubular epithelial cells. It most often presents with recurrent stone formation at a young age due to decreased reabsorption of cysteine from the urine. Urinalysis shows pathognomonic hexagonal cystine crystals, and the sodium cyanide-nitroprusside test can be used to detect excess cystine in the urine.

Pathology	Renal, Urinary Systems & Electrolytes	Cystinuria
Subject	System	Topic

Copyright © UWorld. All rights reserved.

1 2 3 4 5 6 7 8 9 10 11 12 13 14 15 16 17 18 19 20 21 22 23 24 25 26 27 28 29 30

A 65-year-old man comes to the emergency department due to acute-onset, severe right flank pain; nausea; and vomiting for the past hour. His medical conditions include prostate cancer and membranous nephropathy. Blood pressure is 148/60 mm Hg and pulse is 95/min. On physical examination, the patient appears to be in moderate distress due to pain and is diaphoretic. There is right costovertebral angle tenderness. Urinalysis shows hematuria. Contrast-enhanced CT scan reveals a wedge-shaped perfusion defect in the right kidney. The affected renal tissue is most likely to develop which of the following histologic changes over the next several days?

- A. Caseous necrosis
- B. Coagulative necrosis
- C. Fat necrosis
- D. Fibrinoid necrosis
- E. Liquefactive necrosis
- F. Tissue calcification

Submit

A 65-year-old man comes to the emergency department due to acute-onset, severe right flank pain; nausea; and vomiting for the past hour. His medical conditions include prostate cancer and membranous nephropathy. Blood pressure is 148/60 mm Hg and pulse is 95/min. On physical examination, the patient appears to be in moderate distress due to pain and is diaphoretic. There is right costovertebral angle tenderness. Urinalysis shows hematuria. Contrast-enhanced CT scan reveals a wedge-shaped perfusion defect in the right kidney. The affected renal tissue is most likely to develop which of the following histologic changes over the next several days?

- A. Caseous necrosis (2%)
- ✓ B. Coagulative necrosis (82%)
- C. Fat necrosis (0%)
- D. Fibrinoid necrosis (8%)
- E. Liquefactive necrosis (4%)
- F. Tissue calcification (1%)

Omitted
Correct answer
B

82%
Answered correctly

03 secs
Time Spent

03/24/2020
Last Updated

Explanation

Patterns of tissue necrosis		
Type	Etiology	Morphology

Explanation

Patterns of tissue necrosis		
Type	**Etiology**	**Morphology**
Liquefactive necrosis	• Severe bacterial infections (eg, gangrene) • CNS infarcts	• Necrotic tissue is digested by hydrolytic enzymes into a viscous fluid: ◦ Infected abscess fluid is creamy yellow due to dead leukocytes (pus) ◦ Brain infarcts resolve into CSF-filled spaces
Fibrinoid necrosis	• Hypertension • Vasculitis	• Damaged vessels leak fibrin/immune complexes • Eosinophilic layer of proteinaceous material in vessel walls
Fat necrosis	• Acute pancreatitis • Trauma (subcutaneous adipose tissue)	• Free fatty acids released by active enzymes (eg, lipases) or mechanical damage • Fatty acids combine with calcium, forming chalky-white deposits (saponification)
Caseous necrosis	• Mycobacterial infections • Fungal infections (eg, *Histoplasma*, *Cryptococcus*, *Coccidioides*)	• Friable, cheeselike material composed of cell fragments & amorphous proteinaceous debris • Surrounded by epithelioid macrophages & giant cells (granuloma)
Coagulative necrosis	• Irreversible ischemic injury outside CNS	• Tissue architecture is preserved due to denaturation of lytic enzymes: ◦ Cells are anucleate with eosinophilic cytoplasm ◦ Leukocytes eventually infiltrate & digest necrotic tissue

CSF = cerebrospinal fluid

This patient with multiple risk factors for hypercoagulability (ie, malignancy, membranous nephropathy) has flank pain, hematuria, and a **wedge-shaped** perfusion defect in the right kidney. This presentation is consistent with a **renal infarction**, likely from thromboembolic disease. Prolonged ischemia (as seen in infarcted tissue) results in irreversible cellular injury and cellular necrosis.

Necrosis is an uncontrolled process of cell death that results in denaturation of cellular proteins and enzymatic digestion of cellular components. Unlike apoptosis, necrosis leads to a loss of membrane integrity and leakage of proinflammatory intracellular material that can injure the surrounding tissue.

Necrosis occurs in several distinct morphologic patterns. In most organs, irreversible **ischemic injury** typically results in **coagulative necrosis**. Because the digestive enzymes denature before they can significantly disrupt tissue integrity, the cellular architecture is maintained but nuclei are absent. A major exception is tissue within the CNS, in which ischemia (eg, stroke) causes liquefactive necrosis with digestion of cellular constituents and liquefaction of necrotic tissue **(Choice E)**.

(Choice A) Caseous necrosis is a pattern of necrosis seen with mycobacterial or certain fungal (eg, *Histoplasma*, *Cryptococcus*) infections. Collections of epithelioid macrophages and giant cells surround white, friable, cheese-like material made up of cell fragments and proteinaceous debris (ie, caseating granulomas).

(Choice C) Fat necrosis occurs in areas with high numbers of adipocytes (eg, pancreas, breast, subcutaneous fat) and is frequently seen in pancreatitis. Enzymes released from damaged cells break down triglycerides into free fatty acids, which combine with calcium to form soaps; anucleated adipocytes with calcium deposits are visible on microscopy.

(Choice D) Fibrinoid necrosis is a histologic pattern of injury seen in the walls of blood vessels affected by vasculitis or malignant hypertension. It results from immune complexes and/or plasma proteins (eg, fibrin) leaking through the damaged intima and depositing within the vessel wall; the deposits appear histologically as a circumferential ring of pink, amorphous material surrounding the vascular lumen.

(Choice F) Dystrophic calcification occurs in areas of tissue injury or necrosis that escape removal by phagocytes. Phosphate ions in the necrotic tissue bind calcium to form salts, which can appear grossly as white granules and microscopically as amorphous, basophilic material on hematoxylin and eosin stain. However, the calcification develops slowly over the months and years following the initial injury.

Educational objective:
Lethal tissue ischemia causes coagulative necrosis in most tissues (eg, kidney, myocardium); cellular architecture is maintained but nuclei are

Necrosis occurs in several distinct morphologic patterns. In most organs, irreversible **ischemic injury** typically results in **coagulative necrosis**. Because the digestive enzymes denature before they can significantly disrupt tissue integrity, the cellular architecture is maintained but nuclei are absent. A major exception is tissue within the CNS, in which ischemia (eg, stroke) causes liquefactive necrosis with digestion of cellular constituents and liquefaction of necrotic tissue **(Choice E)**.

(Choice A) Caseous necrosis is a pattern of necrosis seen with mycobacterial or certain fungal (eg, *Histoplasma*, *Cryptococcus*) infections. Collections of epithelioid macrophages and giant cells surround white, friable, cheese-like material made up of cell fragments and proteinaceous debris (ie, caseating granulomas).

(Choice C) Fat necrosis occurs in areas with high numbers of adipocytes (eg, pancreas, breast, subcutaneous fat) and is frequently seen in pancreatitis. Enzymes released from damaged cells break down triglycerides into free fatty acids, which combine with calcium to form soaps; anucleated adipocytes with calcium deposits are visible on microscopy.

(Choice D) Fibrinoid necrosis is a histologic pattern of injury seen in the walls of blood vessels affected by vasculitis or malignant hypertension. It results from immune complexes and/or plasma proteins (eg, fibrin) leaking through the damaged intima and depositing within the vessel wall; the deposits appear histologically as a circumferential ring of pink, amorphous material surrounding the vascular lumen.

(Choice F) Dystrophic calcification occurs in areas of tissue injury or necrosis that escape removal by phagocytes. Phosphate ions in the necrotic tissue bind calcium to form salts, which can appear grossly as white granules and microscopically as amorphous, basophilic material on hematoxylin and eosin stain. However, the calcification develops slowly over the months and years following the initial injury.

Educational objective:
Lethal tissue ischemia causes coagulative necrosis in most tissues (eg, kidney, myocardium); cellular architecture is maintained but nuclei are absent. The exception is ischemic cell death in the CNS, which causes liquefactive necrosis.

Pathology	Renal, Urinary Systems & Electrolytes	Necrosis
Subject	System	Topic

Copyright © UWorld. All rights reserved.

A 20-year-old woman comes to the office due to intermittent pain and swelling of both knees over the past 3 months. She has no fever, chills, or abnormal vaginal discharge. The patient has no other medical conditions and is not sexually active. Temperature is 37.2 C (99 F), blood pressure is 150/90 mm Hg, and pulse is 78/min. Small, nontender oral ulcers are present. Examination shows mild tenderness of the knee joints but no effusion. The remainder of the examination shows no abnormalities. Laboratory results reveal anemia, thrombocytopenia, and elevated serum creatinine. Urinalysis shows proteinuria and red blood cell casts. Which of the following pathogenic mechanisms is most likely responsible for this patient's renal disease?

A. Activation of $CD8^+$ T lymphocytes

B. Deposition of immune complexes containing bacterial antigens

C. Deposition of immune complexes containing DNA and anti-DNA

D. Deposition of immunoglobulin light chains

E. Formation of autoantibodies to podocyte antigens

Submit

1 2 3 4 5 6 7 8 9 10 11 12 13 14 15 16 17 18 19 20 21 22 23 24 25 26 27 28 29 30

A 20-year-old woman comes to the office due to intermittent pain and swelling of both knees over the past 3 months. She has no fever, chills, or abnormal vaginal discharge. The patient has no other medical conditions and is not sexually active. Temperature is 37.2 C (99 F), blood pressure is 150/90 mm Hg, and pulse is 78/min. Small, nontender oral ulcers are present. Examination shows mild tenderness of the knee joints but no effusion. The remainder of the examination shows no abnormalities. Laboratory results reveal anemia, thrombocytopenia, and elevated serum creatinine. Urinalysis shows proteinuria and red blood cell casts. Which of the following pathogenic mechanisms is most likely responsible for this patient's renal disease?

A. Activation of $CD8^+$ T lymphocytes (3%)

B. Deposition of immune complexes containing bacterial antigens (9%)

✓ C. Deposition of immune complexes containing DNA and anti-DNA (73%)

D. Deposition of immunoglobulin light chains (7%)

E. Formation of autoantibodies to podocyte antigens (5%)

Omitted
Correct answer
C

73%
Answered correctly

02 secs
Time Spent

07/08/2020
Last Updated

Explanation

This young woman with hypertension, elevated serum creatinine, proteinuria, and red blood cells casts on urinalysis has **glomerulonephritis**. In association with the transient arthralgias, oral ulcers, and cytopenia, this presentation suggests systemic lupus erythematosus (SLE) complicated by **lupus nephritis**. SLE is an autoimmune disease that occurs due to the formation of autoantibodies against cell surface and nuclear antigens. Disease manifestations result from direct tissue injury by the autoantibodies or from the formation of circulating immune complexes that deposit in

This young woman with hypertension, elevated serum creatinine, proteinuria, and red blood cells casts on urinalysis has **glomerulonephritis**. In association with the transient arthralgias, oral ulcers, and cytopenia, this presentation suggests systemic lupus erythematosus (SLE) complicated by **lupus nephritis**. SLE is an autoimmune disease that occurs due to the formation of autoantibodies against cell surface and nuclear antigens. Disease manifestations result from direct tissue injury by the autoantibodies or from the formation of circulating immune complexes that deposit in tissues.

Lupus nephritis occurs primarily due to deposition of **DNA/anti-DNA immune complexes** within the glomerulus (eg, mesangium, subendothelial or subepithelial space). This results in the activation of complement and the recruitment of inflammatory cells **(type III hypersensitivity)**, leading to glomerular injury and reduced renal function. Elevated levels of anti-DNA antibodies often precede clinically apparent renal disease and can be used to monitor disease activity.

(Choice A) Activation of $CD4^+$ and $CD8^+$ T lymphocytes by donor histocompatibility antigens occurs during acute cellular rejection of a renal allograft. CD8+ T cells do not play a prominent role in the pathogenesis of lupus nephritis.

(Choice B) Poststreptococcal glomerulonephritis is another cause of nephritic syndrome and results from glomerular deposition of immune complexes involving streptococcal antigens. However, it typically occurs 1-4 weeks after an infection (eg, impetigo, pharyngitis) and is far more common in young children. In addition, it is not associated with oral ulcers or cytopenias.

(Choice D) Multiple myeloma can cause anemia and bone pain; kidney injury occurs due to monoclonal free light-chain deposition in the renal tubules. However, urinalysis would be expected to demonstrate waxy casts composed of Bence Jones proteins, not red blood cell casts. In addition, multiple myeloma does not cause oral ulcers and is extremely uncommon in young patients.

(Choice E) Autoantibodies against podocyte antigens occurs in membranous nephropathy. Although membranous nephropathy can occur in SLE, it results in nephrotic syndrome characterized by massive proteinuria and edema. Red blood cell casts are unexpected.

Educational objective:
Systemic lupus erythematosus is an autoimmune disease characterized by the formation of antinuclear antibodies (eg, anti-DNA antibodies). Lupus nephritis occurs primarily due to the formation of immune complexes containing DNA and anti-DNA in the circulation. These are deposited in the glomerulus where they result in complement activation, recruitment of inflammatory cells, and renal injury (type III hypersensitivity).

This young woman with hypertension, elevated serum creatinine, proteinuria, and red blood cells casts on urinalysis has **glomerulonephritis**. In association with the transi ed by **lupus nephritis**. SLE ns. Disease manifestations re t in tissues.

Lupus nephritis occurs pri al or subepithelial space). T ng to glomerular injury and re n be used to monitor disease a

(Choice A) Activation of (allograft. CD8+ T cells do

(Choice B) Poststreptocc complexes involving strep e common in young children

(Choice D) Multiple myel tubules. However, urinaly addition, multiple myeloma

(Choice E) Autoantibodie SLE, it results in nephrotic

Educational objective:
Systemic lupus erythemat
Lupus nephritis occurs pri ted in the glomerulus where they result in complement activation, recruitment of inflammatory cells, and renal injury (type III hypersensitivity).

Exhibit Display

Manifestations of systemic lupus erythematosus	
Clinical symptoms	• Constitutional: fever, fatigue & weight loss • Symmetric, migratory arthritis • Skin: butterfly rash & photosensitivity • Serositis: pleurisy, pericarditis & peritonitis • Thromboembolic events (due to vasculitis & antiphospholipid antibodies) • Neurologic: cognitive dysfunction & seizures

Laboratory findings	• Hemolytic anemia, thrombocytopenia & leukopenia
	• Hypocomplementemia (C3 & C4)
	• Antibodies:
	  ◦ ANA (sensitive)
	  ◦ Anti-dsDNA & anti-Sm (specific)
	• Renal involvement: proteinuria & elevated creatinine

ANA = antinuclear antibodies; **dsDNA** = double-stranded DNA.

Add To New Card | Existing Card

or subepithelial space). This results in the activation of complement and the recruitment of inflammatory cells **(type III hypersensitivity)**, leading to glomerular injury and reduced renal function. Elevated levels of anti-DNA antibodies often precede clinically apparent renal disease and can be used to monitor disease activity.

(Choice A) Activation of $CD4^+$ and $CD8^+$ T lymphocytes by donor histocompatibility antigens occurs during acute cellular rejection of a renal allograft. CD8+ T cells do not play a prominent role in the pathogenesis of lupus nephritis.

(Choice B) Poststreptococcal glomerulonephritis is another cause of nephritic syndrome and results from glomerular deposition of immune complexes involving streptococcal antigens. However, it typically occurs 1-4 weeks after an infection (eg, impetigo, pharyngitis) and is far more common in young children. In addition, it is not associated with oral ulcers or cytopenias.

(Choice D) Multiple myeloma can cause anemia and bone pain; kidney injury occurs due to monoclonal free light-chain deposition in the renal tubules. However, urinalysis would be expected to demonstrate waxy casts composed of Bence Jones proteins, not red blood cell casts. In addition, multiple myeloma does not cause oral ulcers and is extremely uncommon in young patients.

(Choice E) Autoantibodies against podocyte antigens occurs in membranous nephropathy. Although membranous nephropathy can occur in SLE, it results in nephrotic syndrome characterized by massive proteinuria and edema. Red blood cell casts are unexpected.

Educational objective:

Systemic lupus erythematosus is an autoimmune disease characterized by the formation of antinuclear antibodies (eg, anti-DNA antibodies). Lupus nephritis occurs primarily due to the formation of immune complexes containing DNA and anti-DNA in the circulation. These are deposited in the glomerulus where they result in complement activation, recruitment of inflammatory cells, and renal injury (type III hypersensitivity).

References

- The pathogenesis of lupus nephritis.

Pathology	Renal, Urinary Systems & Electrolytes	SLE
Subject	System	Topic

Copyright © UWorld. All rights reserved.

A 10-year-old boy is brought to the office due to dark brown urine that he first noticed yesterday after swimming practice. Blood pressure is 130/80 mm Hg. Physical examination is normal with the exception of bilateral periorbital edema. Laboratory results are as follows:

Serum chemistry	
Sodium	140 mEq/L
Potassium	4 mEq/L
Blood urea nitrogen	14 mg/dL
Creatinine	1.4 mg/dL
Creatine kinase	86 U/L

Urinalysis	
Protein	1+
Leukocyte esterase	negative
Nitrites	negative
White blood cells	1-2/hpf
Red blood cells	many/hpf
Casts	RBC casts

Which of the following is the most likely diagnosis?

A. Minimal change disease

B. Nephrolithiasis

1 2 3 4 5 6 7 8 9 10 11 12 13 14 15 16 17 18 19 20 21 22 23 24 25 26 27 28 29 30

Creatinine	1.4 mg/dL
Creatine kinase	86 U/L
Urinalysis	
Protein	1+
Leukocyte esterase	negative
Nitrites	negative
White blood cells	1-2/hpf
Red blood cells	many/hpf
Casts	RBC casts

Which of the following is the most likely diagnosis?

A. Minimal change disease

B. Nephrolithiasis

C. Postinfectious glomerulonephritis

D. Pyelonephritis

E. Rhabdomyolysis

Submit

1 2 3 4 5 6 7 8 9 10 11 12 13 14 15 16 17 18 19 20 21 22 23 24 25 26 27 28 29 30

Creatinine	1.4 mg/dL
Creatine kinase	86 U/L
Urinalysis	
Protein	1+
Leukocyte esterase	negative
Nitrites	negative
White blood cells	1-2/hpf
Red blood cells	many/hpf
Casts	RBC casts

Which of the following is the most likely diagnosis?

- A. Minimal change disease (14%)
- B. Nephrolithiasis (1%)
- ✓ C. Postinfectious glomerulonephritis (63%)
- D. Pyelonephritis (1%)
- E. Rhabdomyolysis (18%)

Omitted
Correct answer

63%
Answered correctly

04 secs
Time Spent

03/21/2020
Last Updated

Explanation

Acute poststreptococcal glomerulonephritis	

Clinical features	• Can be asymptomatic
	• If symptomatic:
	  ◦ Gross hematuria (tea- or cola-colored urine)
	  ◦ Edema (periorbital, generalized)
	  ◦ Hypertension

Laboratory findings	• Urinalysis: + protein, + blood, ± red blood cell casts
	• Serum:
	  ◦ ↓ C3 & possible ↓ C4
	  ◦ ↑ Serum creatinine
	  ◦ ↑ Anti-DNase B & ↑ AHase
	  ◦ ↑ ASO & ↑ anti-NAD (from preceding pharyngitis)

AHase = antihyaluronidase; **anti-DNase B** = antideoxyribonuclease-B; **ASO** = antistreptolysin O.

This pediatric patient with periorbital edema, hypertension, and hematuria with red blood cell (RBC) casts, as well as mild proteinuria on urinalysis, has **poststreptococcal glomerulonephritis**, a nonsuppurative complication of a pharyngeal or skin (eg, impetigo) infection. Infection with nephritogenic strains of group A *Streptococcus* (eg, *S pyogenes*) can induce formation of antigen-antibody complexes, which are deposited on the glomerular basement membrane. Subsequent activation of complement and inflammation can lead to **nephritic syndrome** 2-4 weeks after the infection; because of this delay, parents may not report the inciting infection.

Urine studies in nephritic syndrome typically reveal RBCs, mild protein, and **RBC casts** (indicating an intrarenal process). Serum studies show elevated creatinine, **antistreptococcal antibodies** (from recent infection), and decreased C3 (glomerular complement deposition). For refractory cases in which biopsies are indicated, histology shows diffusely enlarged, hypercellular glomeruli, RBC casts in nephron tubules, and interstitial edema and inflammation (white arrow). Electron microscopy reveals electron-dense, **subepithelial** deposits or "humps" along the glomerular

This pediatric patient with periorbital edema, hypertension, and hematuria with red blood cell (RBC) casts, as well as mild proteinuria on urinalysis, has **poststreptococcal glomerulonephritis**, a nonsuppurative complication of a pharyngeal or skin (eg, impetigo) infection. Infection with nephritogenic strains of group A *Streptococcus* (eg, *S pyogenes*) can induce formation of antigen-antibody complexes, which are deposited on the glomerular basement membrane. Subsequent activation of complement and inflammation can lead to **nephritic syndrome** 2-4 weeks after the infection; because of this delay, parents may not report the inciting infection.

Urine studies in nephritic syndrome typically reveal RBCs, mild protein, and **RBC casts** (indicating an intrarenal process). Serum studies show elevated creatinine, **antistreptococcal antibodies** (from recent infection), and decreased C3 (glomerular complement deposition). For refractory cases in which biopsies are indicated, histology shows diffusely enlarged, hypercellular glomeruli, RBC casts in nephron tubules, and interstitial edema and inflammation (white arrow). Electron microscopy reveals electron-dense, **subepithelial** deposits or "humps" along the glomerular basement membrane that represent antigen-antibody complexes.

(Choice A) Minimal change disease is the most common cause of pediatric nephrotic syndrome. It is characterized by immune-related loss of the normal glomerular anionic charge (which prevents filtration of negatively charged albumin), leading to heavy proteinuria. However, hematuria and hypertension are unexpected.

(Choice B) Nephrolithiasis is a common cause of hematuria; however, the glomeruli are not involved, so RBC casts are unexpected. In addition, nephrolithiasis is rare in children and typically presents with back pain radiating to the groin.

(Choice D) Pyelonephritis is most commonly due to an ascending bacterial infection from the bladder. Microscopic urinalysis findings are similar to those of a urinary tract infection (eg, bacteria, leukocytes, nitrites, leukocyte esterase) with the addition of white blood cell casts.

(Choice E) Rhabdomyolysis can occur after strenuous exercise and results in muscle pain, elevated creatine kinase levels, and myoglobinuria (ie, positive urine dipstick for blood without RBCs on microscopy). This patient's normal creatine kinase level and the presence of many RBCs on urine microscopy are not suggestive of rhabdomyolysis.

Educational objective:
Poststreptococcal glomerulonephritis presents most commonly in children with hematuria, hypertension, and periorbital edema. Red blood cell casts and mild proteinuria may be present on urinalysis, and serum creatinine may be elevated.

References

Settings

1
2
3
4
5
6
7
8
9
10
11
12
13
14
15
16
17
18
19
20
21
22
23
24
25
26
27
28
29
30

Item 25 of 40
Question Id: 1

Mark | Previous | Next | Full Screen | Tutorial | Lab Values | Notes | Calculator | Reverse Color | Text Zoom | Settings

This pediatric patient with periorbital edema, hypertension, and hematuria with red blood cell (RBC) casts, as well as mild proteinuria on urinalysis,

Exhibit Display

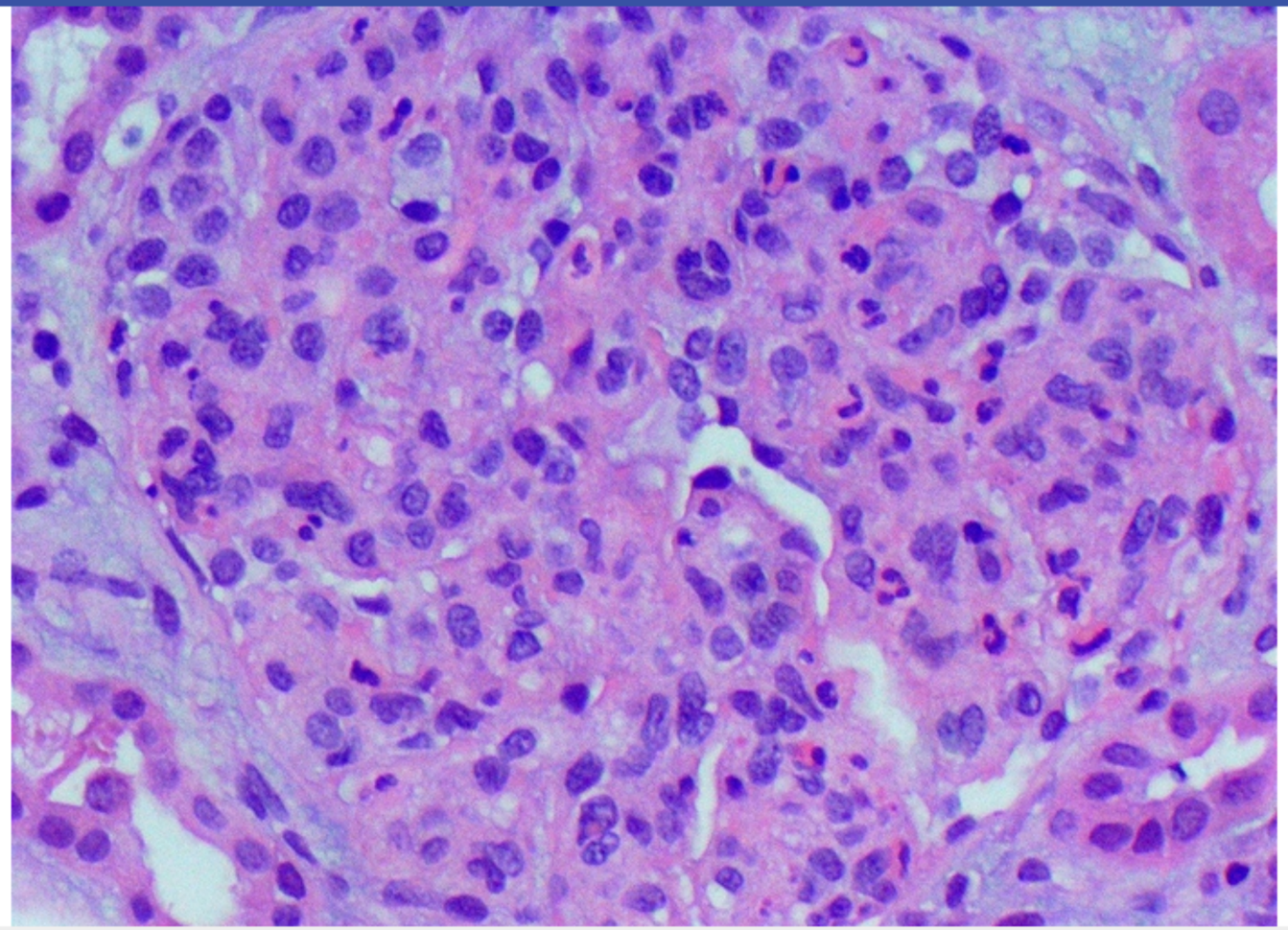

Zoom In | Zoom Out | Reset | Add To New Card | Existing Card

References

Block Time Remaining: 00:05:22
TUTOR

3 | Feedback | Suspend | End Block

This pediatric patient with periorbital edema, hypertension, and hematuria with red blood cell (RBC) casts, as well as mild proteinuria on urinalysis,

Exhibit Display

Acute postinfectious glomerulonephritis

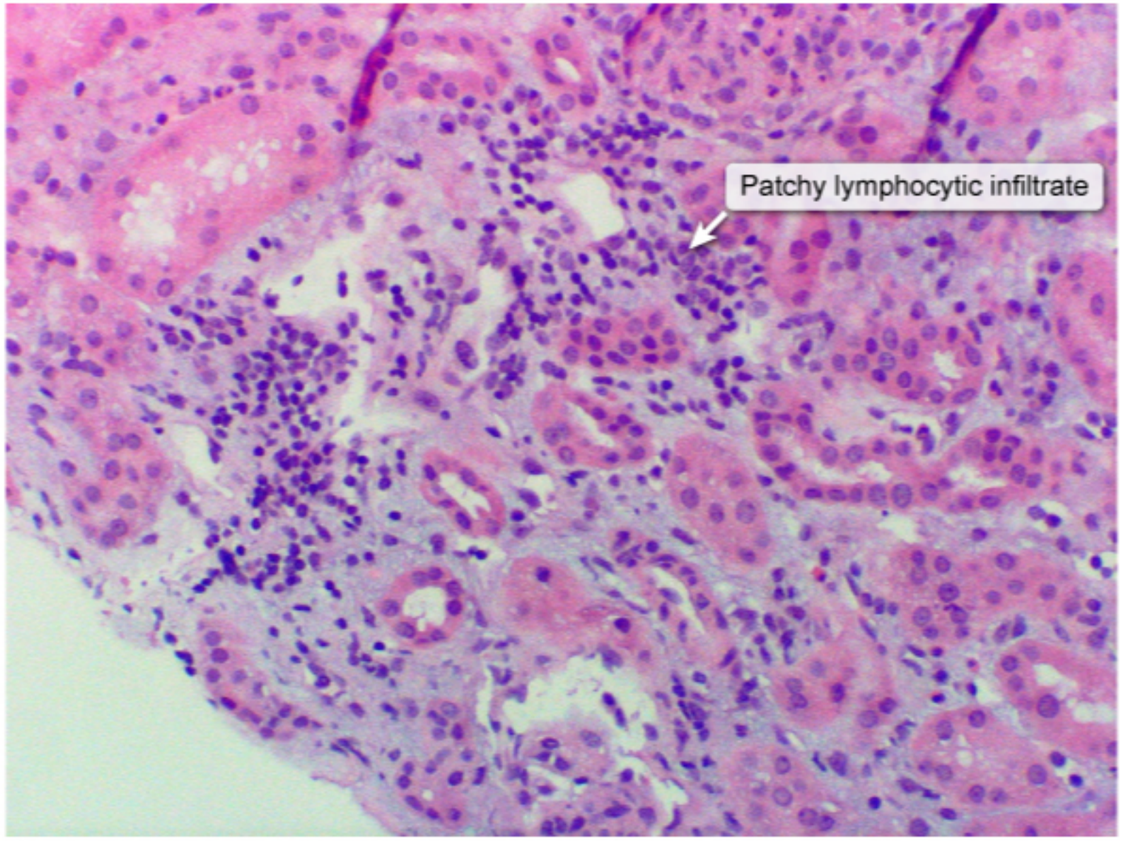

©UWorld

Zoom In | Zoom Out | Reset | Add To New Card | Existing Card

References

elevated creatinine, **antistreptococcal antibodies** (from recent infection), and decreased C3 (glomerular complement deposition). For refractory cases in which biopsies are indicated, histology shows diffusely enlarged, hypercellular glomeruli, RBC casts in nephron tubules, and interstitial edema and inflammation (white arrow). Electron microscopy reveals electron-dense, **subepithelial** deposits or "humps" along the glomerular basement membrane that represent antigen-antibody complexes.

(Choice A) Minimal change disease is the most common cause of pediatric nephrotic syndrome. It is characterized by immune-related loss of the normal glomerular anionic charge (which prevents filtration of negatively charged albumin), leading to heavy proteinuria. However, hematuria and hypertension are unexpected.

(Choice B) Nephrolithiasis is a common cause of hematuria; however, the glomeruli are not involved, so RBC casts are unexpected. In addition, nephrolithiasis is rare in children and typically presents with back pain radiating to the groin.

(Choice D) Pyelonephritis is most commonly due to an ascending bacterial infection from the bladder. Microscopic urinalysis findings are similar to those of a urinary tract infection (eg, bacteria, leukocytes, nitrites, leukocyte esterase) with the addition of white blood cell casts.

(Choice E) Rhabdomyolysis can occur after strenuous exercise and results in muscle pain, elevated creatine kinase levels, and myoglobinuria (ie, positive urine dipstick for blood without RBCs on microscopy). This patient's normal creatine kinase level and the presence of many RBCs on urine microscopy are not suggestive of rhabdomyolysis.

Educational objective:
Poststreptococcal glomerulonephritis presents most commonly in children with hematuria, hypertension, and periorbital edema. Red blood cell casts and mild proteinuria may be present on urinalysis, and serum creatinine may be elevated.

References

- New trends of an old disease: the acute post infectious glomerulonephritis at the beginning of the new millennium.

Pathology	Renal, Urinary Systems & Electrolytes	Poststreptococcal Glomerulonephritis
Subject	System	Topic

Copyright © UWorld. All rights reserved.

1 2 3 4 5 6 7 8 9 10 11 12 13 14 15 16 17 18 19 20 21 22 23 24 25 26 27 28 29 30

A 54-year-old man comes to the physician due to blood in his urine and abdominal discomfort that occurred 2 days ago. He was moving potted plants around his porch when he started having pain in his abdomen. Afterward, he noticed blood in his urine but says it resolved the following day. He has a history of hypertension. The patient does not use tobacco, alcohol, or illicit drugs. Physical examination shows no abnormalities. CT scan of the abdomen with contrast is shown below.

1 2 3 4 5 6 7 8 9 10 11 12 13 14 15 16 17 18 19 20 21 22 23 24 25 26 27 28 29 30

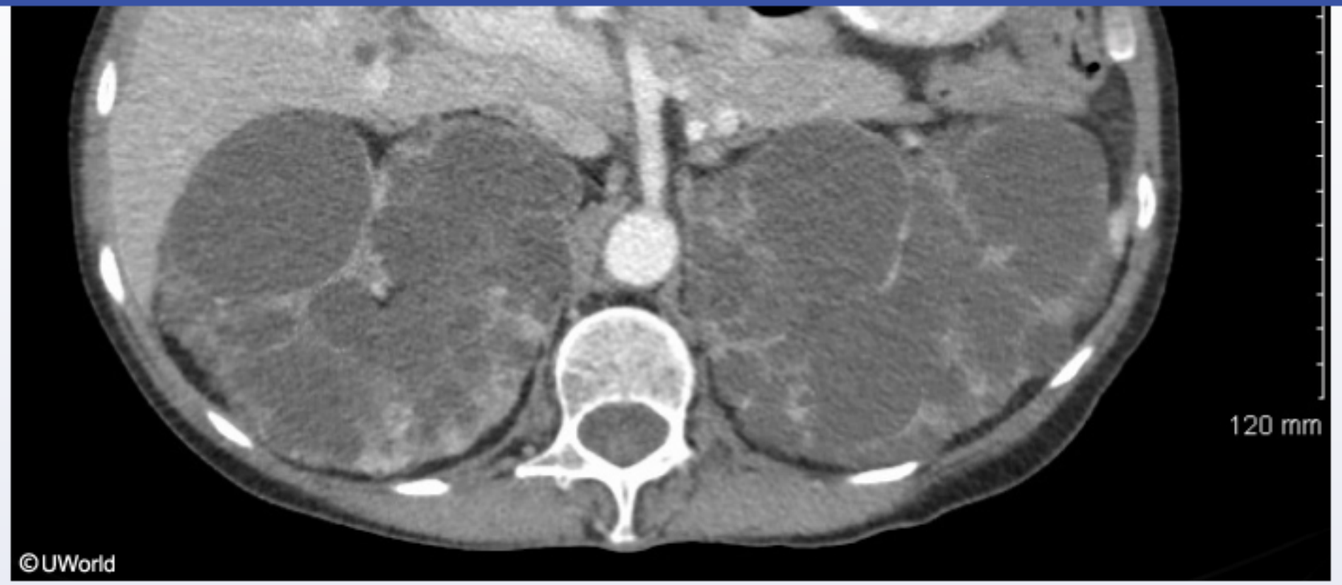

Which of the following is the most likely diagnosis?

- A. Glomerulonephritis
- B. Hydronephrosis
- C. Nephroblastoma
- D. Polycystic kidney disease
- E. Renal cell carcinoma

Submit

1 2 3 4 5 6 7 8 9 10 11 12 13 14 15 16 17 18 19 20 21 22 23 24 25 26 27 28 29 30

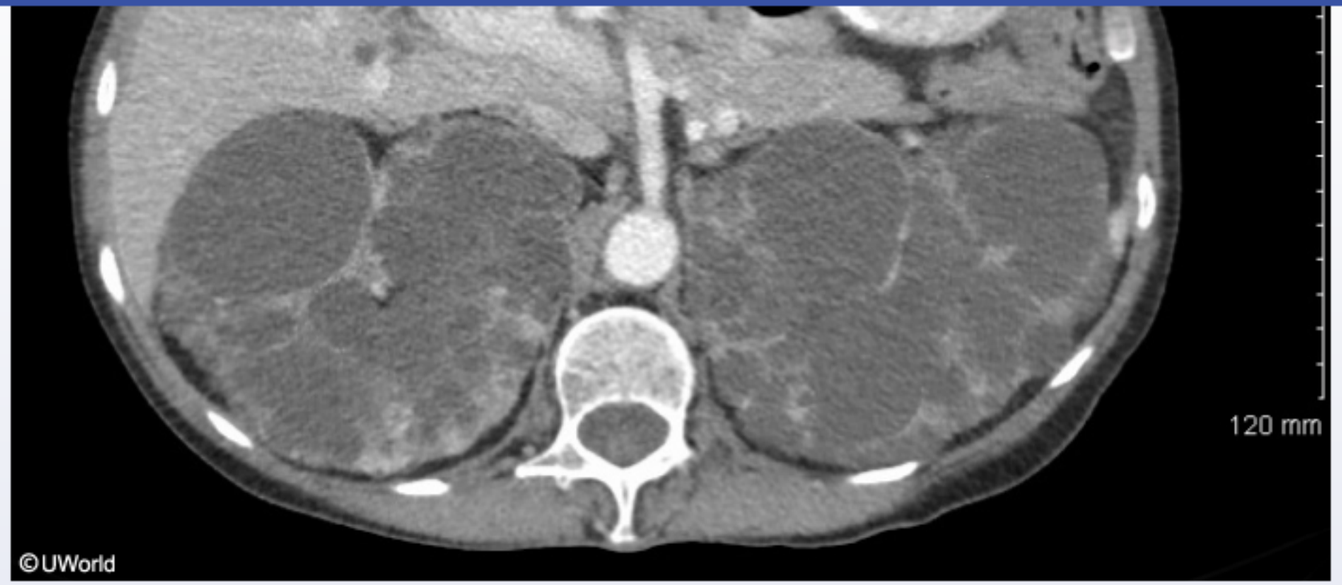

Which of the following is the most likely diagnosis?

- A. Glomerulonephritis (1%)
- B. Hydronephrosis (5%)
- C. Nephroblastoma (1%)
- ✓ D. Polycystic kidney disease (81%)
- E. Renal cell carcinoma (10%)

Omitted
Correct answer

81%
Answered correctly

04 secs
Time Spent

03/04/2020
Last Updated

Autosomal dominant polycystic kidney disease	
Genetics	• Autosomal dominant mutation in *PKD1* or *PKD2*
Clinical features	• **Symptoms:** often asymptomatic; ± abdominal/flank pain • **Signs:** hypertension, hematuria, progressive renal failure
Imaging	• Multiple renal cysts (thin-walled, nonenhancing)
Extrarenal manifestations	• Liver cysts • Cerebral aneurysms

This patient with flank pain, hematuria, hypertension, and multiple renal and hepatic cysts on imaging (smooth, thin walls with nonenhancing cystic fluid) has **autosomal dominant polycystic kidney disease** (ADPKD). ADPKD is the most common hereditary cause of renal failure in **adults** and is caused by mutations in the polycystin genes (*PKD1*, *PKD2*) that result in progressive cystic enlargement of the kidneys.

Patients often remain asymptomatic until their fourth or fifth decade, when relentless enlargement of the cysts begins to impair renal function; **hypertension** is often the earliest clinical sign. Stretching of the renal capsule and dilation/rupture of the cysts can result in abdominal/flank pain; cyst rupture can also cause gross hematuria. Renal dysfunction worsens with age, and approximately 50% of adults progress to **end-stage renal disease** by age 70. Extrarenal manifestations include **liver cysts** and **intracranial aneurysms** that may rupture.

(Choice A) Glomerulonephritis can cause hematuria, hypertension, and renal failure but is not associated with cyst formation. Casts are typically visible on urinalysis.

(Choice B) Hydronephrosis can cause hematuria and pain, particularly if associated with an obstructing stone. However, dilation of the ureters and calyces would be expected on imaging.

(Choice C) Nephroblastoma (Wilms tumor) is the most common pediatric renal malignancy but is rare in adults. It typically presents with a painful abdominal mass, hematuria, and hypertension. CT scan demonstrates a solid, heterogenous renal mass with patchy enhancement.

(Choice E) Renal cell carcinoma is the most common renal malignancy in adults and often presents with hematuria, hypertension, and flank pain. However, imaging typically demonstrates solitary renal mass with areas of contrast enhancement and focal necrosis; bilateral cystic

Settings

1 2 3 4 5 6 7 8 9 10 11 12 13 14 15 16 17 18 19 20 21 22 23 24 25 26 27 28 29 30

Item 26 of 40
Question Id: 3

Mark | Previous | Next | Full Screen | Tutorial | Lab Values | Notes | Calculator | Reverse Color | Text Zoom | Settings

Exhibit Display

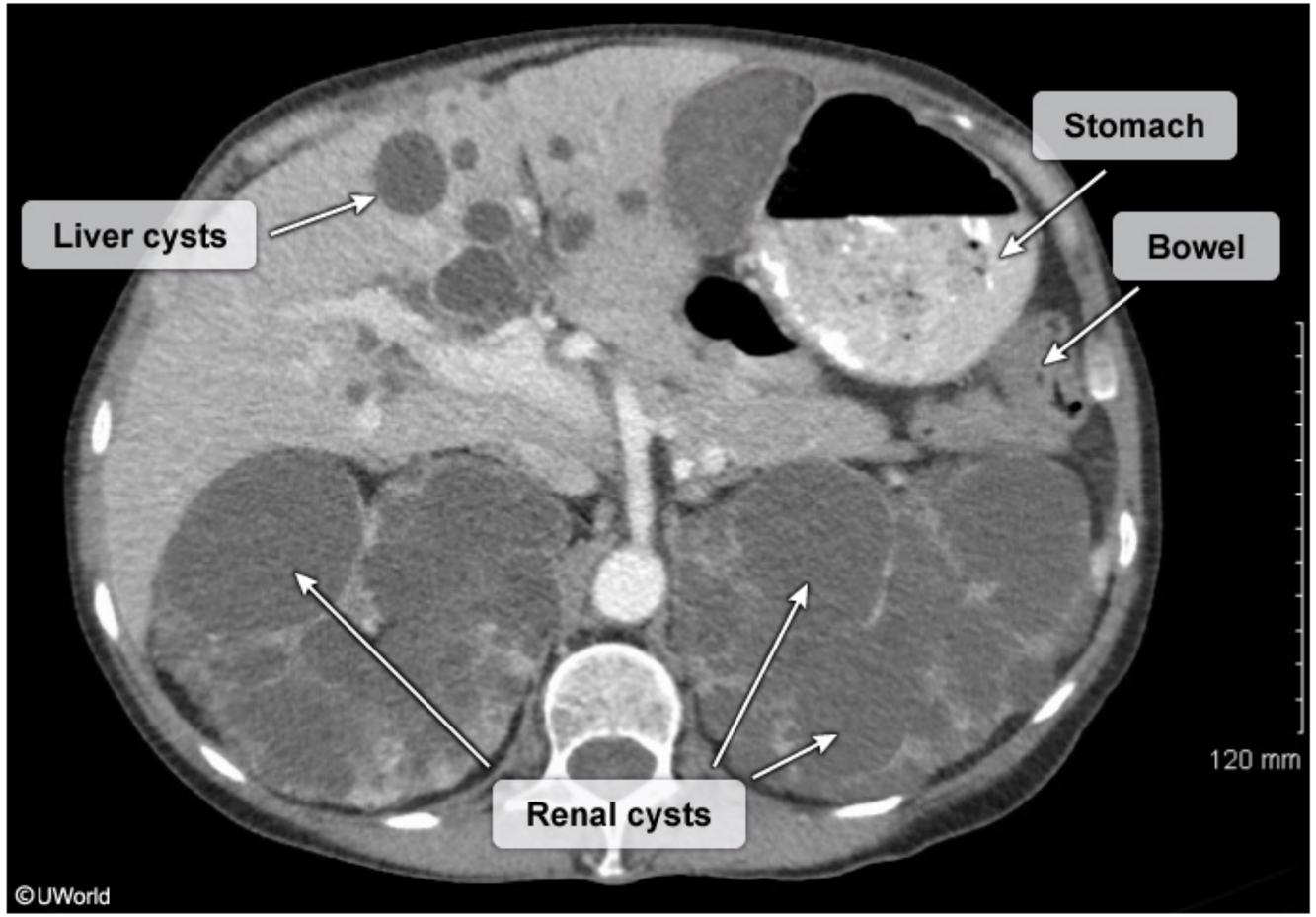

Zoom In | Zoom Out | Reset | Add To New Card | Existing Card

pain. However, imaging typically demonstrates solitary renal mass with areas of contrast enhancement and focal necrosis; bilateral cystic

Block Time Remaining: 00:05:26
TUTOR

6 | Feedback | Suspend | End Block

Settings

1 2 3 4 5 6 7 8 9 10 11 12 13 14 15 16 17 18 19 20 21 22 23 24 25 26 27 28 29 30

Item 26 of 40
Question Id: 3

Mark | Previous | Next | Full Screen | Tutorial | Lab Values | Notes | Calculator | Reverse Color | Text Zoom | Settings

Patients often remain asymptomatic until their fourth or fifth decade, when relentless enlargement of the cysts begins to impair renal function;

Exhibit Display

Zoom In | Zoom Out | Reset | Add To New Card | Existing Card

Block Time Remaining: 00:05:26
TUTOR

6 | Feedback | Suspend | End Block

Settings

1 2 3 4 5 6 7 8 9 10 11 12 13 14 15 16 17 18 19 20 21 22 23 24 25 26 27 28 29 30

Item 26 of 40
Question Id: 3

Mark | Previous | Next | Full Screen | Tutorial | Lab Values | Notes | Calculator | Reverse Color | Text Zoom | Settings

Patients often remain asymptomatic until their fourth or fifth decade, when relentless enlargement of the cysts begins to impair renal function;

Exhibit Display

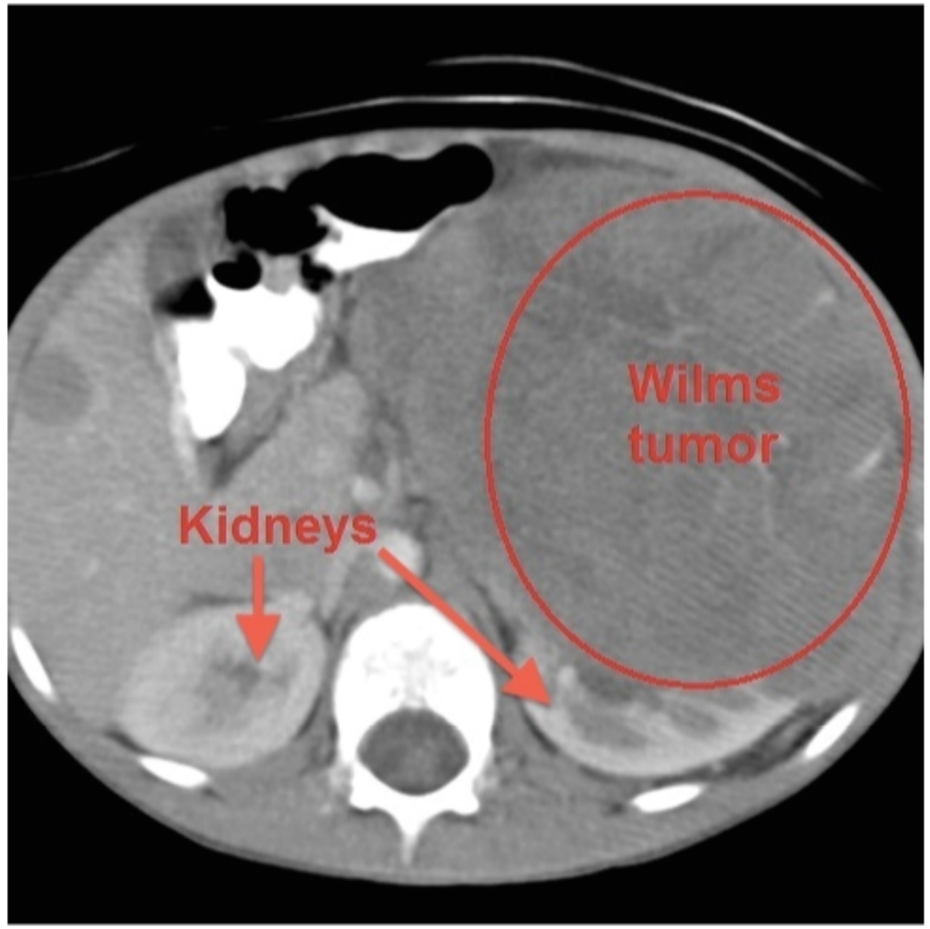

Zoom In | Zoom Out | Reset | Add To New Card | Existing Card

Block Time Remaining: 00:05:26
TUTOR

6 | Feedback | Suspend | End Block

A 32-year-old man is hospitalized with multiple fractures and internal bleeding following a motor vehicle collision. He is successfully resuscitated and taken to the operating room for fixation of a left femoral fracture. The patient's condition remains stable postoperatively, and he is transferred to the surgical floor. Blood pressure is 118/68 mm Hg and pulse is 88/min. He develops oliguria on the second day of hospitalization. Renal biopsy findings are shown in the image below.

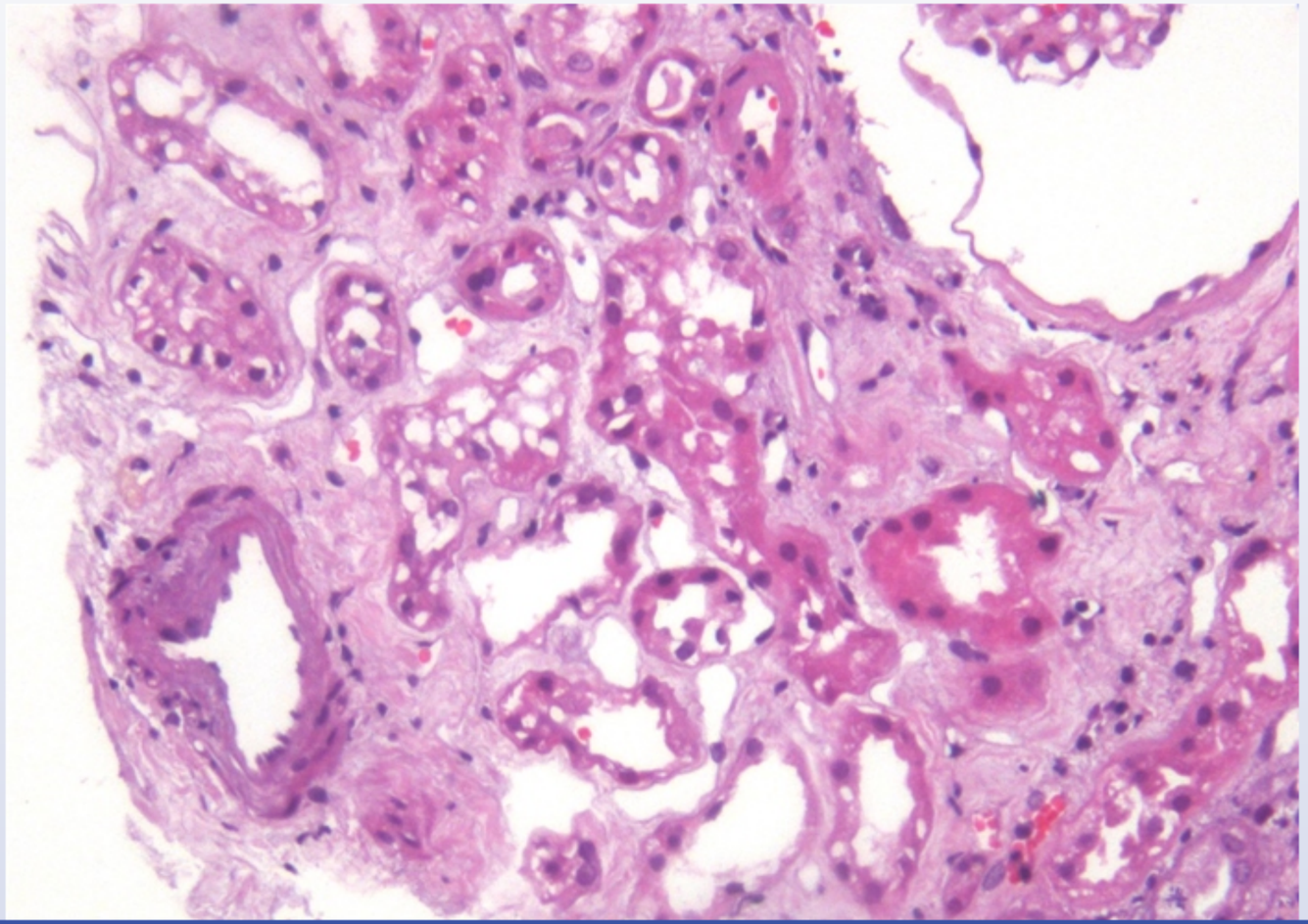

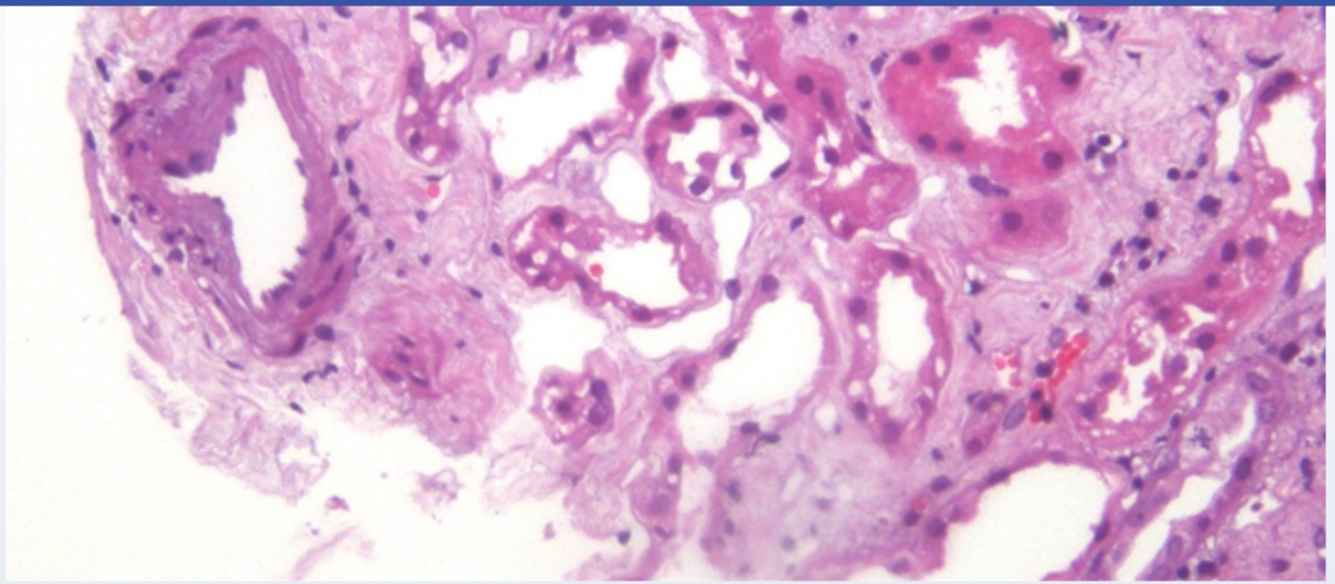

If the kidney biopsy were repeated 3 weeks from now, which of the following would most likely be seen?

- A. Diffuse mesangial sclerosis
- B. Glomerular epithelial proliferation
- C. Scarring and atrophy of the medulla
- D. Segmental glomerulosclerosis
- E. Tubular re-epithelization

Submit

1 2 3 4 5 6 7 8 9 10 11 12 13 14 15 16 17 18 19 20 21 22 23 24 25 26 27 28 29 30

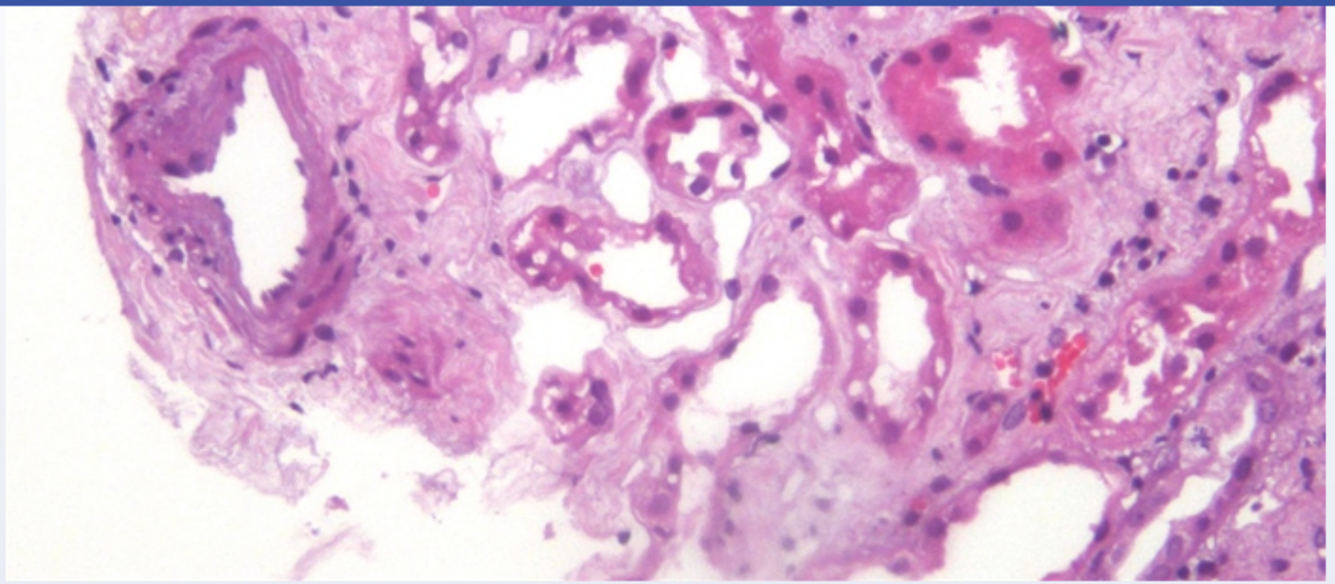

If the kidney biopsy were repeated 3 weeks from now, which of the following would most likely be seen?

A. Diffuse mesangial sclerosis (5%)

B. Glomerular epithelial proliferation (4%)

C. Scarring and atrophy of the medulla (8%)

D. Segmental glomerulosclerosis (5%)

✓ E. Tubular re-epithelization (75%)

Omitted
Correct answer

75%
Answered correctly

05 secs
Time Spent

05/02/2020
Last Updated

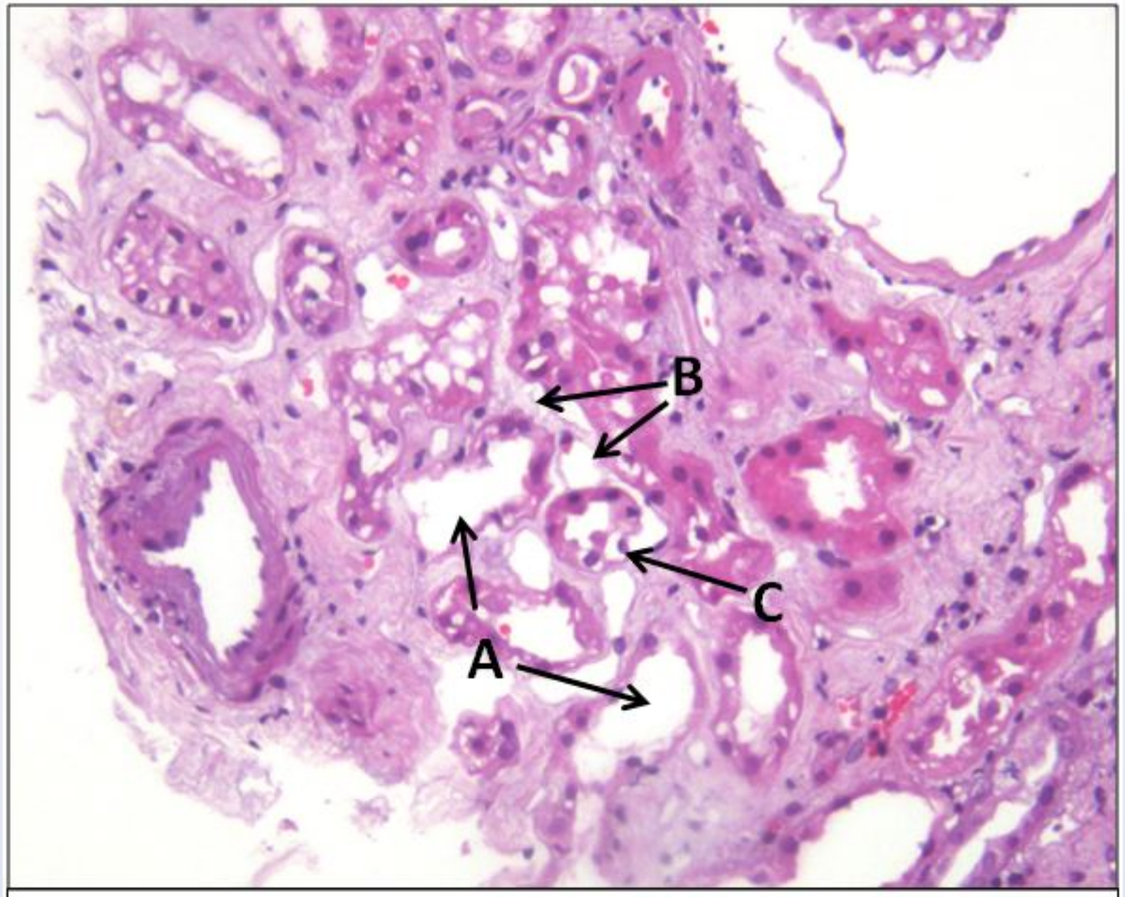

Acute tubular necrosis, H&E stain.
(A) Loss of columnar epithelium, denudation of basement membrane; (B) interstitial edema; (C) epithelial cell vacuolization.

This patient has ischemic **acute tubular necrosis** (ATN) as a result of hypotension from hemorrhage. The clinical course of ATN may be divided into the initiation, maintenance (oliguric), and recovery phases.

This patient has ischemic **acute tubular necrosis** (ATN) as a result of hypotension from hemorrhage. The clinical course of ATN may be divided into the initiation, maintenance (oliguric), and recovery phases.

1. The **initiation phase** corresponds with the original ischemic or toxic insult and lasts approximately 24-36 hours. During this phase, only a slight decrease in urine output is present as renal tubular cell damage begins.
2. During the **maintenance phase**, tubular damage is fully established, resulting in oliguria, fluid overload, and electrolyte abnormalities (eg, hyperkalemia, metabolic acidosis). This phase usually lasts 1-2 weeks, during which the glomerular filtration rate remains well below normal with a corresponding rise in serum creatinine. Light microscopy shows tubular epithelial necrosis, denudation of the tubular basement membrane, and casts containing degenerating cells and debris.
3. The **recovery phase** is characterized by the re-epithelization of tubules. The glomerular filtration rate recovers relatively quickly as the tubules clear of casts and debris. However, the tubular cells recover more gradually, resulting in transient polyuria and loss of electrolytes due to impaired tubular resorption and decreased renal concentrating ability. The majority of patients eventually have complete restoration of renal function.

(Choices A, B, and D) Diffuse mesangial sclerosis results in infantile nephrotic syndrome, whereas focal segmental glomerulosclerosis causes nephrotic syndrome in adolescents and adults and can be related to drug use (eg, heroin). Glomerular epithelial proliferation occurs in crescentic glomerulonephritis and diabetic nephropathy, among other diseases. These findings are not common in ATN.

(Choice C) Focal interstitial fibrosis causing medullary scarring and atrophy may be seen in a small number of patients, especially when ATN is accompanied by disruption of the tubular basement membrane. It is not, however, the most common outcome of ATN.

Educational objective:
Most patients with acute tubular necrosis (ATN) experience tubular re-epithelization and regain renal function. However, when ATN is associated with multiorgan failure, renal function may be permanently impaired; in such patients, foci of interstitial scarring can be seen on light microscopy.

Pathology	Renal, Urinary Systems & Electrolytes	Acute kidney injury
Subject	System	Topic

Settings

1
2
3
4
5
6
7
8
9
10
11
12
13
14
15
16
17
18
19
20
21
22
23
24
25
26
27
28
29
30

Item 27 of 40
Question Id: 1053

Mark | Previous | Next | Full Screen | Tutorial | Lab Values | Notes | Calculator | Reverse Color | Text Zoom | Settings

Exhibit Display

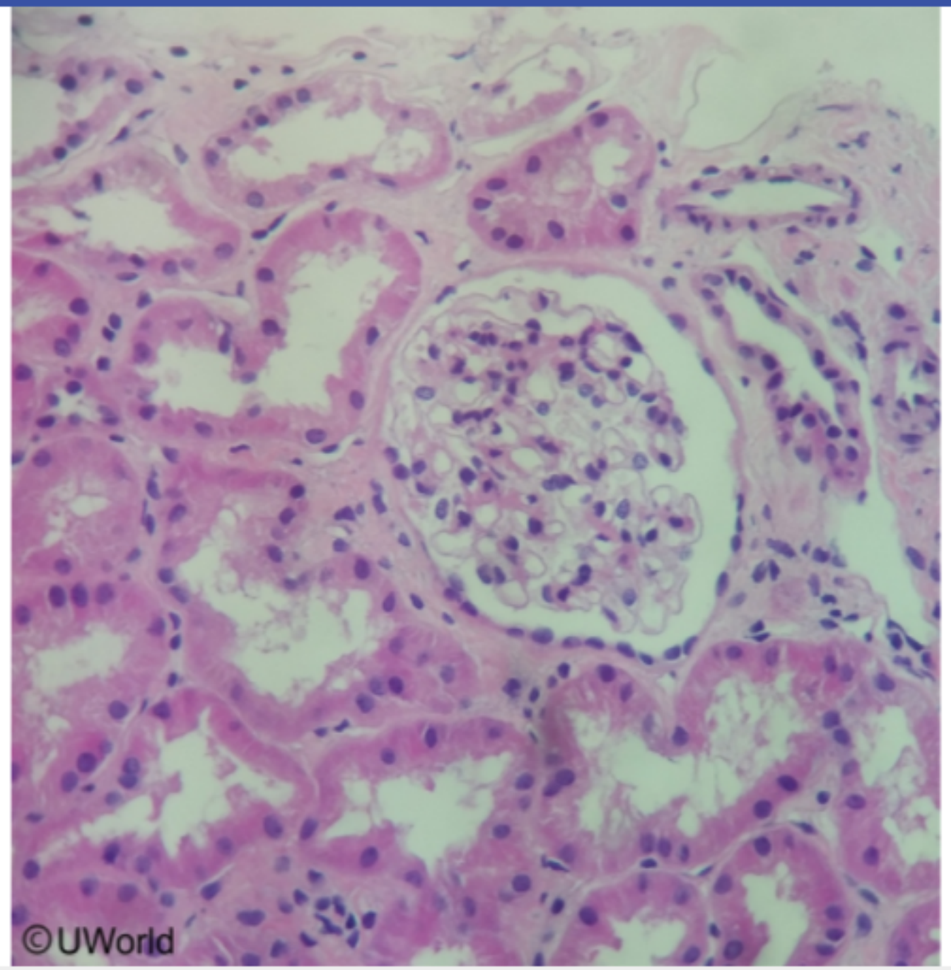

Zoom In | Zoom Out | Reset | Add To New Card | Existing Card

Block Time Remaining: 00:05:31
TUTOR

2 | Feedback | Suspend | End Block

Settings

1
2
3
4
5
6
7
8
9
10
11
12
13
14
15
16
17
18
19
20
21
22
23
24
25
26
27
28
29
30

Item 27 of 40
Question Id: 1053

Mark | Previous | Next | Full Screen | Tutorial | Lab Values | Notes | Calculator | Reverse Color | Text Zoom | Settings

Exhibit Display

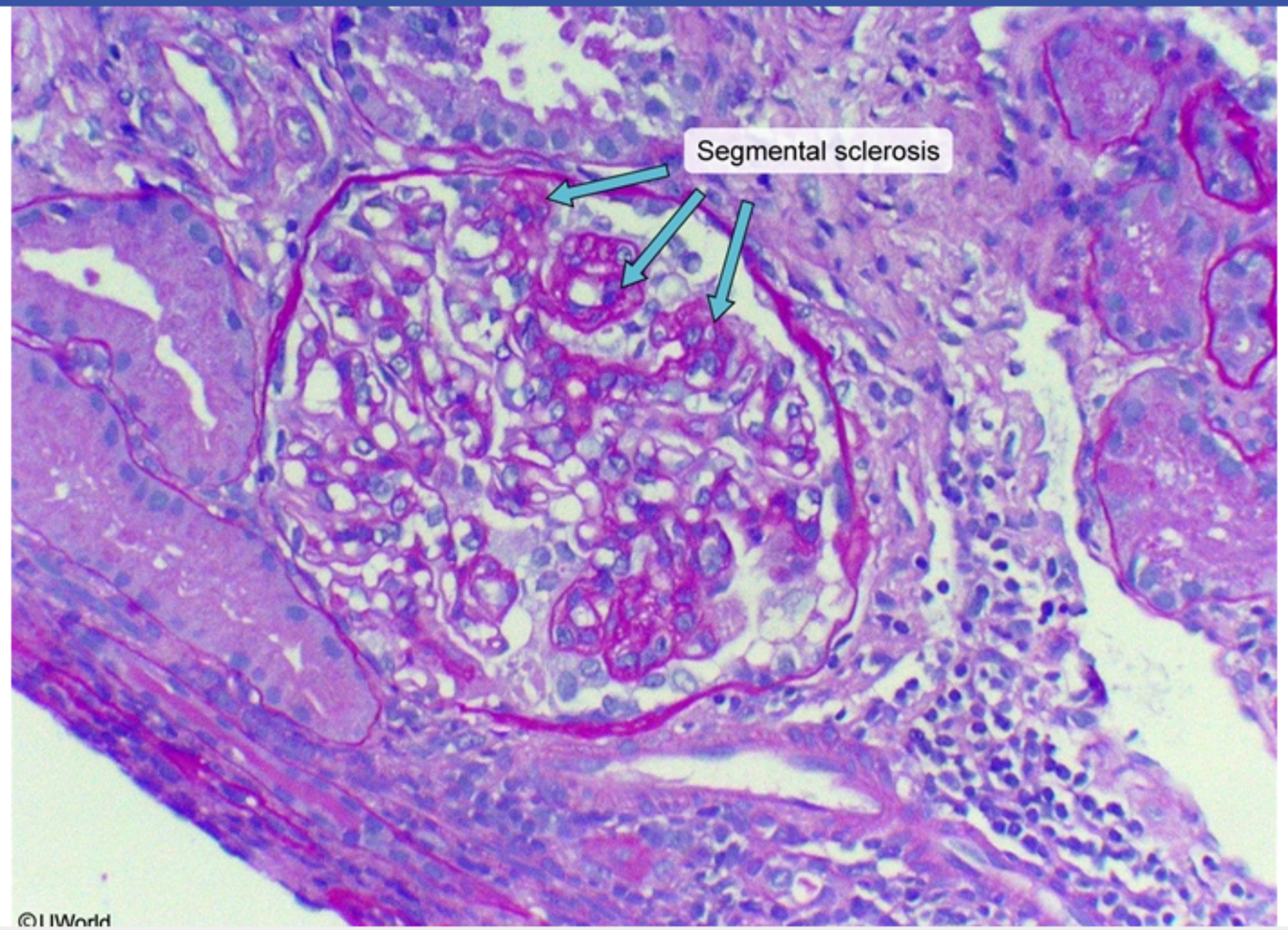

Zoom In | Zoom Out | Reset | Add To New Card | Existing Card

Block Time Remaining: 00:05:31
TUTOR

2 | Feedback | Suspend | End Block

Exhibit Display

Crescentic glomerulonephritis

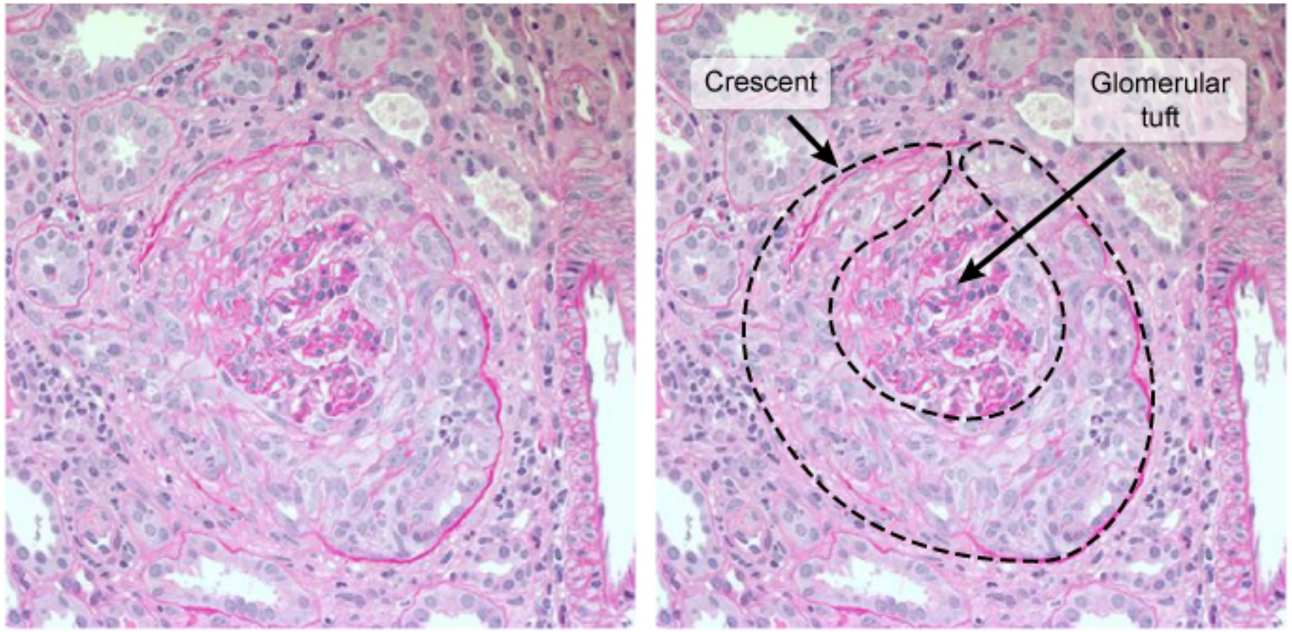

©UWorld

Zoom In | Zoom Out | Reset | Add To New Card | Existing Card

A 63-year-old man comes to the emergency department due to fever and loss of appetite. He also has chest pain with deep breaths. The patient has never had regular medical care and his medical history is unknown. He has smoked half a pack of cigarettes daily for 30 years. Laboratory evaluation shows a hematocrit of 56%. Chest imaging shows multiple round lesions in both lungs. Biopsy of one of the lesions reveals the findings shown below.

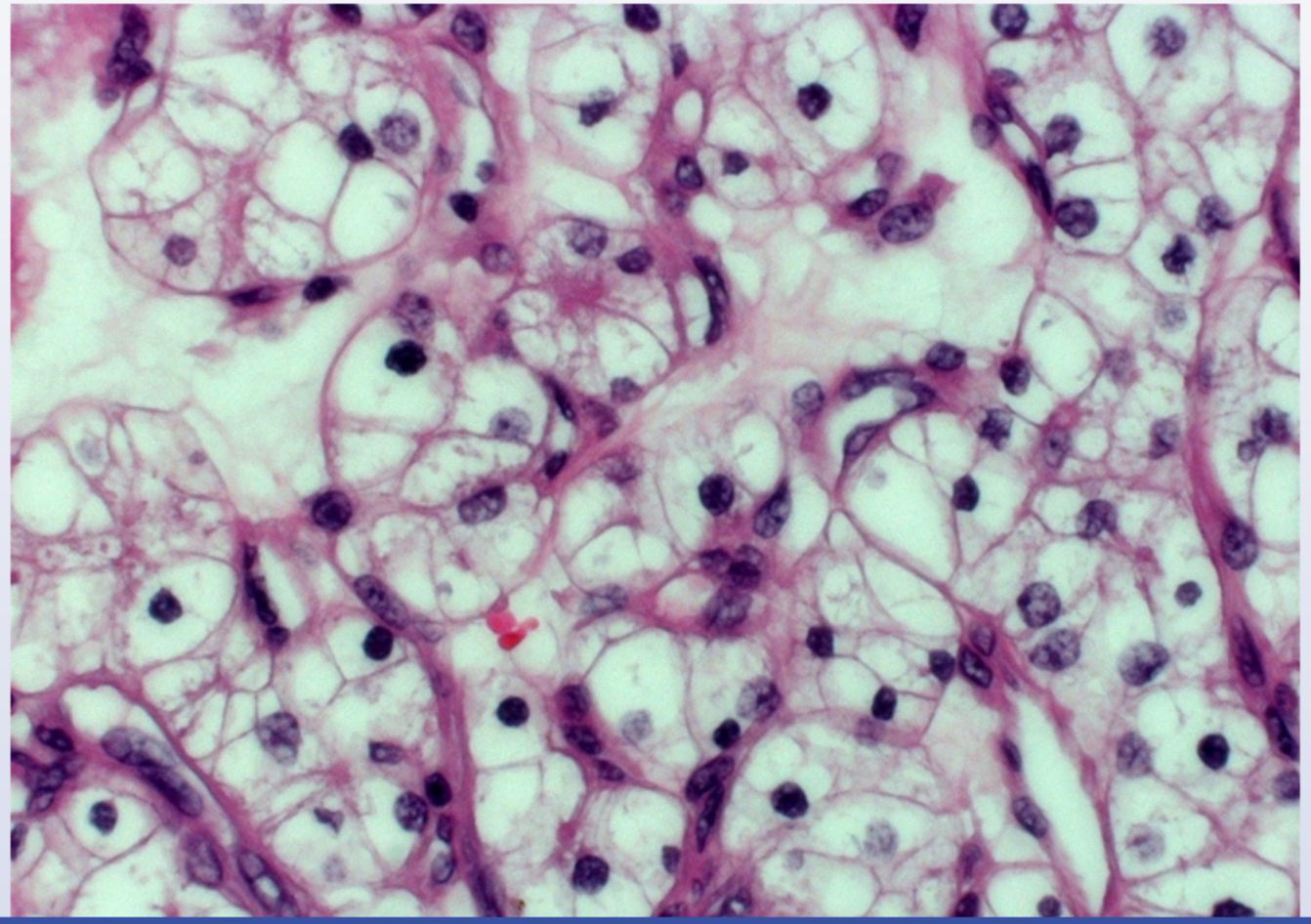

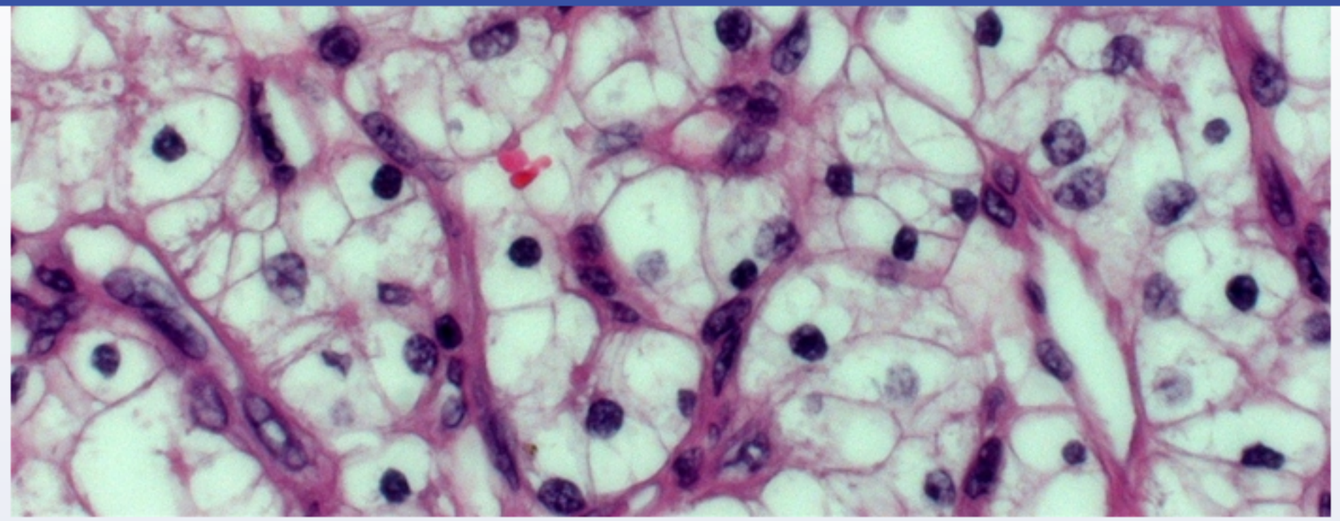

This patient's metastatic disease most likely originated from which of the following organs?

- A. Bone
- B. Brain
- C. Colon
- D. Kidney
- E. Stomach
- F. Testis

Submit

1 2 3 4 5 6 7 8 9 10 11 12 13 14 15 16 17 18 19 20 21 22 23 24 25 26 27 28 29 30

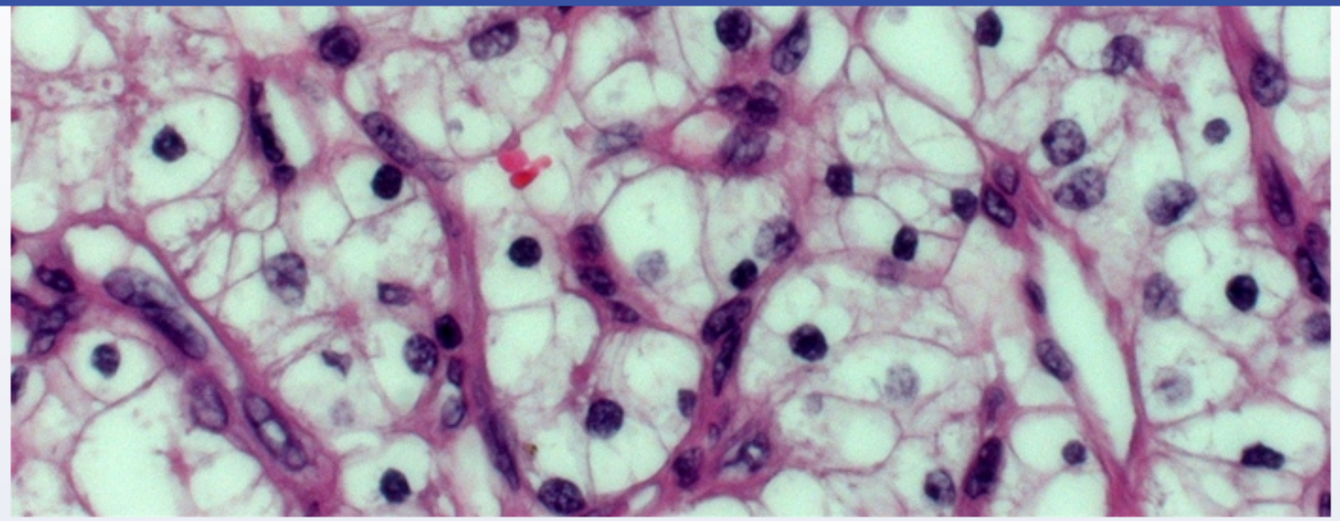

This patient's metastatic disease most likely originated from which of the following organs?

- A. Bone (5%)
- B. Brain (1%)
- C. Colon (8%)
- ✓ D. Kidney (75%)
- E. Stomach (5%)
- F. Testis (3%)

Omitted
Correct answer

75%
Answered correctly

04 secs
Time Spent

02/22/2020
Last Updated

Renal cell carcinoma	
Common presentation	• Asymptomatic (most common) • Hematuria, flank pain, palpable abdominal mass
Histopathology (clear cell)	• Rounded polygonal or cuboidal cells • Abundant clear or yellow cytoplasm
Common metastatic site	• Lungs ("cannonball metastases") • Bone (osteolytic)
Paraneoplastic syndromes	• Polycythemia (erythropoietin production) • Hypercalcemia (parathyroid hormone-related peptide production) • Hormone production (eg, ACTH, renin)

This patient has fevers, anorexia, and polycythemia. His evaluation shows multiple round lung lesions with histopathology revealing rounded polygonal cells with **abundant clear cytoplasm**. This presentation is consistent with metastatic clear cell carcinoma, the most common subtype of **renal cell carcinoma** (RCC). The cytoplasm appears clear due to the high glycogen and lipid content of the tumor. For the same reason, this neoplasm is often golden-yellow on macroscopic examination.

Patients with RCC are often asymptomatic; the classic triad of hematuria, flank pain, and palpable abdominal mass occur together in less than 10% of cases, often late in the course of the disease. **Nonspecific symptoms** such as fever and weight loss are more common. Paraneoplastic syndromes, including polycythemia (constitutive secretion of erythropoietin) and hypercalcemia (synthesis of parathyroid hormone-related protein), can also occur.

Renal cell carcinoma is often **detected incidentally** since localizing symptoms only develop in advanced disease; metastases are often discovered earlier than the primary neoplasm. RCC most commonly **metastasizes to the lungs**, where it often presents as large, rounded, well-circumscribed "cannonball metastases". Osteolytic bone lesions and liver metastases also occur frequently.

(Choice A) Osteosarcoma frequently metastasizes to the lungs, but most patients have localized pain at the primary site (eg, distal femur) and

1 2 3 4 5 6 7 8 9 10 11 12 13 14 15 16 17 18 19 20 21 22 23 24 25 26 27 28 29 30

10% of cases, often late in the course of the disease. **Nonspecific symptoms** such as fever and weight loss are more common. Paraneoplastic syndromes, including polycythemia (constitutive secretion of erythropoietin) and hypercalcemia (synthesis of parathyroid hormone-related protein), can also occur.

Renal cell carcinoma is often **detected incidentally** since localizing symptoms only develop in advanced disease; metastases are often discovered earlier than the primary neoplasm. RCC most commonly **metastasizes to the lungs**, where it often presents as large, rounded, well-circumscribed "cannonball metastases". Osteolytic bone lesions and liver metastases also occur frequently.

(Choice A) Osteosarcoma frequently metastasizes to the lungs, but most patients have localized pain at the primary site (eg, distal femur) and polycythemia is unexpected. Histologically, spindle cells with osteoid matrix production would be seen.

(Choice B) Primary brain neoplasms usually metastasize within the CNS, although rarely they can present with metastases outside the nervous system. These are not associated with polycythemia; histology varies by malignancy.

(Choices C and E) Colon and stomach cancers commonly metastasize to the lungs. Microscopy of signet cell carcinoma of the stomach demonstrates clear cytoplasm and eccentric nuclei (resembling a signet ring), whereas colon cancer forms glands and tubules. However, patients typically develop anemia due to occult bleeding, not polycythemia.

(Choice F) Testicular cancer also commonly metastasizes to the lung, but patients typically have a testicular mass. β-hCG or alpha-fetoprotein are often elevated; however, hematocrit elevations are unexpected. Histology varies by malignancy.

Educational objective:
Clear cell carcinoma is the most common subtype of renal cell carcinoma and is composed of large, rounded, or polygonal cells with clear cytoplasm. These tumors are often detected incidentally at an advanced stage; the lung is the most common site for metastasis, followed by osteolytic bone and liver.

Pathology	Renal, Urinary Systems & Electrolytes	Renal cell carcinoma
Subject	System	Topic

Copyright © UWorld. All rights reserved.

Settings

1
2
3
4
5
6
7
8
9
10
11
12
13
14
15
16
17
18
19
20
21
22
23
24
25
26
27
28
29
30

Item 28 of 40
Question Id: 818

Mark | Previous | Next | Full Screen | Tutorial | Lab Values | Notes | Calculator | Reverse Color | Text Zoom | Settings

10% of cases, often late in the course of the disease. **Nonspecific symptoms** such as fever and weight loss are more common. Paraneoplastic

Exhibit Display

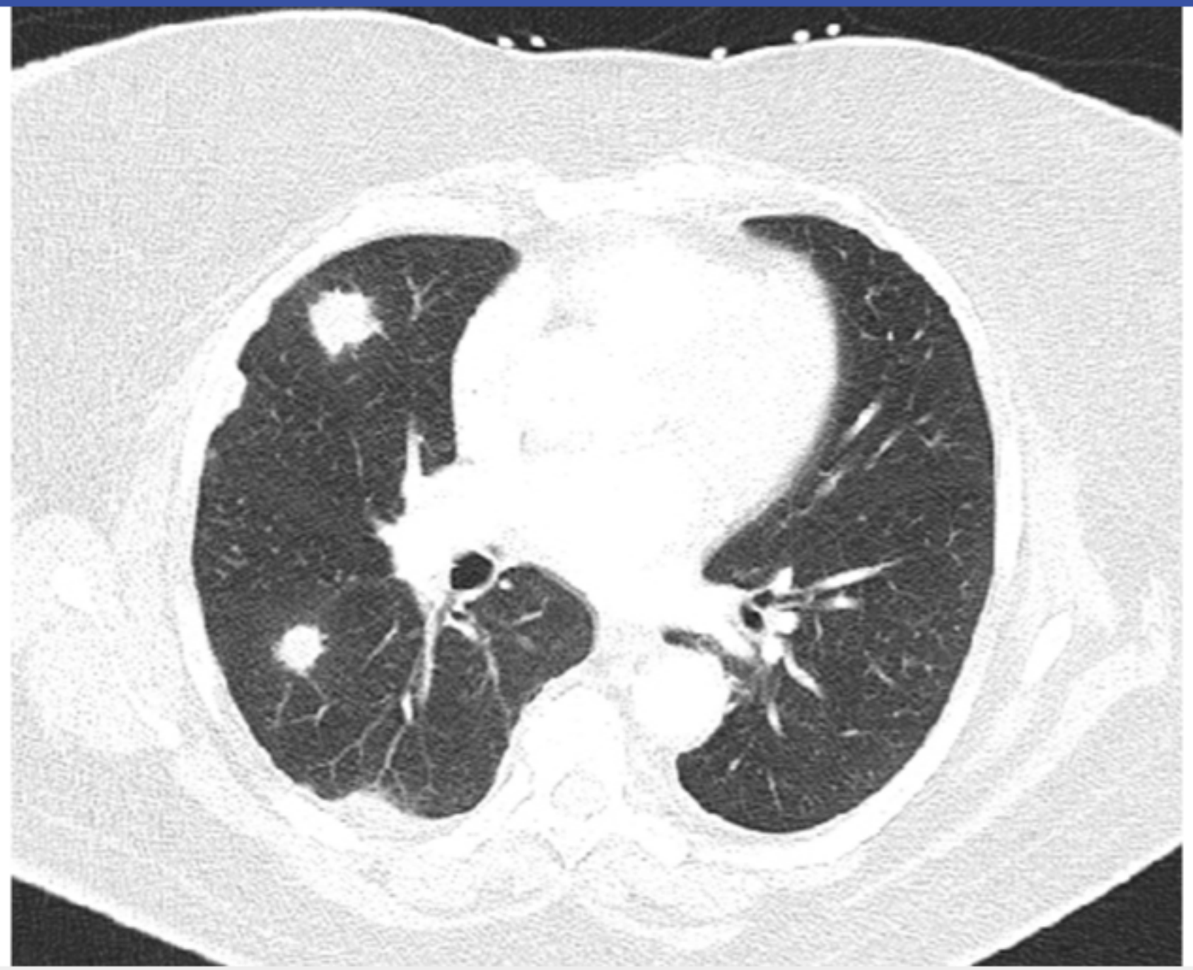

Zoom In | Zoom Out | Reset | Add To New Card | Existing Card

Block Time Remaining: 00:05:35
TUTOR

7 | Feedback | Suspend | End Block

1 2 3 4 5 6 7 8 9 10 11 12 13 14 15 16 17 18 19 20 21 22 23 24 25 26 27 28 29 30

10% of cases, often late in the course of the disease. **Nonspecific symptoms** such as fever and weight loss are more common. Paraneoplastic

Exhibit Display

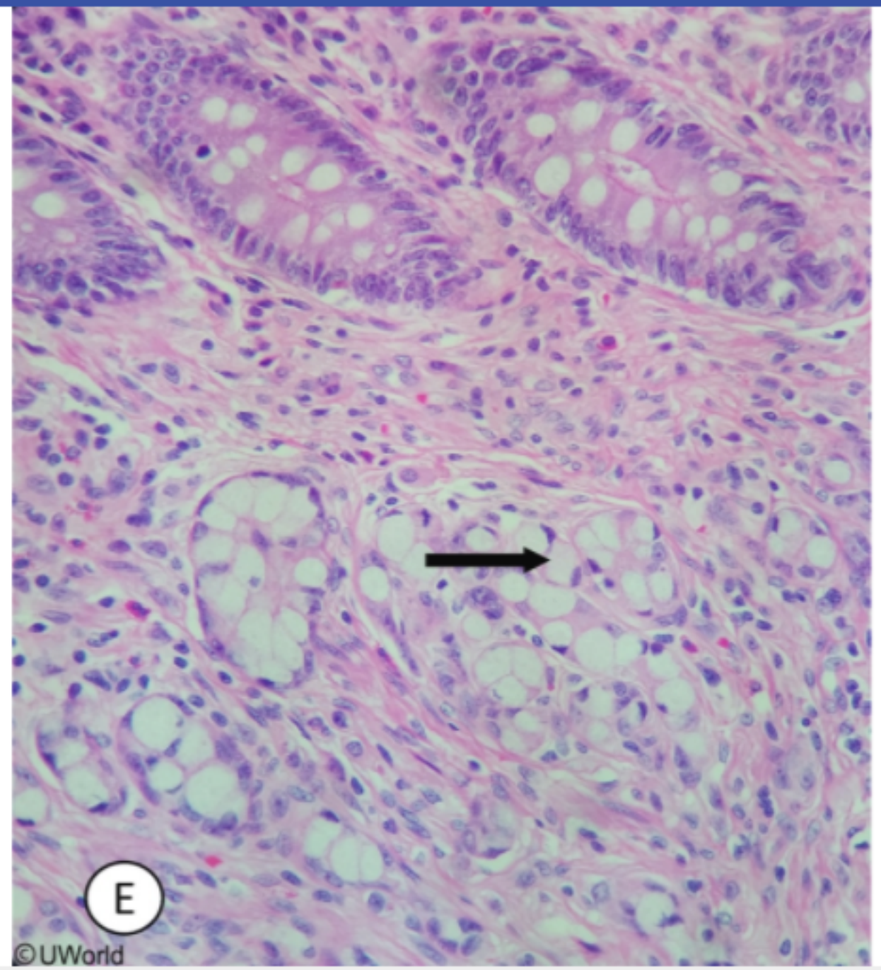

Zoom In | Zoom Out | Reset | Add To New Card | Existing Card

Settings

1 2 3 4 5 6 7 8 9 10 11 12 13 14 15 16 17 18 19 20 21 22 23 24 25 26 27 28 29 30

Item 28 of 40
Question Id: 818

Mark | Previous | Next | Full Screen | Tutorial | Lab Values | Notes | Calculator | Reverse Color | Text Zoom | Settings

10% of cases, often late in the course of the disease. **Nonspecific symptoms** such as fever and weight loss are more common. Paraneoplastic

Exhibit Display

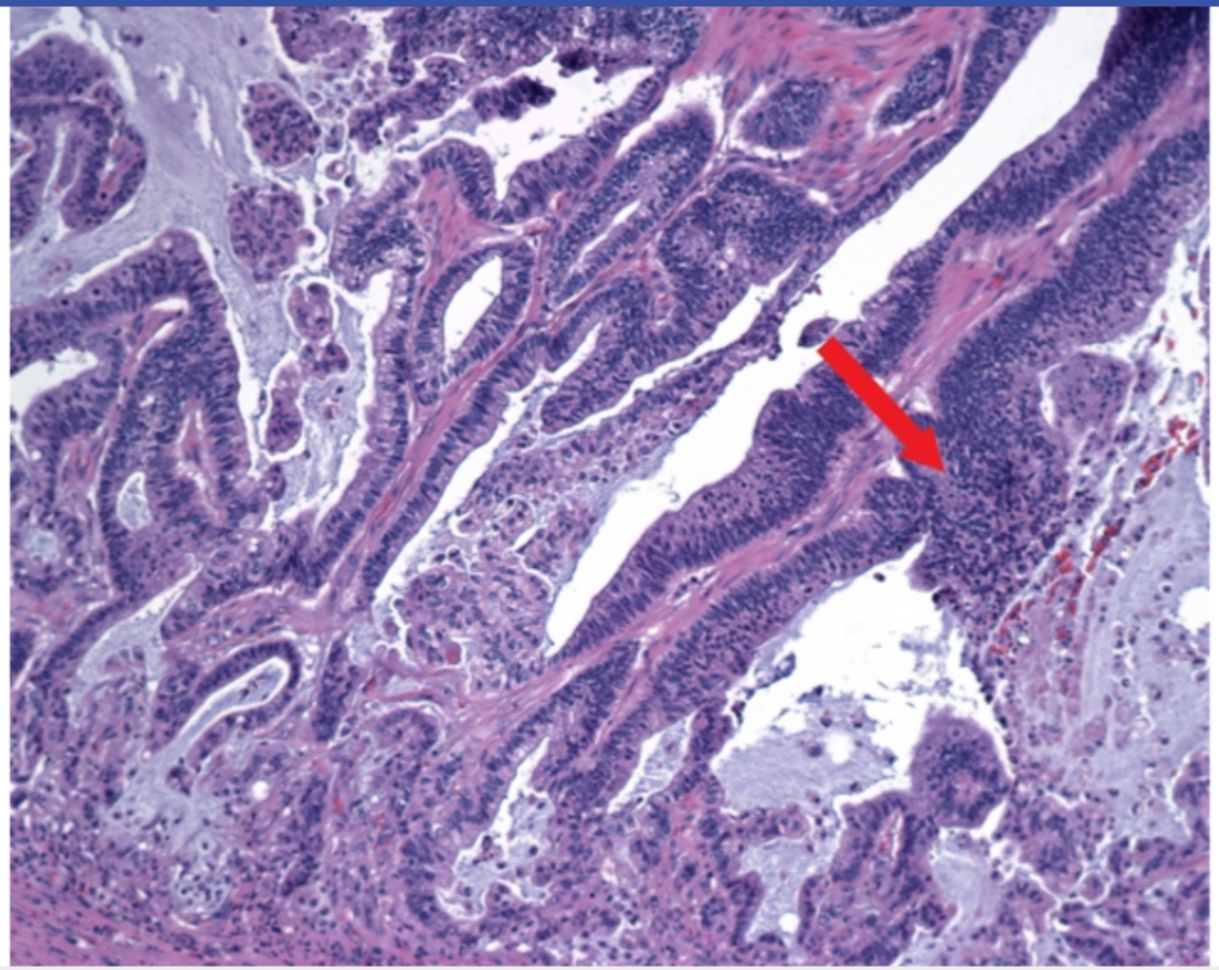

Zoom In | Zoom Out | Reset | Add To New Card | Existing Card

Block Time Remaining: 00:05:35
TUTOR

7 | Feedback | Suspend | End Block

A 15-year-old girl is brought to the clinic for evaluation of swelling around her eyes that developed over the past week. The patient is a cheerleader, and she had been taking ibuprofen daily for the last 3 months for various sprains and aches after practice. She has no chronic medical conditions. Vital signs are normal. On physical examination, there is moderate periorbital edema with bilateral lower extremity pitting edema. Serum creatinine is 0.5 mg/dL and serum albumin is 2.1 g/dL. Urinalysis shows 4+ protein and negative blood. Multiple regions of the kidney are biopsied, and a representative image is shown below:

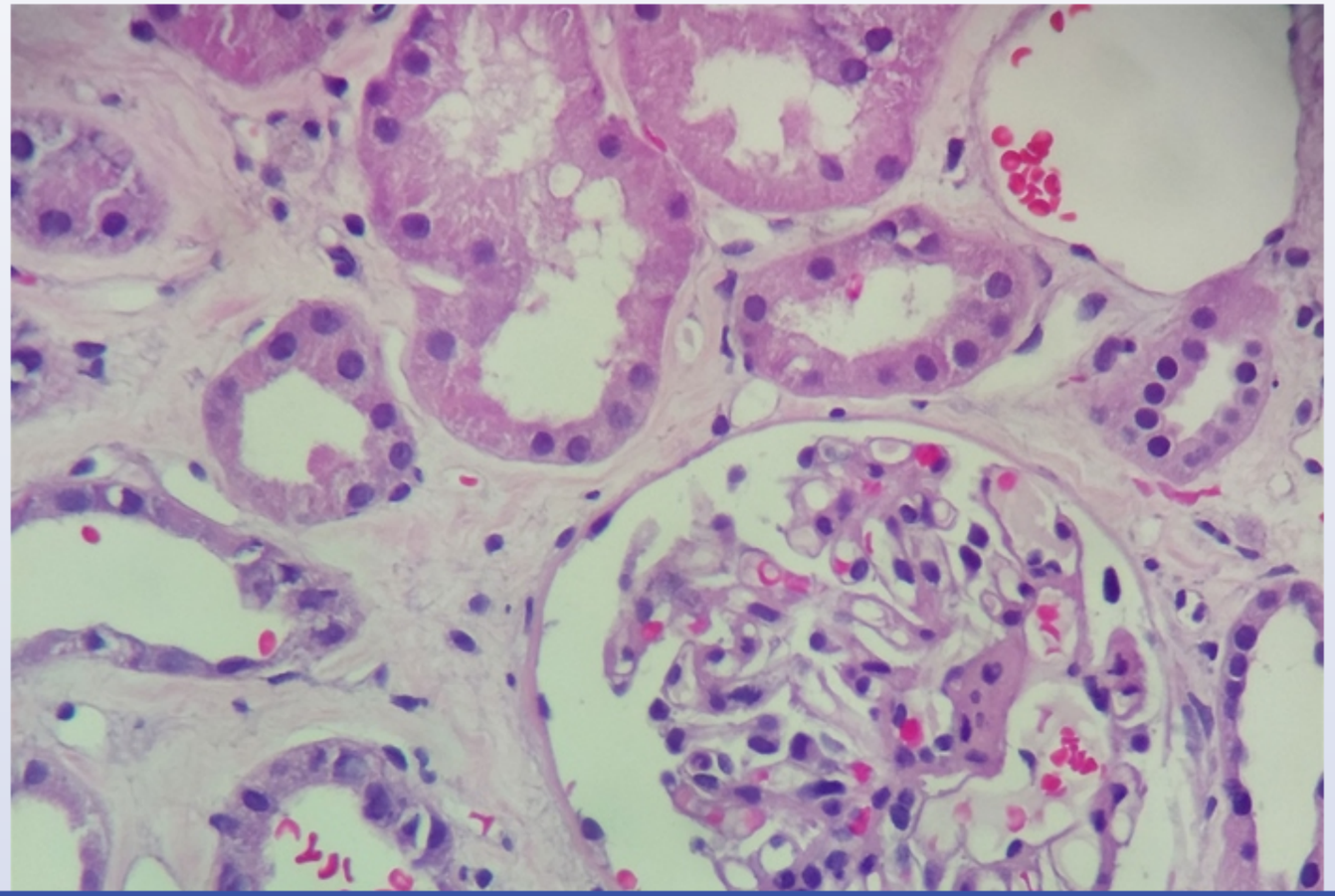

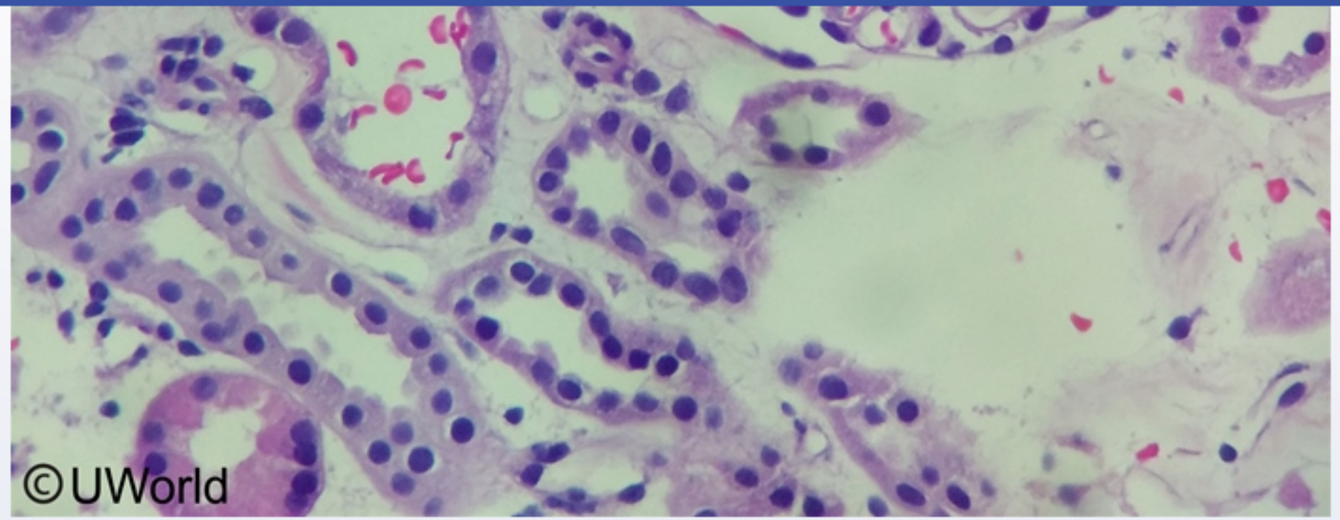

Which of the following is the most likely diagnosis?

- A. Acute interstitial nephritis
- B. Crescentic glomerulonephritis
- C. Focal segmental glomerulosclerosis
- D. Membranous nephropathy
- E. Minimal change disease
- F. Poststreptococcal glomerulonephritis

Submit

1 2 3 4 5 6 7 8 9 10 11 12 13 14 15 16 17 18 19 20 21 22 23 24 25 26 27 28 29 30

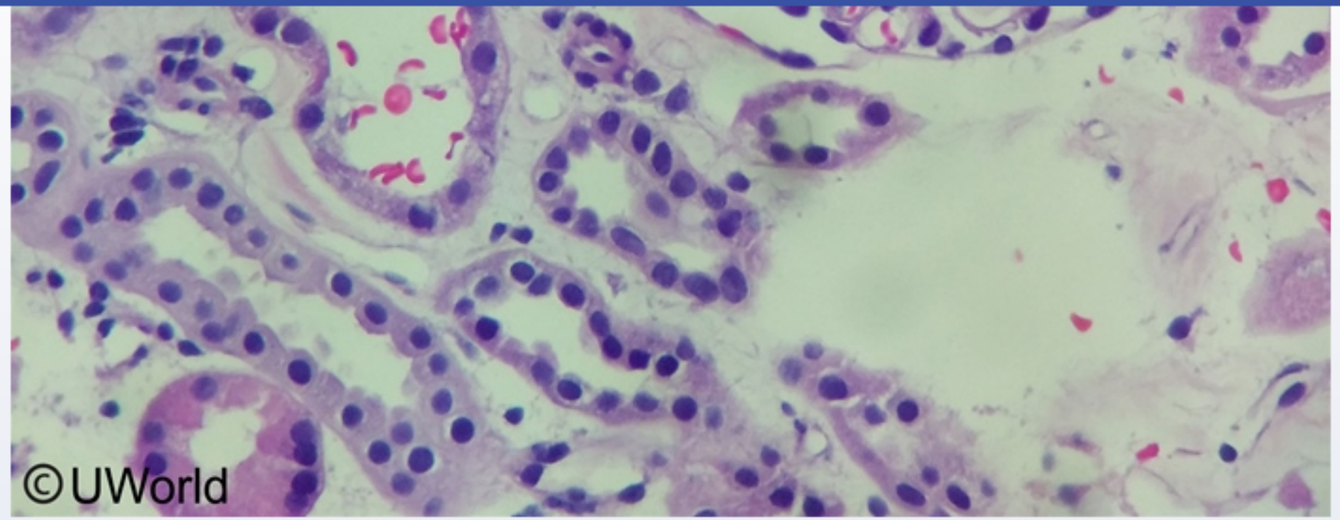

Which of the following is the most likely diagnosis?

- A. Acute interstitial nephritis (23%)
- B. Crescentic glomerulonephritis (1%)
- C. Focal segmental glomerulosclerosis (10%)
- D. Membranous nephropathy (19%)
- ✓ E. Minimal change disease (43%)
- F. Poststreptococcal glomerulonephritis (1%)

Omitted
Correct answer

43%
Answered correctly

05 secs
Time Spent

02/18/2020
Last Updated

Explanation

Minimal change disease	
Epidemiology	• Most common cause of nephrotic syndrome in children • Median age 2-3
Pathogenesis	• T cell–mediated injury to podocytes • Production of a glomerular permeability factor
Clinical features	• Edema, frothy urine • Proteinuria, hypoalbuminemia, hyperlipidemia
Diagnosis	• LM: normal glomeruli • IM: no immune deposits • EM: diffuse podocyte foot process effacement

EM = electron microscopy; **IM** = immunofluorescence microscopy; **LM** = light microcopy.

This patient with edema, proteinuria, and hypoalbuminemia has nephrotic syndrome. The histopathology demonstrating normal glomeruli on light microscopy (LM) suggests a diagnosis of **minimal change disease** (MCD). MCD is the most common cause of nephrotic syndrome in children. It is often idiopathic but may be triggered by drugs (eg, **nonsteroidal anti-inflammatory drugs** [NSAIDs], as in this patient), immunizations, or malignancy (eg, Hodgkin lymphoma). T-cell dysfunction results in the production of a glomerular permeability factor (possibly IL-13), which damages podocytes and decreases the anionic charge of the glomerular basement membrane (GBM), allowing for selective loss of albumin in the urine.

Clinical features include acute weight gain, diffuse edema, and "frothy urine" due to heavy proteinuria. Renal biopsy demonstrates **normal glomeruli on LM**, with no immunoglobulin or complement deposits visible on immunofluorescent microscopy. However, electron microscopy shows diffuse effacement and fusion of podocyte foot process.

(Choice A) Acute interstitial nephritis often occurs after initiation of new drugs (eg, NSAIDS, diuretics) but causes acute kidney injury with white

This patient with edema, proteinuria, and hypoalbuminemia has nephrotic syndrome. The histopathology demonstrating normal glomeruli on light microscopy (LM) suggests a diagnosis of **minimal change disease** (MCD). MCD is the most common cause of nephrotic syndrome in children. It is often idiopathic but may be triggered by drugs (eg, **nonsteroidal anti-inflammatory drugs** [NSAIDs], as in this patient), immunizations, or malignancy (eg, Hodgkin lymphoma). T-cell dysfunction results in the production of a glomerular permeability factor (possibly IL-13), which damages podocytes and decreases the anionic charge of the glomerular basement membrane (GBM), allowing for selective loss of albumin in the urine.

Clinical features include acute weight gain, diffuse edema, and "frothy urine" due to heavy proteinuria. Renal biopsy demonstrates **normal glomeruli on LM**, with no immunoglobulin or complement deposits visible on immunofluorescent microscopy. However, electron microscopy shows diffuse effacement and fusion of podocyte foot process.

(Choice A) Acute interstitial nephritis often occurs after initiation of new drugs (eg, NSAIDS, diuretics) but causes acute kidney injury with white blood cell casts on urinalysis; heavy proteinuria is unexpected. Although the glomeruli are often normal, patchy tubular necrosis will be seen on LM.

(Choices B and F) Crescentic glomerulonephritis and poststreptococcal glomerulonephritis cause nephritic syndrome (eg, hematuria, red blood cell casts, hypertension). Crescentic glomerulonephritis occurs in multiple renal diseases (eg, Goodpasture disease, microscopic polyangiitis) and demonstrates hypercellular crescents composed of parietal and inflammatory cells. Poststreptococcal glomerulonephritis, which occurs 2-4 weeks after a group A streptococcal infection, demonstrates hypercellular glomeruli on LM.

(Choice C) Focal segmental glomerular sclerosis causes nephrotic syndrome and also demonstrates similar podocyte foot process effacement on electron microscopy; however, LM demonstrates sclerotic foci within the glomerulus. This disease is more common in adults and typically has a slower onset of edema and weight gain.

(Choice D) Membranous nephropathy causes nephrotic syndrome, and is associated with NSAID use, but is more common in adults. LM demonstrates glomeruli with diffuse GBM thickening.

Educational objective:
Minimal change disease is the most common cause of nephrotic syndrome in children. It is often idiopathic but may be triggered by drugs, immunizations, or malignancy. Light microscopy shows normal glomeruli, with no immunoglobulin or complement deposits on immunofluorescent

This patient with edema, proteinuria, and hypoalbuminemia has nephrotic syndrome. The histopathology demonstrating normal glomeruli on light microscopy (LM) suggests n. It is often idiopathic but may malignancy (eg, Hodgkin l damages podocytes and c the urine.

Clinical features include a **glomeruli on LM**, with no shows diffuse effacement

(Choice A) Acute intersti te blood cell casts on urinaly n LM.

(Choices B and F) Cresc od cell casts, hypertension). and demonstrates hypercellula eeks after a group A streptococ

(Choice C) Focal segmer t on electron microscopy; howe a slower onset of edema an

(Choice D) Membranous demonstrates glomeruli w

Educational objective:
Minimal change disease is the most common cause of nephrotic syndrome in children. It is often idiopathic but may be triggered by drugs, immunizations, or malignancy. Light microscopy shows normal glomeruli, with no immunoglobulin or complement deposits on immunofluorescent

Exhibit Display

Nephritic vs nephrotic syndrome

	Nephritic	Nephrotic
Onset	Abrupt	Insidious
GFR	Low	Normal or low
Serum albumin	Normal	Low
Edema	±	++
Hypertension	++	±
Casts	RBC casts	Fatty or none
Proteinuria	±	++
Hematuria	++	±
Pyuria	+	None

GFR = glomerular filtration rate; RBC = red blood cell.
+ = present; ++ = significant.

Add To New Card | Existing Card

Settings

1 2 3 4 5 6 7 8 9 10 11 12 13 14 15 16 17 18 19 20 21 22 23 24 25 26 27 28 29 30

Item 29 of 40
Question Id: 15355

Mark | Previous | Next | Full Screen | Tutorial | Lab Values | Notes | Calculator | Reverse Color | Text Zoom | Settings

Exhibit Display

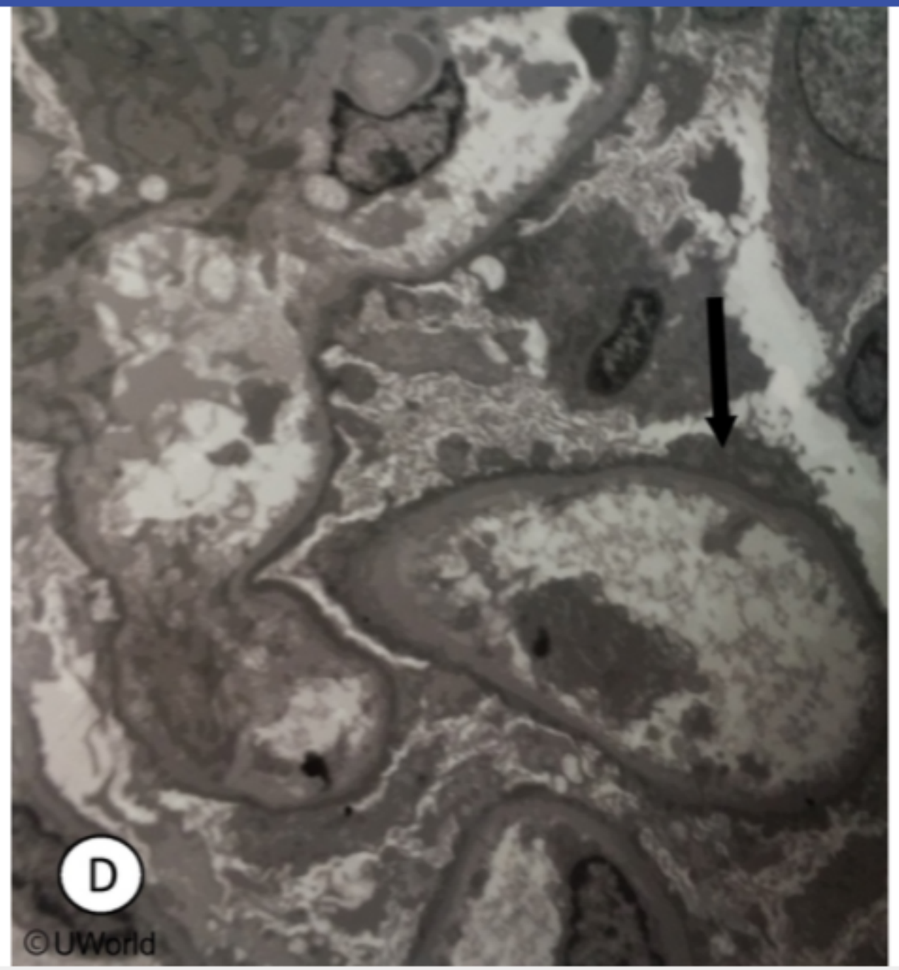

Zoom In | Zoom Out | Reset | Add To New Card | Existing Card

immunizations, or malignancy. Light microscopy shows normal glomeruli, with no immunoglobulin or complement deposits on immunofluorescent

Block Time Remaining: 00:05:40
TUTOR

3 | Feedback | Suspend | End Block

Settings

1 2 3 4 5 6 7 8 9 10 11 12 13 14 15 16 17 18 19 20 21 22 23 24 25 26 27 28 29 30

Item 29 of 40
Question Id: 15355

Mark | Previous | Next | Full Screen | Tutorial | Lab Values | Notes | Calculator | Reverse Color | Text Zoom | Settings

Exhibit Display

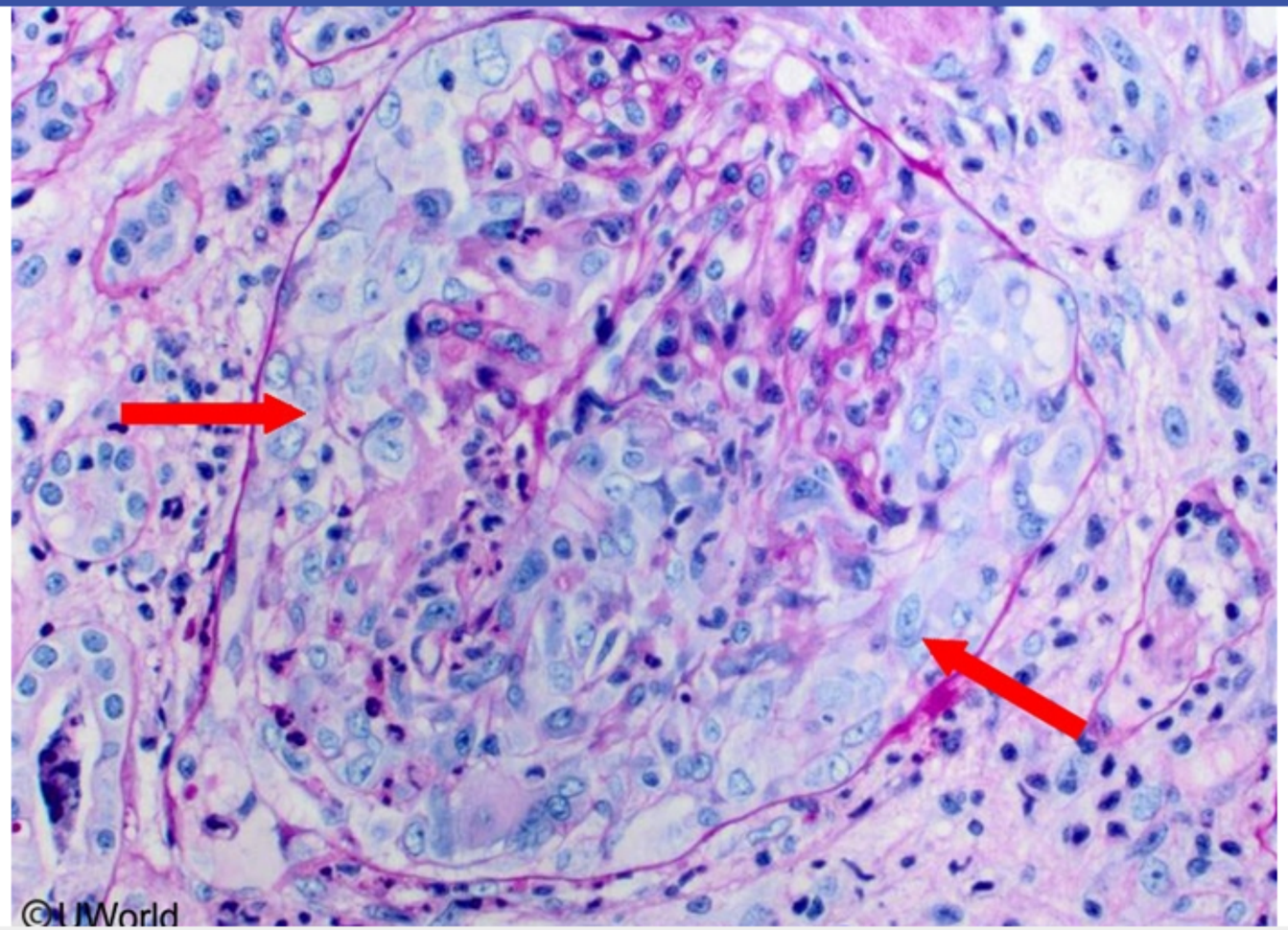

Zoom In | Zoom Out | Reset | Add To New Card | Existing Card

immunizations, or malignancy. Light microscopy shows normal glomeruli, with no immunoglobulin or complement deposits on immunofluorescent

Block Time Remaining: 00:05:40
TUTOR

3 | Feedback | Suspend | End Block

Settings

1
2
3
4
5
6
7
8
9
10
11
12
13
14
15
16
17
18
19
20
21
22
23
24
25
26
27
28
29
30

Item 29 of 40
Question Id: 15355

Mark | Previous | Next | Full Screen | Tutorial | Lab Values | Notes | Calculator | Reverse Color | Text Zoom | Settings

Exhibit Display

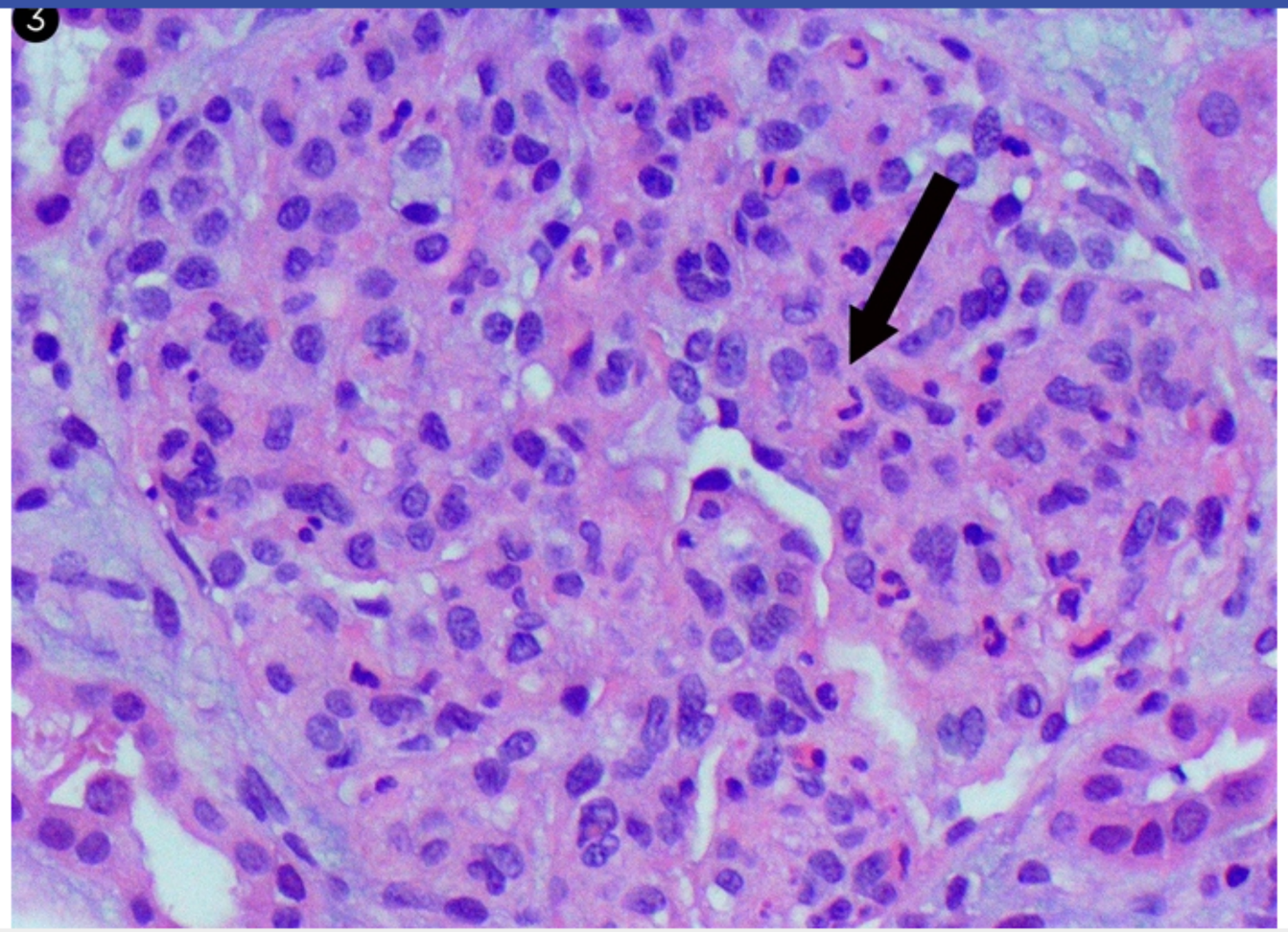

Zoom In | Zoom Out | Reset | Add To New Card | Existing Card

immunizations, or malignancy. Light microscopy shows normal glomeruli, with no immunoglobulin or complement deposits on immunofluorescent

Block Time Remaining: 00:05:40
TUTOR

3 | Feedback | Suspend | End Block

Settings

1
2
3
4
5
6
7
8
9
10
11
12
13
14
15
16
17
18
19
20
21
22
23
24
25
26
27
28
29
30

Item 29 of 40
Question Id: 15355

Mark | Previous | Next | Full Screen | Tutorial | Lab Values | Notes | Calculator | Reverse Color | Text Zoom | Settings

Exhibit Display

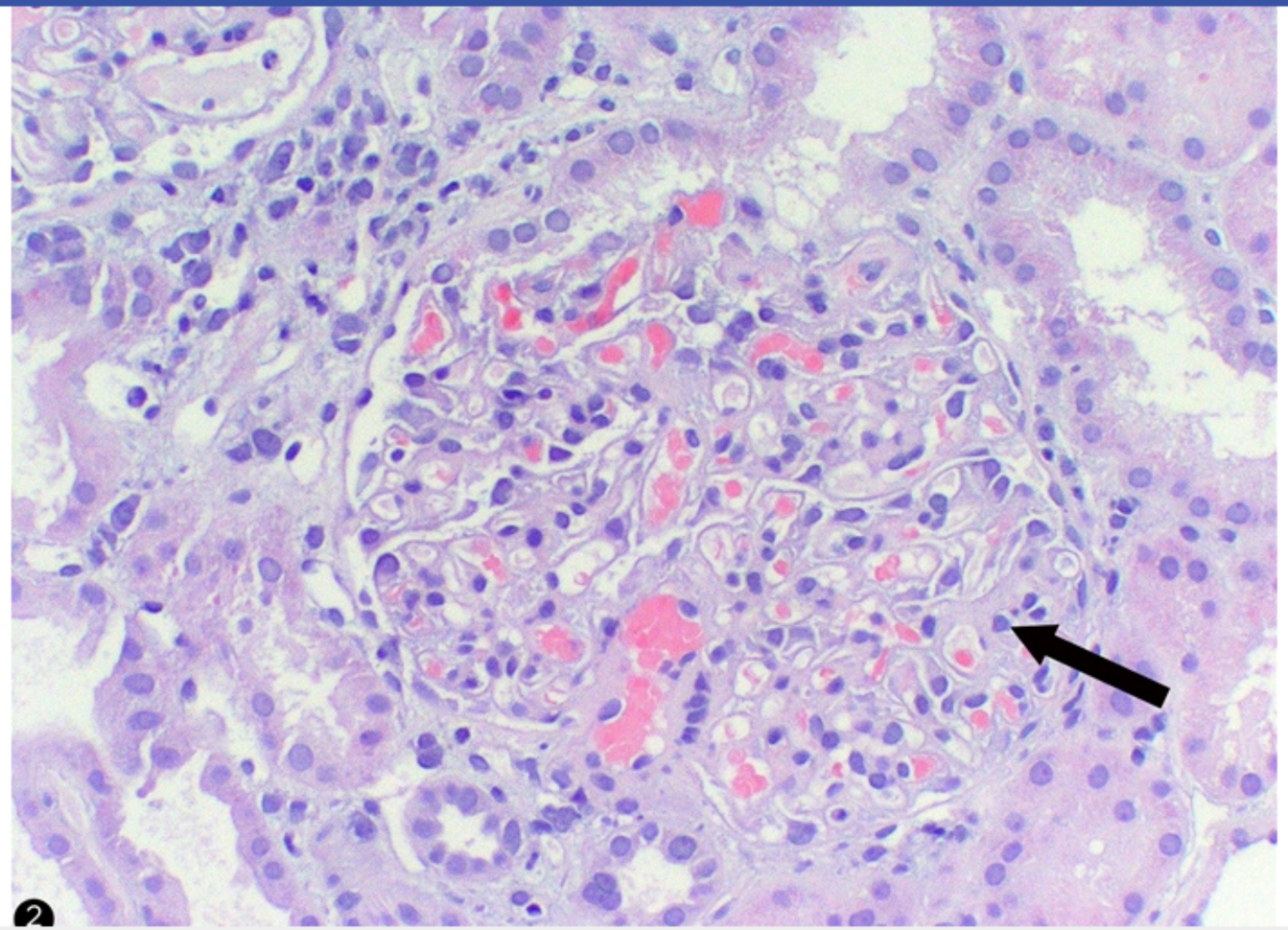

Zoom In | Zoom Out | Reset | Add To New Card | Existing Card

immunizations, or malignancy. Light microscopy shows normal glomeruli, with no immunoglobulin or complement deposits on immunofluorescent

Block Time Remaining: 00:05:40
TUTOR

3 | Feedback | Suspend | End Block

Clinical features include acute weight gain, diffuse edema, and "frothy urine" due to heavy proteinuria. Renal biopsy demonstrates **normal glomeruli on LM**, with no immunoglobulin or complement deposits visible on immunofluorescent microscopy. However, electron microscopy shows diffuse effacement and fusion of podocyte foot process.

(Choice A) Acute interstitial nephritis often occurs after initiation of new drugs (eg, NSAIDS, diuretics) but causes acute kidney injury with white blood cell casts on urinalysis; heavy proteinuria is unexpected. Although the glomeruli are often normal, patchy tubular necrosis will be seen on LM.

(Choices B and F) Crescentic glomerulonephritis and poststreptococcal glomerulonephritis cause nephritic syndrome (eg, hematuria, red blood cell casts, hypertension). Crescentic glomerulonephritis occurs in multiple renal diseases (eg, Goodpasture disease, microscopic polyangiitis) and demonstrates hypercellular crescents composed of parietal and inflammatory cells. Poststreptococcal glomerulonephritis, which occurs 2-4 weeks after a group A streptococcal infection, demonstrates hypercellular glomeruli on LM.

(Choice C) Focal segmental glomerular sclerosis causes nephrotic syndrome and also demonstrates similar podocyte foot process effacement on electron microscopy; however, LM demonstrates sclerotic foci within the glomerulus. This disease is more common in adults and typically has a slower onset of edema and weight gain.

(Choice D) Membranous nephropathy causes nephrotic syndrome, and is associated with NSAID use, but is more common in adults. LM demonstrates glomeruli with diffuse GBM thickening.

Educational objective:
Minimal change disease is the most common cause of nephrotic syndrome in children. It is often idiopathic but may be triggered by drugs, immunizations, or malignancy. Light microscopy shows normal glomeruli, with no immunoglobulin or complement deposits on immunofluorescent staining. However, electron microscopy shows diffuse podocyte foot process effacement and fusion.

Pathology	Renal, Urinary Systems & Electrolytes	Glomerular disorders
Subject	System	Topic

Copyright © UWorld. All rights reserved.

A 55-year-old man is found unresponsive on the street during a cold winter night. He is hypothermic and does not follow commands. Medical history is unavailable. Despite rewarming efforts, the patient dies in the emergency department. An autopsy is performed. Light microscopy of a section of the patient's kidney is shown on the slide below.

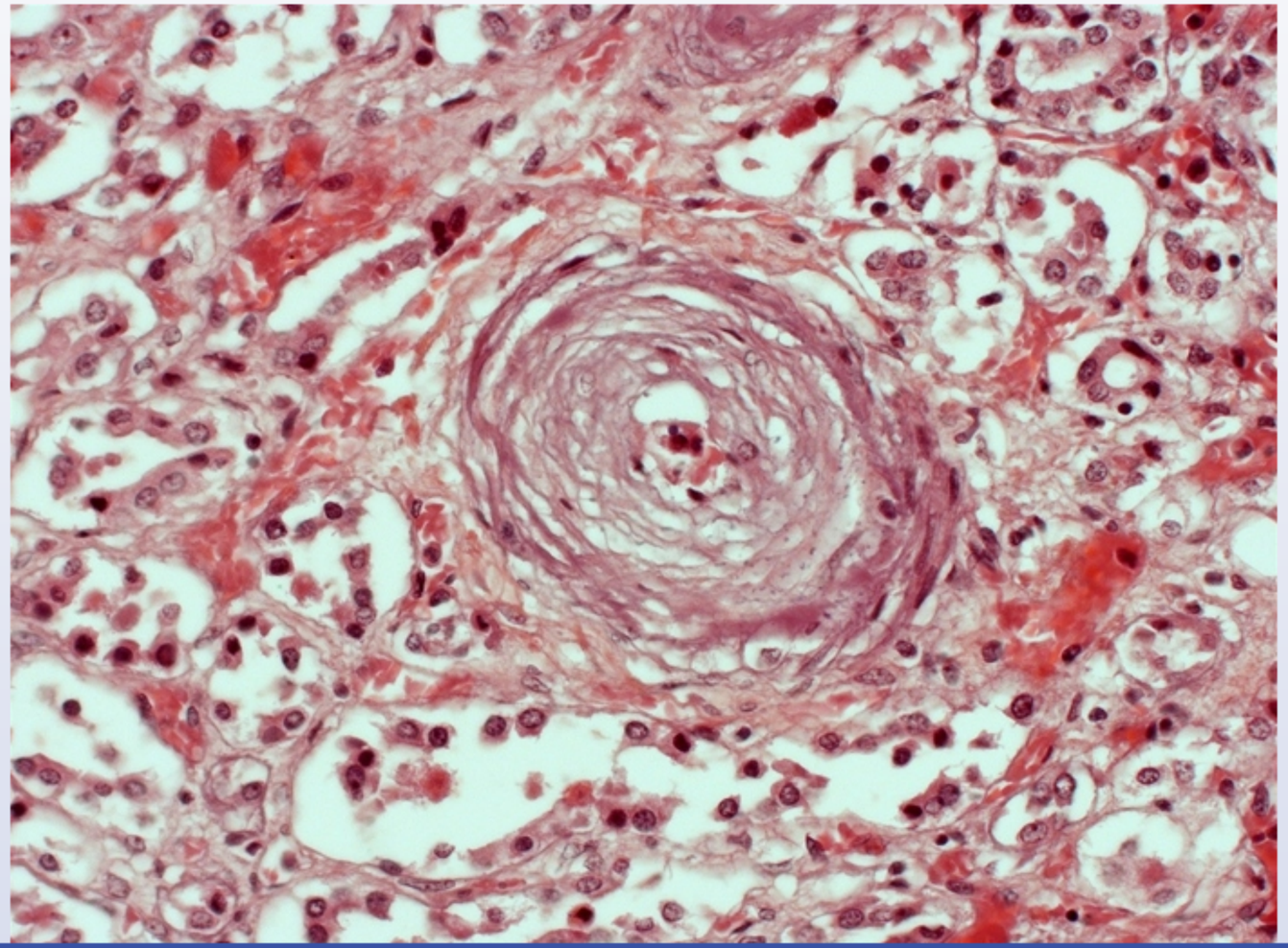

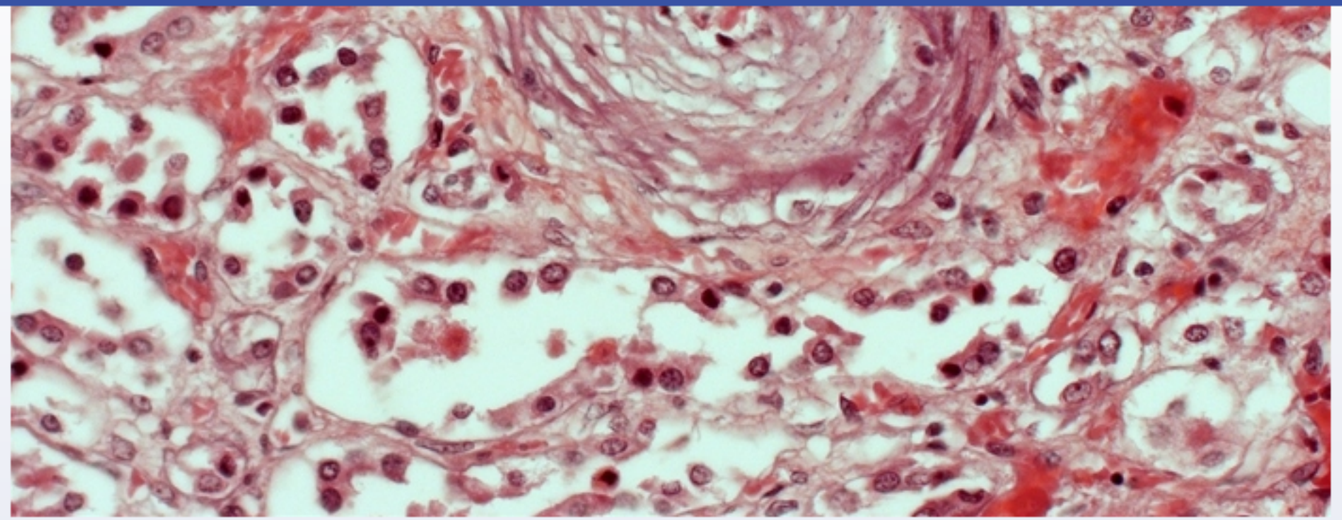

This individual's renal condition could most likely have been prevented by use of which of the following types of medication?

- A. Antibiotics
- B. Antihypertensives
- C. Antiplatelet agents
- D. Glucocorticoids
- E. Hypoglycemic agents
- F. Nonsteroidal anti-inflammatory drugs

Submit

1 2 3 4 5 6 7 8 9 10 11 12 13 14 15 16 17 18 19 20 21 22 23 24 25 26 27 28 29 30

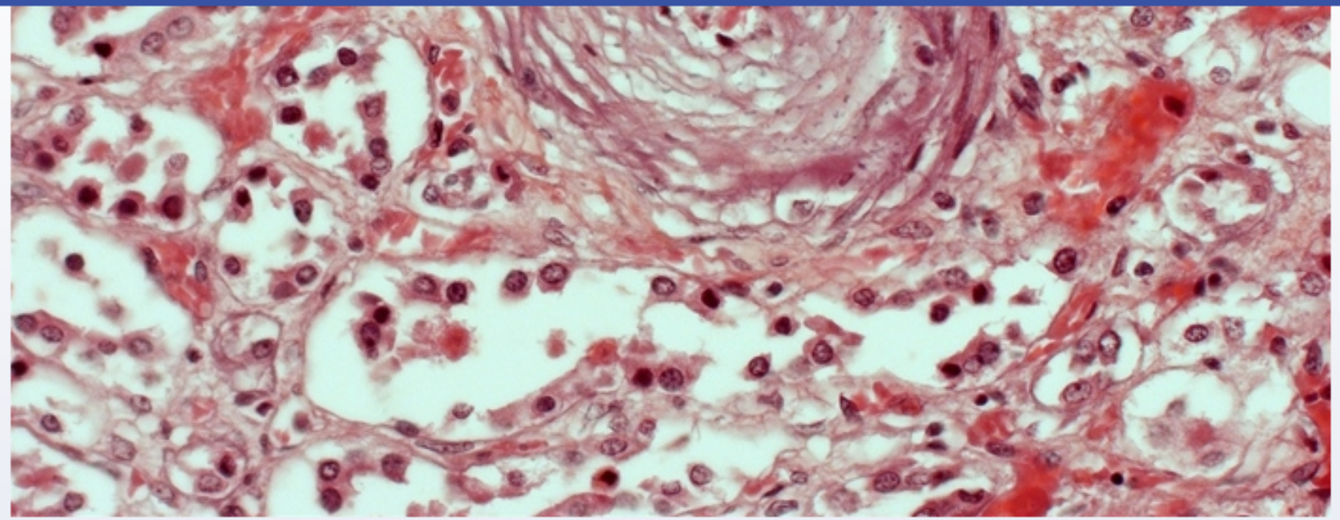

This individual's renal condition could most likely have been prevented by use of which of the following types of medication?

- A. Antibiotics (1%)
- ✓ B. Antihypertensives (82%)
- C. Antiplatelet agents (1%)
- D. Glucocorticoids (5%)
- E. Hypoglycemic agents (7%)
- F. Nonsteroidal anti-inflammatory drugs (1%)

Omitted
Correct answer

82%
Answered correctly

04 secs
Time Spent

04/28/2020
Last Updated

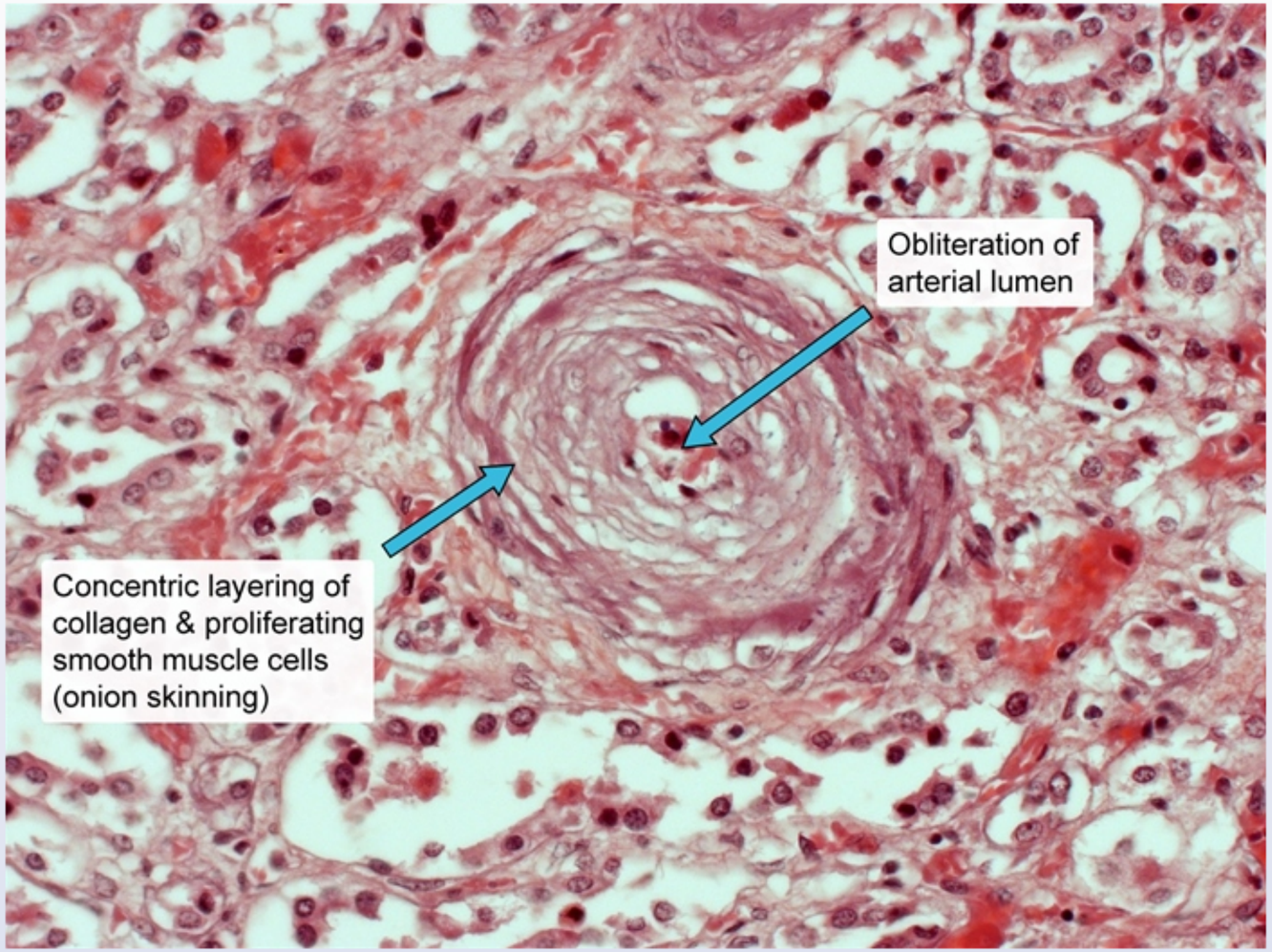

Hypertensive (malignant) nephrosclerosis is the renal manifestation of **hypertensive emergency**, a condition in which severe hypertension results in end-organ damage. Markedly elevated blood pressure causes vascular endothelial damage, leading to inflammation, cell necrosis, and extravasation of plasma proteins (eg, fibrinogen, coagulation factors). In the kidneys, this results in a characteristic set of histologic changes:

Hypertensive (malignant) nephrosclerosis is the renal manifestation of **hypertensive emergency**, a condition in which severe hypertension results in end-organ damage. Markedly elevated blood pressure causes vascular endothelial damage, leading to inflammation, cell necrosis, and extravasation of plasma proteins (eg, fibrinogen, coagulation factors). In the kidneys, this results in a characteristic set of histologic changes:

- Leakage of fibrinogen and coagulation factors through the damaged endothelium causes fibrin deposition in vessel walls, which appear as circumferential, acellular eosinophilic deposits **(fibrinoid necrosis)**.
- Over time, release of growth factors by damaged tissue stimulates the formation of concentric layers of collagen and proliferating smooth muscle cells, resulting in an "**onion skin**" appearance **(hyperplastic arteriosclerosis)** of the arteriole, as seen in this patient.

These processes result in narrowing and obliteration of the arteriolar lumens, reducing glomerular perfusion and filtration, with subsequent activation of the renin-angiotensin-aldosterone system. This maladaptation can result in a further increase in blood pressure and compromised circulation in other organs.

Treatment of hypertensive emergency includes **antihypertensive** therapy with the goal of lowering blood pressure to prevent end-organ damage.

(Choices A and E) Antibiotics and hypoglycemic agents are not used in the treatment of hypertensive emergency. Although sepsis can cause acute kidney injury and unresponsiveness, histology would show evidence of tubular necrosis with sloughing of tubular epithelial cells and loss of basement membrane integrity.

(Choice C) Antiplatelet agents would be useful if the endothelial dysfunction in hypertensive emergencies led to thrombotic complications (eg, acute myocardial infarction, acute ischemic stroke), but would not have any effect on preventing acute hypertensive nephrosclerosis.

(Choice D) The mineralocorticoid activity of steroids leads to salt and water retention, increasing blood pressure and worsening hypertension.

(Choice F) Nonsteroidal anti-inflammatory drugs inhibit prostaglandin secretion, resulting in vasoconstriction and decreased renal blood flow. This would worsen hypertension by activating the renin-angiotensin-aldosterone system.

Educational objective:
Hyperplastic arteriosclerosis ("onion-skinning") and fibrinoid necrosis of the renal arterioles are typical morphologic findings in hypertensive (malignant) nephrosclerosis. End-organ damage can be prevented by treatment of high blood pressure with antihypertensives.

circumferential, acellular eosinophilic deposits **(fibrinoid necrosis)**.

- Over time, release of growth factors by damaged tissue stimulates the formation of concentric layers of collagen and proliferating smooth muscle cells, resulting in an "**onion skin**" appearance **(hyperplastic arteriosclerosis)** of the arteriole, as seen in this patient.

These processes result in narrowing and obliteration of the arteriolar lumens, reducing glomerular perfusion and filtration, with subsequent activation of the renin-angiotensin-aldosterone system. This maladaptation can result in a further increase in blood pressure and compromised circulation in other organs.

Treatment of hypertensive emergency includes **antihypertensive** therapy with the goal of lowering blood pressure to prevent end-organ damage.

(Choices A and E) Antibiotics and hypoglycemic agents are not used in the treatment of hypertensive emergency. Although sepsis can cause acute kidney injury and unresponsiveness, histology would show evidence of tubular necrosis with sloughing of tubular epithelial cells and loss of basement membrane integrity.

(Choice C) Antiplatelet agents would be useful if the endothelial dysfunction in hypertensive emergencies led to thrombotic complications (eg, acute myocardial infarction, acute ischemic stroke), but would not have any effect on preventing acute hypertensive nephrosclerosis.

(Choice D) The mineralocorticoid activity of steroids leads to salt and water retention, increasing blood pressure and worsening hypertension.

(Choice F) Nonsteroidal anti-inflammatory drugs inhibit prostaglandin secretion, resulting in vasoconstriction and decreased renal blood flow. This would worsen hypertension by activating the renin-angiotensin-aldosterone system.

Educational objective:
Hyperplastic arteriosclerosis ("onion-skinning") and fibrinoid necrosis of the renal arterioles are typical morphologic findings in hypertensive (malignant) nephrosclerosis. End-organ damage can be prevented by treatment of high blood pressure with antihypertensives.

Pathology	Renal, Urinary Systems & Electrolytes	Primary hypertension
Subject	System	Topic

Copyright © UWorld. All rights reserved.

1 2 3 4 5 6 7 8 9 10 11 12 13 14 15 16 17 18 19 20 21 22 23 24 25 26 27 28 29 30

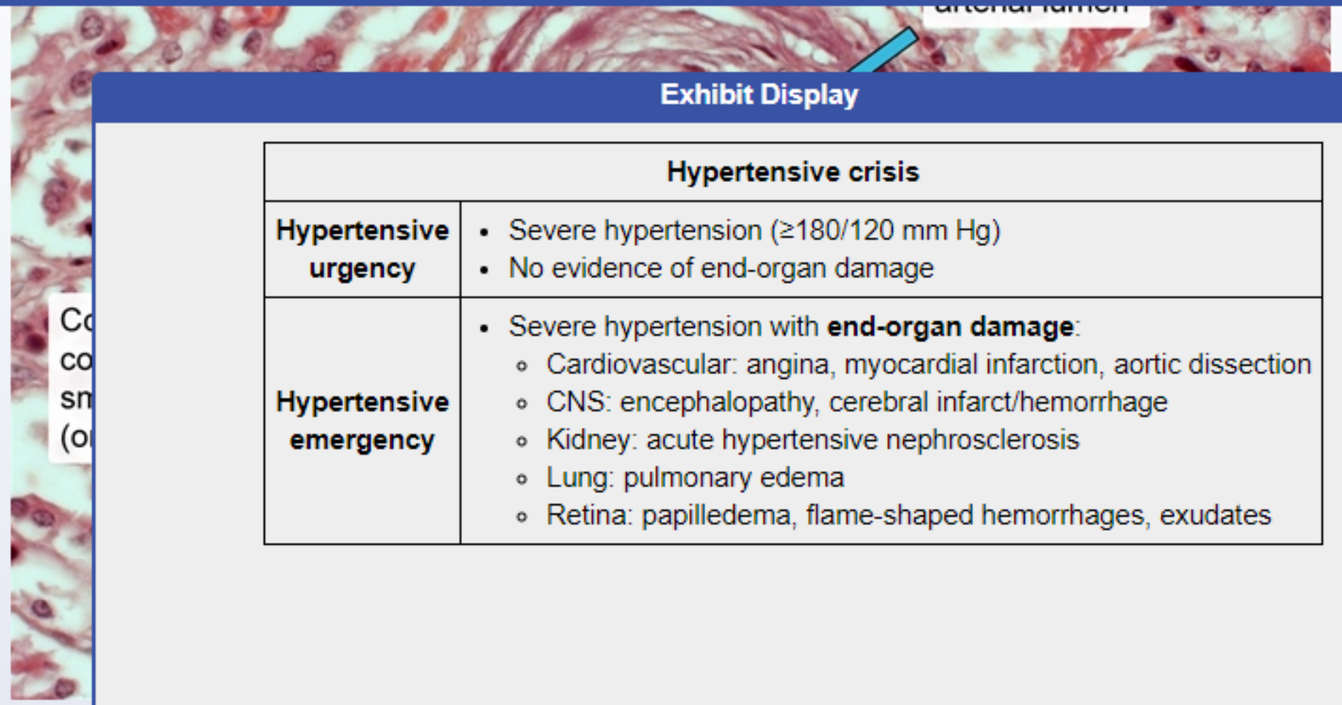

Hypertensive (malignant

results in end-organ dama

extravasation of plasma p

- Leakage of fibrinoge
  circumferential, ace
- Over time, release o
  muscle cells, resulti

These processes result in

activation of the renin-angiotensin-aldosterone system. This maladaptation can result in a further increase in blood pressure and compromised

Exhibit Display

Hypertensive crisis	
Hypertensive urgency	• Severe hypertension (≥180/120 mm Hg) • No evidence of end-organ damage
Hypertensive emergency	• Severe hypertension with **end-organ damage**: ◦ Cardiovascular: angina, myocardial infarction, aortic dissection ◦ CNS: encephalopathy, cerebral infarct/hemorrhage ◦ Kidney: acute hypertensive nephrosclerosis ◦ Lung: pulmonary edema ◦ Retina: papilledema, flame-shaped hemorrhages, exudates

Add To New Card | Existing Card

9
10
11
12
13
14
15
16
17
18
19
20
21
22
23
24
25
26
27
28
29
30
31
32
33
34
35
36
37
38

A 65-year-old man comes to the office for evaluation of blood in the urine. The patient has no abdominal pain, urinary frequency, or urgency. He has hypertension, type 2 diabetes mellitus, and stage II chronic kidney disease. He quit smoking 10 years ago and had smoked a pack of cigarettes daily for 30 years. On examination, vital signs are within normal limits. The patient's BMI is 33 kg/m^2. Appropriate work-up is performed, and he undergoes a renal biopsy. The histopathologic findings are displayed on the slide below.

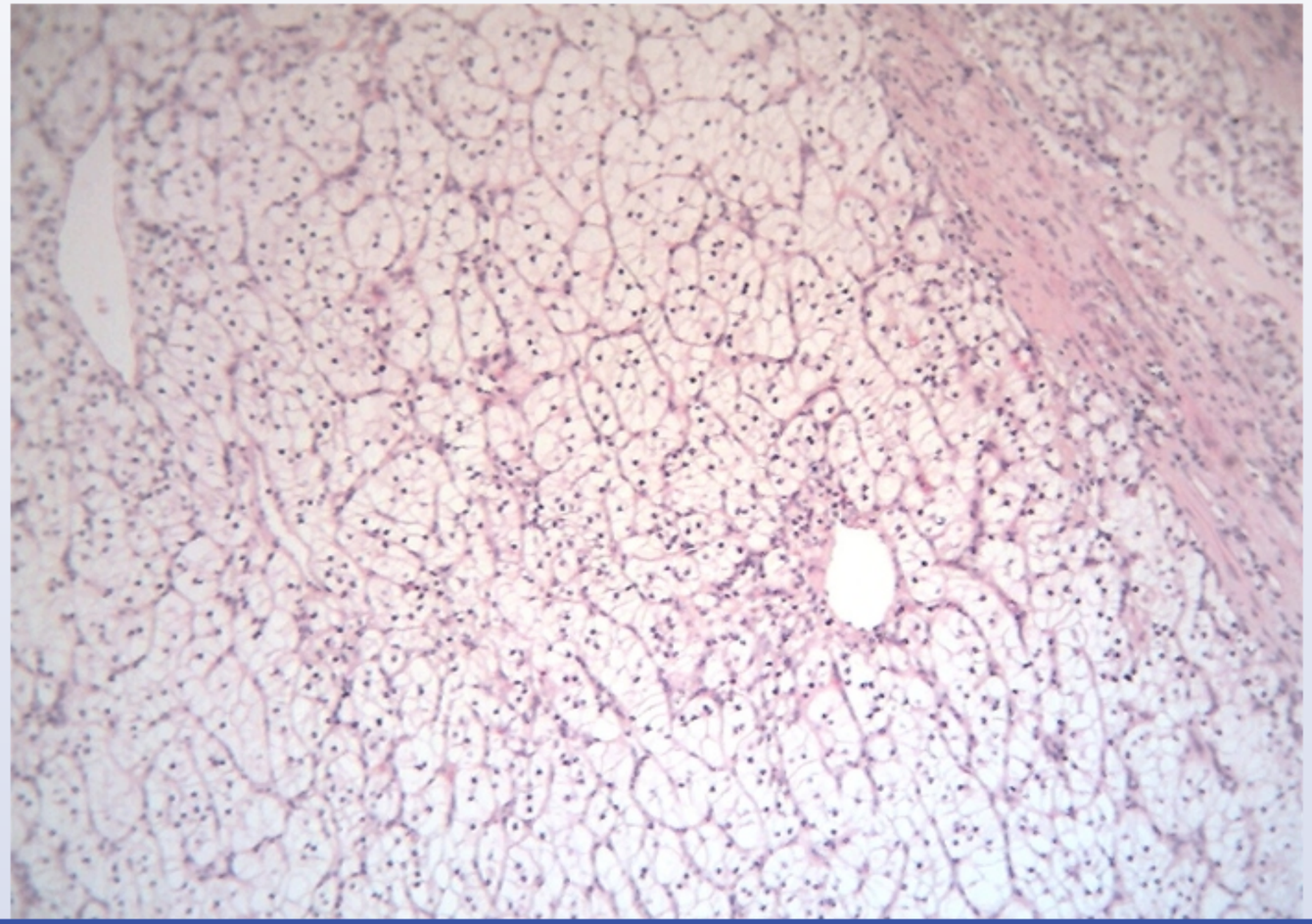

Settings

Item 31 of 40
Question Id: 1862

Mark | Previous | Next | Full Screen | Tutorial | Lab Values | Notes | Calculator | Reverse Color | Text Zoom | Settings

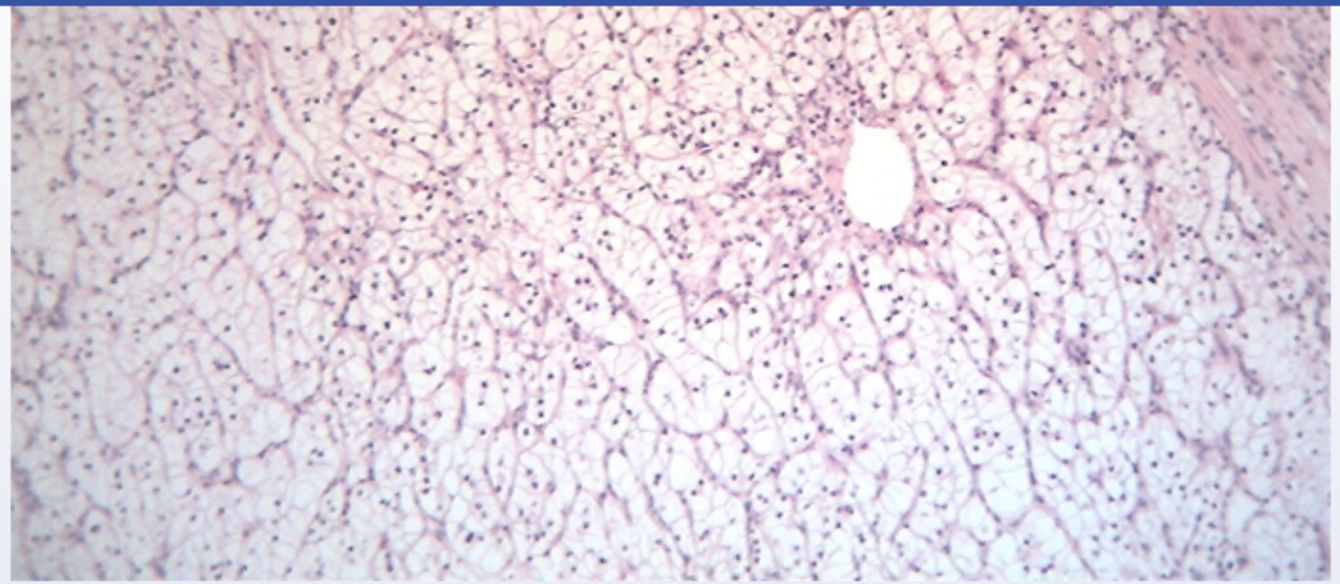

Which of the following processes most likely accounts for the abnormal appearance of these cells?

- A. Glycogen and lipid accumulation
- B. Karyorrhexis
- C. Membrane lipid peroxidation
- D. Mitochondrial swelling
- E. Pigment accumulation

Submit

Block Time Remaining: 00:05:47
TUTOR

5 | Feedback | Suspend | End Block

9, 10, 11, 12, 13, 14, 15, 16, 17, 18, 19, 20, 21, 22, 23, 24, 25, 26, 27, 28, 29, 30, 31, 32, 33, 34, 35, 36, 37, 38

9
10
11
12
13
14
15
16
17
18
19
20
21
22
23
24
25
26
27
28
29
30
31
32
33
34
35
36
37
38

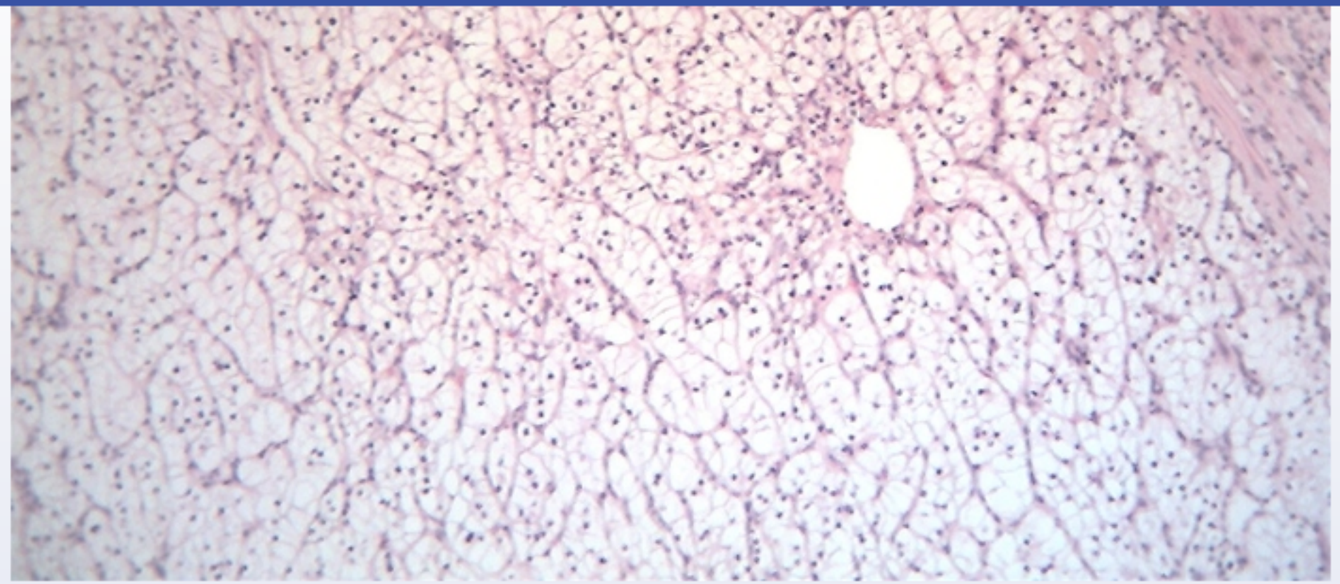

Which of the following processes most likely accounts for the abnormal appearance of these cells?

- ✓ A. Glycogen and lipid accumulation (76%)
- B. Karyorrhexis (8%)
- C. Membrane lipid peroxidation (9%)
- D. Mitochondrial swelling (4%)
- E. Pigment accumulation (1%)

Omitted
Correct answer

76%
Answered correctly

05 secs
Time Spent

03/16/2020
Last Updated

9
10
11
12
13
14
15
16
17
18
19
20
21
22
23
24
25
26
27
28
29
30
31
32
33
34
35
36
37
38

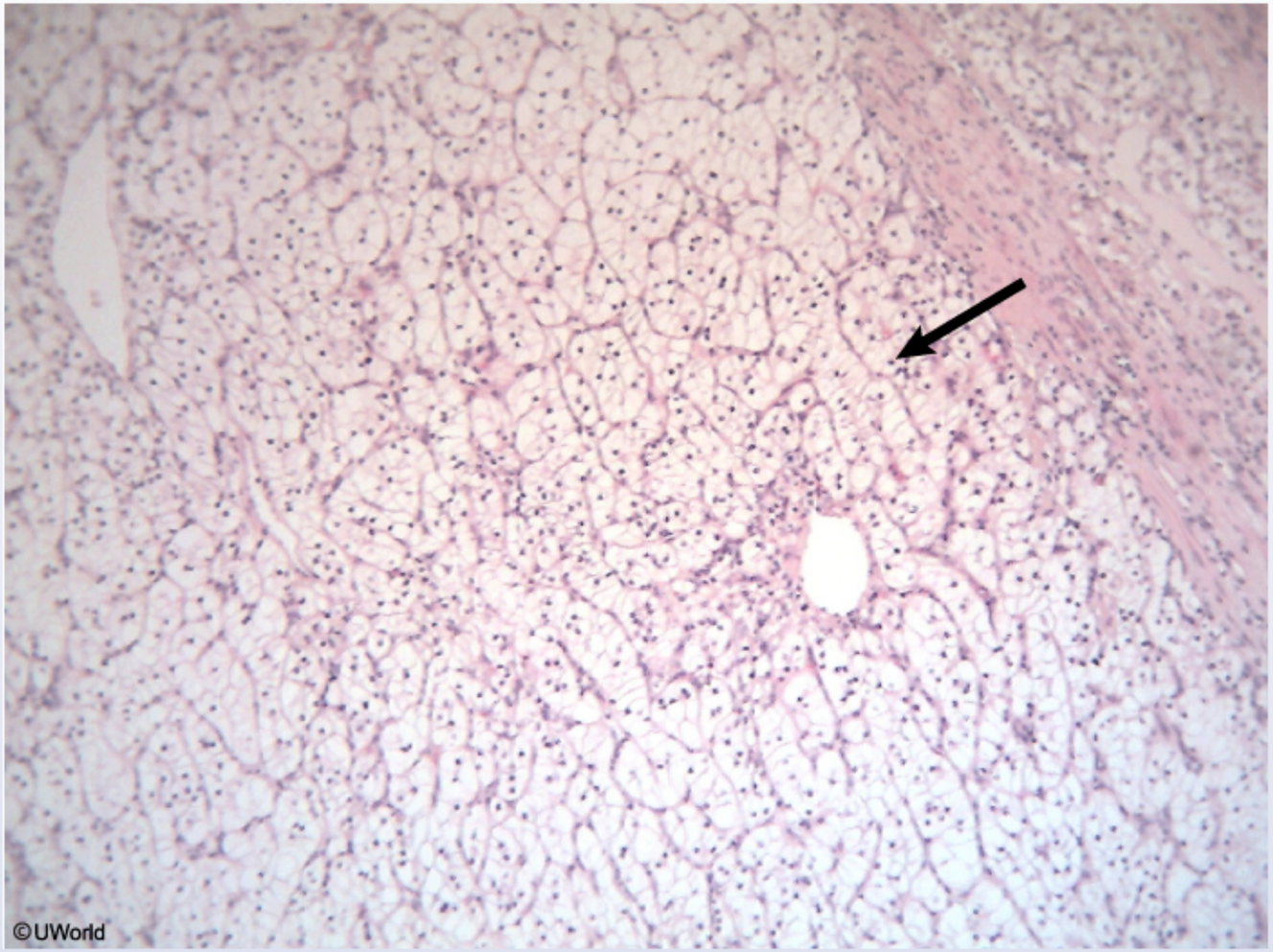

Gross painless hematuria in an older adult should be considered a sign of urinary tract cancer (urothelial or renal cell carcinoma) until proven otherwise. This patient's renal biopsy shows **rounded/polygonal cells** with abundant **clear cytoplasm**, which is characteristic of **clear cell carcinoma**, the most common form of renal cell carcinoma. Clear cell carcinoma originates from proximal tubular epithelial cells and contains copious amounts of intracellular glycogen and lipids. Standard tissue fixation and staining techniques typically dissolve glycogen and lipids from

Gross painless hematuria in an older adult should be considered a sign of urinary tract cancer (urothelial or renal cell carcinoma) until proven otherwise. This patient's renal biopsy shows **rounded/polygonal cells** with abundant **clear cytoplasm**, which is characteristic of **clear cell carcinoma**, the most common form of renal cell carcinoma. Clear cell carcinoma originates from proximal tubular epithelial cells and contains copious amounts of intracellular glycogen and lipids. Standard tissue fixation and staining techniques typically dissolve glycogen and lipids from pathologic specimens, leaving **clear spaces**, as seen in the slide.

(Choice B) Karyorrhexis is fragmentation of pyknotic (condensed) nuclei during apoptotic cell death. The cells in this slide have intact nuclei.

(Choice C) Plasma membrane damage caused by lipid peroxidation can be visualized using immunofluorescent microscopy. Lipid peroxidation is a form of free radical damage and is associated with inflammation, atherosclerosis, and tumorigenesis.

(Choice D) Mitochondrial swelling usually occurs during cell injury and would not be expected to render the cell cytoplasm completely clear on routine hematoxylin and eosin stain.

(Choice E) Melanin and hemosiderin are pigments commonly seen on histologic specimens. Hemosiderin is an iron oxide pigment that stains tissues at sites of bleeding.

Educational objective:
The most common renal malignancy is clear cell carcinoma, which arises from renal proximal tubular cells. Rounded or polygonal cells with abundant clear cytoplasm are seen on light microscopy. "Clear cells" are generally those with a high glycogen or lipid content that dissolves during routine tissue preparation.

Pathology	Renal, Urinary Systems & Electrolytes	Renal cell carcinoma
Subject	System	Topic

Copyright © UWorld. All rights reserved.

Settings

Item 31 of 40
Question Id: 1862

Mark | Previous | Next | Full Screen | Tutorial | Lab Values | Notes | Calculator | Reverse Color | Text Zoom | Settings

9 10 11 12 13 14 15 16 17 18 19 20 21 22 23 24 25 26 27 28 29 30 31 32 33 34 35 36 37 38

©UWo

Gross painless hematuria
otherwise. This patient's r
carcinoma, the most com
copious amounts of intrac
pathologic specimens, lea

(Choice B) Karyorrhexis

(Choice C) Plasma mem
a form of free radical dam

(Choice D) Mitochondrial
routine hematoxylin and e

(Choice E) Melanin and l
tissues at sites of bleeding

Educational objective:
The most common renal r
abundant clear cytoplasm
during routine tissue prepa

Pathology — Subject
Renal, U — System

Exhibit Display

Zoom In | Zoom Out | Reset | Add To New Card | Existing Card

Block Time Remaining: 00:05:49
TUTOR

5 | Feedback | Suspend | End Block

Settings

Item 31 of 40
Question Id: 1862

Mark | Previous | Next | Full Screen | Tutorial | Lab Values | Notes | Calculator | Reverse Color | Text Zoom | Settings

9
10
11
12
13
14
15
16
17
18
19
20
21
22
23
24
25
26
27
28
29
30
31
32
33
34
35
36
37
38

Exhibit Display

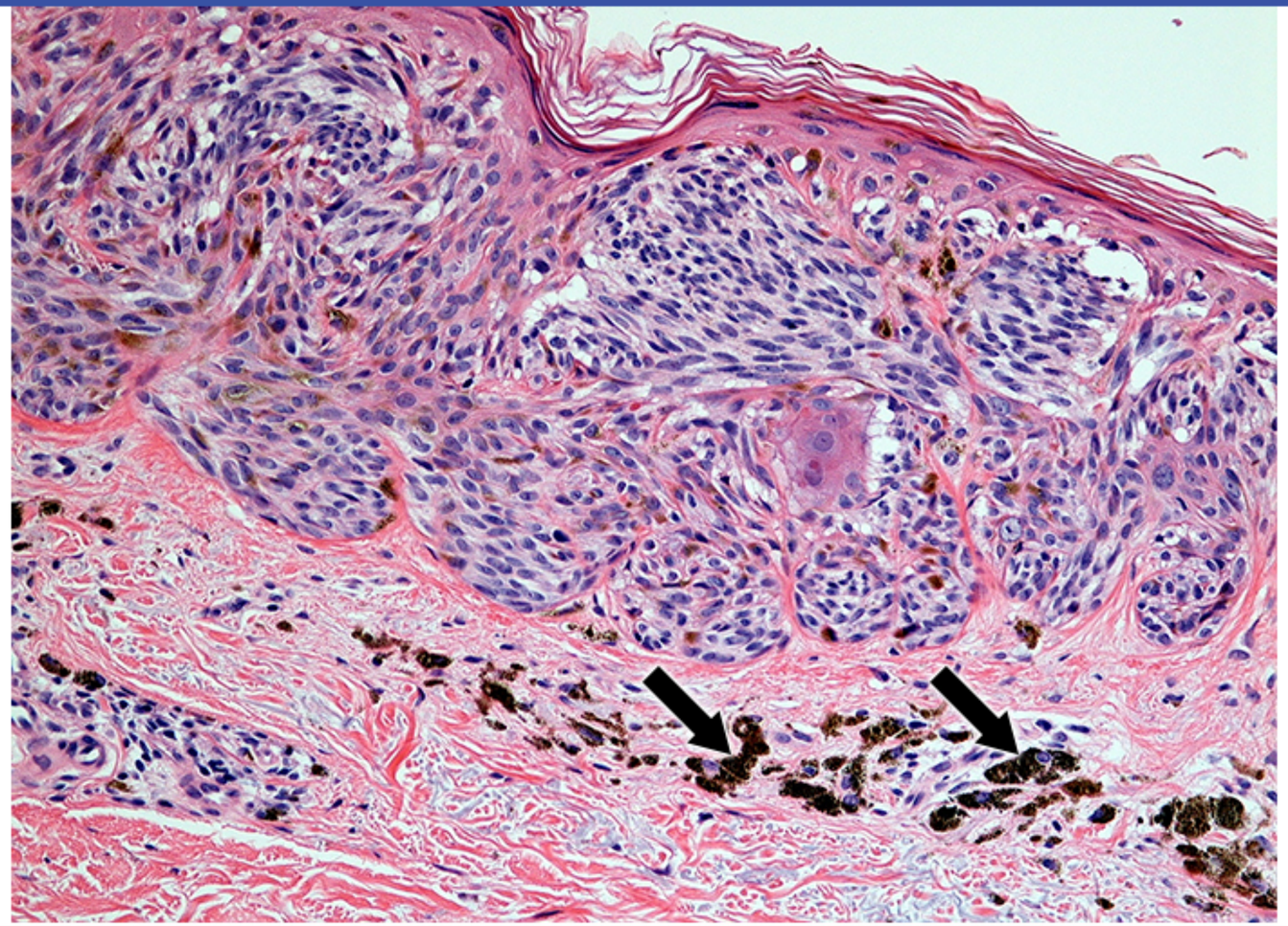

Zoom In | Zoom Out | Reset | Add To New Card | Existing Card

Block Time Remaining: 00:05:49
TUTOR

5 | Feedback | Suspend | End Block

Settings

9
10
11
12
13
14
15
16
17
18
19
20
21
22
23
24
25
26
27
28
29
30
31
32
33
34
35
36
37
38

Item 31 of 40
Question Id: 1862

Mark | Previous | Next | Full Screen | Tutorial | Lab Values | Notes | Calculator | Reverse Color | Text Zoom | Settings

Exhibit Display

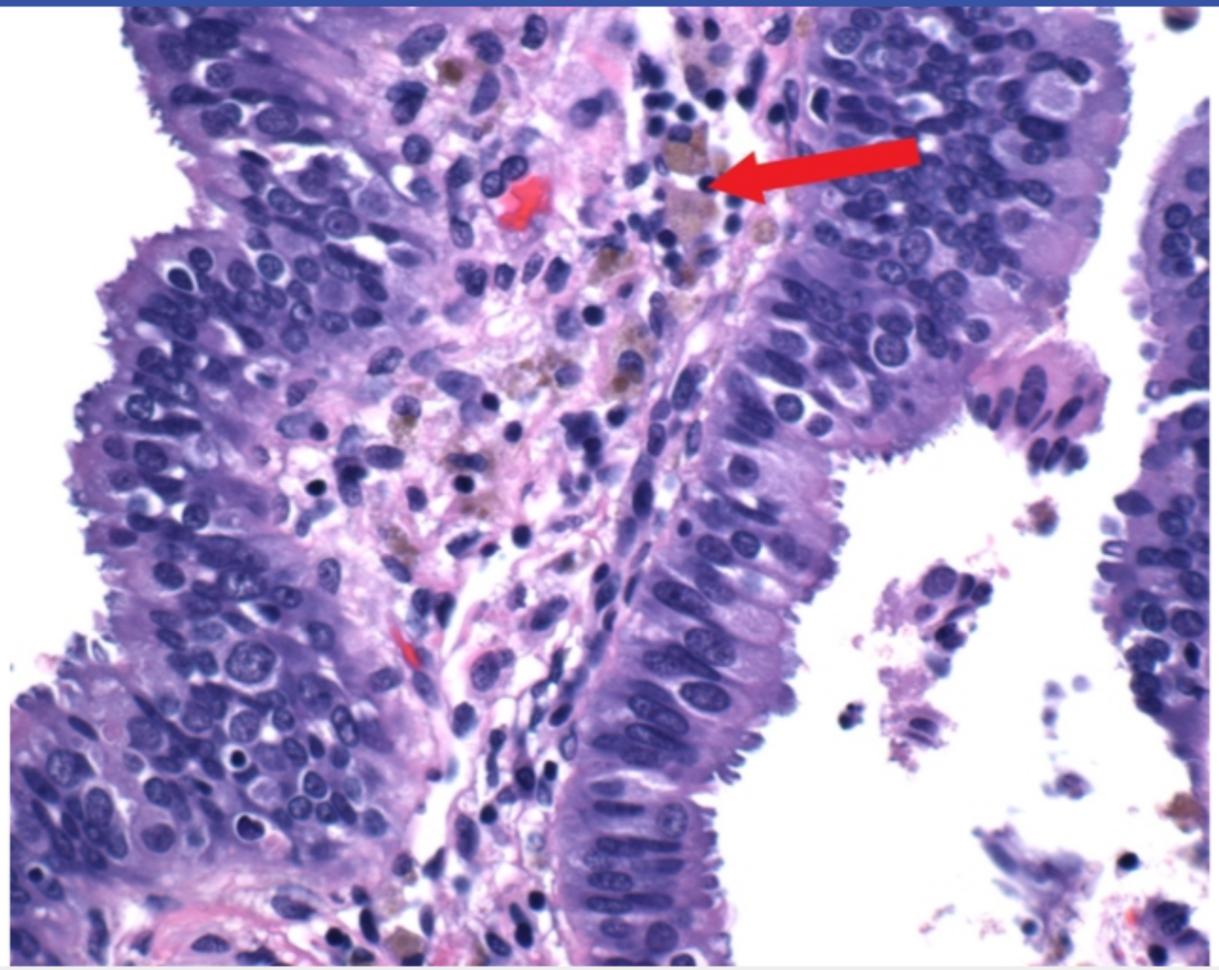

Zoom In | Zoom Out | Reset | Add To New Card | Existing Card

Block Time Remaining: 00:05:49
TUTOR

5 | Feedback | Suspend | End Block

11
12
13
14
15
16
17
18
19
20
21
22
23
24
25
26
27
28
29
30
31
32
33
34
35
36
37
38
39
40

A 46-year-old woman is admitted to the hospital with dehydration secondary to excess output from an ileostomy. Five years ago, the patient had a total colectomy with a diverting ileostomy for colon cancer. For the last 6 months, she has had increased output from the ileostomy and has been admitted to the hospital twice with similar episodes of dehydration. On the second day of admission, she reports right flank pain. X-ray of the abdomen reveals a nonspecific bowel gas pattern with no evidence of renal calculi. Ultrasound of the abdomen shows a 4-mm stone in the distal right ureter. The patient is treated with analgesics and the stone passes spontaneously. Microscopic analysis of the stone reveals a pure uric acid stone. Which of the following is the most likely underlying mechanism leading to stone formation in this patient?

A. Bile salt malabsorption in the ileum

B. Concentrated acidic urine

C. Increased uric acid production

D. Infection with urea-splitting bacteria

E. Overproduction of parathyroid hormone

Submit

11
12
13
14
15
16
17
18
19
20
21
22
23
24
25
26
27
28
29
30
31
32
33
34
35
36
37
38
39
40

A 46-year-old woman is admitted to the hospital with dehydration secondary to excess output from an ileostomy. Five years ago, the patient had a total colectomy with a diverting ileostomy for colon cancer. For the last 6 months, she has had increased output from the ileostomy and has been admitted to the hospital twice with similar episodes of dehydration. On the second day of admission, she reports right flank pain. X-ray of the abdomen reveals a nonspecific bowel gas pattern with no evidence of renal calculi. Ultrasound of the abdomen shows a 4-mm stone in the distal right ureter. The patient is treated with analgesics and the stone passes spontaneously. Microscopic analysis of the stone reveals a pure uric acid stone. Which of the following is the most likely underlying mechanism leading to stone formation in this patient?

- A. Bile salt malabsorption in the ileum (18%)
- ✓ B. Concentrated acidic urine (51%)
- C. Increased uric acid production (20%)
- D. Infection with urea-splitting bacteria (8%)
- E. Overproduction of parathyroid hormone (1%)

Omitted
Correct answer
B

51%
Answered correctly

02 secs
Time Spent

02/16/2020
Last Updated

Explanation

Uric acid kidney stones	
	• **Increased uric acid excretion**: Gout, myeloproliferative disorders

Uric acid kidney stones	
Risk factors	• **Increased uric acid excretion**: Gout, myeloproliferative disorders • **Increased urine concentration**: Hot, arid climates; dehydration • **Low urine pH**: Chronic diarrhea (GI bicarbonate loss), metabolic syndrome/diabetes mellitus
Pathophysiology	• Acidic urine favors formation of uric acid (insoluble) over urate (soluble) • Supersaturation of urine with uric acid precipitates crystal formation
Clinical characteristics	• Radiolucent stones (not visible on x-ray) • Uric acid crystals on urine microscopy • Urine pH usually <5.5
Treatment	• Alkalinization of urine (potassium citrate)

GI = gastrointestinal.

This patient with recurrent episodes of **dehydration** due to fluid loss from her ileostomy developed a uric acid stone. Pure uric acid stones are radiolucent and cannot be visualized on x-ray but appear as yellow/brown agglomerations of rhomboid-shaped crystals on gross/microscopic examination. Biochemical risk factors include low urine pH, low urine volume (eg, dehydration), and hyperuricemia.

Patients with **chronic diarrhea** or those who have had a colectomy have reduced bicarbonate reabsorption from the gut, leading to a state of chronic metabolic acidosis. The kidneys compensate by increasing the **excretion of hydrogen ions** (H^+) and reabsorption of bicarbonate in the collecting ducts. This lowers urine pH (**acidic urine**), increasing the conversion of soluble urate ion into **insoluble uric acid**. Conversely, alkalinization of the urine with potassium citrate favors formation of urate and can prevent, and in some cases dissolve, uric acid stones. Other commonly associated conditions include gout, high cell turnover states (eg, lymphoproliferative disorders), and metabolic syndrome.

(Choice A) Dietary calcium and oxalate normally form insoluble complexes, which are eliminated in the feces. Disruption of the normal enterohepatic circulation of bile acids can cause malabsorption of dietary lipids, which then form soap complexes with calcium, allowing increased

This patient with recurrent episodes of **dehydration** due to fluid loss from her ileostomy developed a uric acid stone. Pure uric acid stones are radiolucent and cannot be visualized on x-ray but appear as yellow/brown agglomerations of rhomboid-shaped crystals on gross/microscopic examination. Biochemical risk factors include low urine pH, low urine volume (eg, dehydration), and hyperuricemia.

Patients with **chronic diarrhea** or those who have had a colectomy have reduced bicarbonate reabsorption from the gut, leading to a state of chronic metabolic acidosis. The kidneys compensate by increasing the **excretion of hydrogen ions** (H^+) and reabsorption of bicarbonate in the collecting ducts. This lowers urine pH (**acidic urine**), increasing the conversion of soluble urate ion into **insoluble uric acid**. Conversely, alkalinization of the urine with potassium citrate favors formation of urate and can prevent, and in some cases dissolve, uric acid stones. Other commonly associated conditions include gout, high cell turnover states (eg, lymphoproliferative disorders), and metabolic syndrome.

(Choice A) Dietary calcium and oxalate normally form insoluble complexes, which are eliminated in the feces. Disruption of the normal enterohepatic circulation of bile acids can cause malabsorption of dietary lipids, which then form soap complexes with calcium, allowing increased absorption of free oxalate. The excess oxalate is then excreted by the kidneys where it promotes formation of calcium oxalate stones. These stones are radio-opaque.

(Choice C) Overproduction of uric acid (eg, gout, myeloproliferative disorders) can lead to uric acid stones. However, this patient has no features of these disorders, and her stone formation is likely due to abnormally concentrated and acidic urine.

(Choice D) Hydrolysis of urea by urease-producing bacteria (eg, *Proteus*, *Klebsiella*) yields ammonia, which alkalinizes the urine and promotes formation of magnesium ammonium phosphate (struvite) stones. These stones are large and radio-opaque, and typically present with fever and moderate flank pain.

(Choice E) Hyperparathyroidism leads to hypercalcemia and an increased filtered calcium load. The subsequent hypercalciuria increases the risk of radio-opaque calcium (oxalate, phosphate) stones.

Educational objective:
Formation of uric acid kidney stones is promoted by low urine pH, which favors formation of insoluble uric acid over soluble urate ion. Gastrointestinal bicarbonate loss due to chronic diarrhea leads to chronic metabolic acidosis and production of acidic urine, promoting formation of uric acid stones.

collecting ducts. This lowers urine pH (**acidic urine**), increasing the conversion of soluble urate ion into **insoluble uric acid**. Conversely, alkalinization of the urine with potassium citrate favors formation of urate and can prevent, and in some cases dissolve, uric acid stones. Other commonly associated conditions include gout, high cell turnover states (eg, lymphoproliferative disorders), and metabolic syndrome.

(Choice A) Dietary calcium and oxalate normally form insoluble complexes, which are eliminated in the feces. Disruption of the normal enterohepatic circulation of bile acids can cause malabsorption of dietary lipids, which then form soap complexes with calcium, allowing increased absorption of free oxalate. The excess oxalate is then excreted by the kidneys where it promotes formation of calcium oxalate stones. These stones are radio-opaque.

(Choice C) Overproduction of uric acid (eg, gout, myeloproliferative disorders) can lead to uric acid stones. However, this patient has no features of these disorders, and her stone formation is likely due to abnormally concentrated and acidic urine.

(Choice D) Hydrolysis of urea by urease-producing bacteria (eg, *Proteus*, *Klebsiella*) yields ammonia, which alkalinizes the urine and promotes formation of magnesium ammonium phosphate (struvite) stones. These stones are large and radio-opaque, and typically present with fever and moderate flank pain.

(Choice E) Hyperparathyroidism leads to hypercalcemia and an increased filtered calcium load. The subsequent hypercalciuria increases the risk of radio-opaque calcium (oxalate, phosphate) stones.

Educational objective:
Formation of uric acid kidney stones is promoted by low urine pH, which favors formation of insoluble uric acid over soluble urate ion. Gastrointestinal bicarbonate loss due to chronic diarrhea leads to chronic metabolic acidosis and production of acidic urine, promoting formation of uric acid stones.

References

- Uric acid nephrolithiasis: a systemic metabolic disorder.

Pathology	Renal, Urinary Systems & Electrolytes	Renal calculi
Subject	System	Topic

Copyright © UWorld. All rights reserved.

Settings

11
12
13
14
15
16
17
18
19
20
21
22
23
24
25
26
27
28
29
30
31
32
33
34
35
36
37
38
39
40

Item 32 of 40
Question Id: 12081

Mark | Previous | Next | Full Screen | Tutorial | Lab Values | Notes | Calculator | Reverse Color | Text Zoom | Settings

- Radiolucent stones (not visible on x-ray)

Exhibit Display



Zoom In | Zoom Out | Reset | Add To New Card | Existing Card

risk of radio-opaque calcium (oxalate, phosphate) stones

Block Time Remaining: 00:05:51
TUTOR

4 | Feedback | Suspend | End Block

11
12
13
14
15
16
17
18
19
20
21
22
23
24
25
26
27
28
29
30
31
32
33
34
35
36
37
38
39
40

A 57-year-old man comes to the hospital due to nausea, vomiting, and severe crampy pain in the right flank. He has had no fever or chills. Several days ago, the patient had similar, but less severe, pain that resolved spontaneously. Medical history is significant for type 2 diabetes mellitus, obesity, hyperlipidemia, hypertension, and gout. Temperature is 37 C (98.6 F), blood pressure is 160/100 mm Hg, and pulse is 98/min. Physical examination shows right flank tenderness. Blood urea nitrogen and serum creatinine are normal. Abdominal ultrasound reveals right-sided hydronephrosis and proximal ureteral dilation. Urinalysis in this patient would most likely reveal which of the following?

A. Malignant cells

B. Red blood cells

C. Red blood cell casts

D. Specific gravity of 1.002

E. White blood cell casts

Submit

11
12
13
14
15
16
17
18
19
20
21
22
23
24
25
26
27
28
29
30
31
32
33
34
35
36
37
38
39
40

A 57-year-old man comes to the hospital due to nausea, vomiting, and severe crampy pain in the right flank. He has had no fever or chills. Several days ago, the patient had similar, but less severe, pain that resolved spontaneously. Medical history is significant for type 2 diabetes mellitus, obesity, hyperlipidemia, hypertension, and gout. Temperature is 37 C (98.6 F), blood pressure is 160/100 mm Hg, and pulse is 98/min. Physical examination shows right flank tenderness. Blood urea nitrogen and serum creatinine are normal. Abdominal ultrasound reveals right-sided hydronephrosis and proximal ureteral dilation. Urinalysis in this patient would most likely reveal which of the following?

A. Malignant cells (2%)
✓ B. Red blood cells (57%)
C. Red blood cell casts (10%)
D. Specific gravity of 1.002 (16%)
E. White blood cell casts (12%)

Omitted
Correct answer
B

57%
Answered correctly

01 sec
Time Spent

03/22/2020
Last Updated

Explanation

This patient has acute, recurrent flank pain associated with ureteral dilation; this presentation is typical for acute **ureterolithiasis**. Although ultrasound is relatively sensitive for ureteral and calyceal dilation due to an obstructing stone **(hydronephrosis)**, small stones themselves may not be visible.

Kidney stones usually cause **disruption of the ureteral epithelium** with resulting gross or microscopic **hematuria** due to the presence of free red

This patient has acute, recurrent flank pain associated with ureteral dilation; this presentation is typical for acute **ureterolithiasis**. Although ultrasound is relatively sensitive for ureteral and calyceal dilation due to an obstructing stone **(hydronephrosis)**, small stones themselves may not be visible.

Kidney stones usually cause **disruption of the ureteral epithelium** with resulting gross or microscopic **hematuria** due to the presence of free red blood cells (RBCs) in the urine. When bleeding into the renal collecting system or lower urinary tract occurs, RBC **morphology is normal**. In contrast, glomerular bleeding (eg, glomerulonephritis) causes formation of RBC casts due to trapping of RBC cells by precipitating Tamm-Horsfall protein **(Choice C)**; the cells are typically dysmorphic due to mechanical and osmotic trauma as they pass through the nephron.

Inspection of urine sediment in patients with acute ureterolithiasis may identify crystals corresponding to the type of stone. This patient has risk factors for uric acid stones, including gout and metabolic syndrome (obesity, diabetes mellitus, hyperlipidemia), and urinalysis may show polygonal (eg, rhomboid, hexagonal) uric acid crystals (which are morphologically distinct from the needle-shaped monosodium urate crystals seen in synovial fluid in acute gout).

(Choice A) Malignant cells can sometimes be identified on unstained microscopy of urine sediment in patients with urothelial carcinoma arising from the epithelium of the renal pelvis, ureters, or bladder. However, these malignancies typically present with painless hematuria rather than acute ureteral obstruction.

(Choice D) Urine specific gravity correlates with urine concentration and is influenced by hydration status, renal perfusion, renal tubular concentrating ability, and regulatory hormone (eg, antidiuretic hormone) levels. A specific gravity of ≤1.003 indicates dilute urine; because kidney stones most commonly occur in concentrated urine (eg, >1.015), it is unlikely that a patient with an acute stone would have such a low specific gravity.

(Choice E) Occasional white blood cells may also be seen in ureterolithiasis, but overt pyuria suggests a urinary tract infection; white cell casts would be more characteristic of intrarenal inflammation or infection (eg, acute interstitial nephritis, pyelonephritis).

Educational objective:
Urine sediment in acute ureterolithiasis typically shows free red blood cells (hematuria) and crystals consistent with the type of stone. Ultrasound can reveal ureteral and calyceal dilation (hydronephrosis), but small stones themselves may not be visible.

Settings

11
12
13
14
15
16
17
18
19
20
21
22
23
24
25
26
27
28
29
30
31
32
33
34
35
36
37
38
39
40

Item 33 of 40
Question Id: 15271

Mark | Previous | Next | Full Screen | Tutorial | Lab Values | Notes | Calculator | Reverse Color | Text Zoom | Settings

This patient has acute, recurrent flank pain associated with ureteral dilation; this presentation is typical for acute **ureterolithiasis**. Although

Exhibit Display

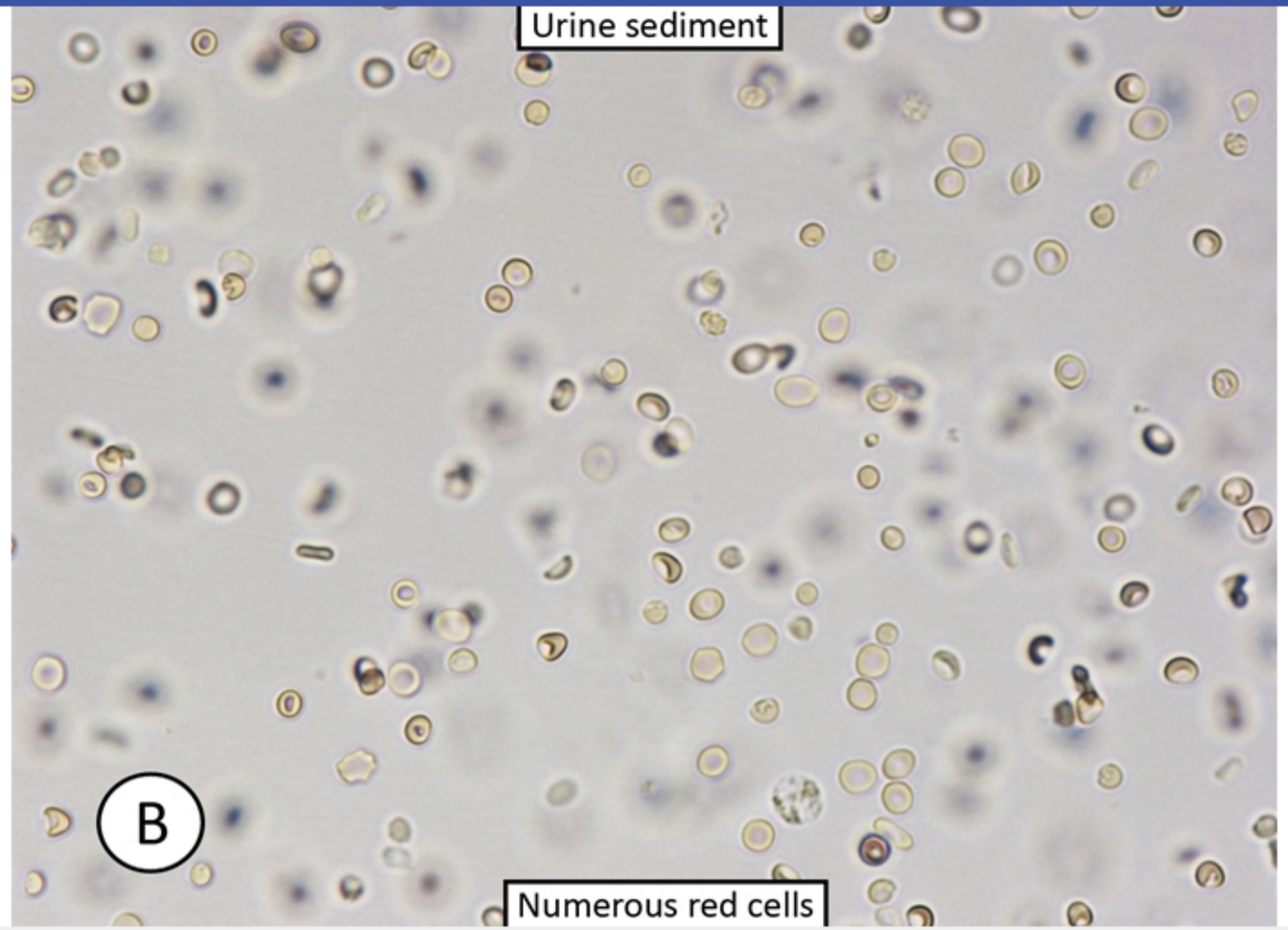

Zoom In | Zoom Out | Reset | Add To New Card | Existing Card

Block Time Remaining: 00:05:52
TUTOR

6 | Feedback | Suspend | End Block

Settings

- 11
- 12
- 13
- 14
- 15
- 16
- 17
- 18
- 19
- 20
- 21
- 22
- 23
- 24
- 25
- 26
- 27
- 28
- 29
- 30
- 31
- 32
- 33
- 34
- 35
- 36
- 37
- 38
- 39
- 40

Item 33 of 40
Question Id: 15271

Mark | Previous | Next | Full Screen | Tutorial | Lab Values | Notes | Calculator | Reverse Color | Text Zoom | Settings

This patient has acute, recurrent flank pain associated with ureteral dilation; this presentation is typical for acute **ureterolithiasis**. Although

Exhibit Display



Zoom In | Zoom Out | Reset | Add To New Card | Existing Card

Block Time Remaining: 00:05:52
TUTOR

6 | Feedback | Suspend | End Block

Settings

11
12
13
14
15
16
17
18
19
20
21
22
23
24
25
26
27
28
29
30
31
32
33
34
35
36
37
38
39
40

Item 33 of 40
Question Id: 15271

Mark | Previous | Next | Full Screen | Tutorial | Lab Values | Notes | Calculator | Reverse Color | Text Zoom | Settings

This patient has acute, recurrent flank pain associated with ureteral dilation; this presentation is typical for acute **ureterolithiasis**. Although

Exhibit Display



Zoom In | Zoom Out | Reset | Add To New Card | Existing Card

Block Time Remaining: 00:05:52
TUTOR

6 | Feedback | Suspend | End Block

11
12
13
14
15
16
17
18
19
20
21
22
23
24
25
26
27
28
29
30
31
32
33
34
35
36
37
38
39
40

be visible.

Exhibit Display

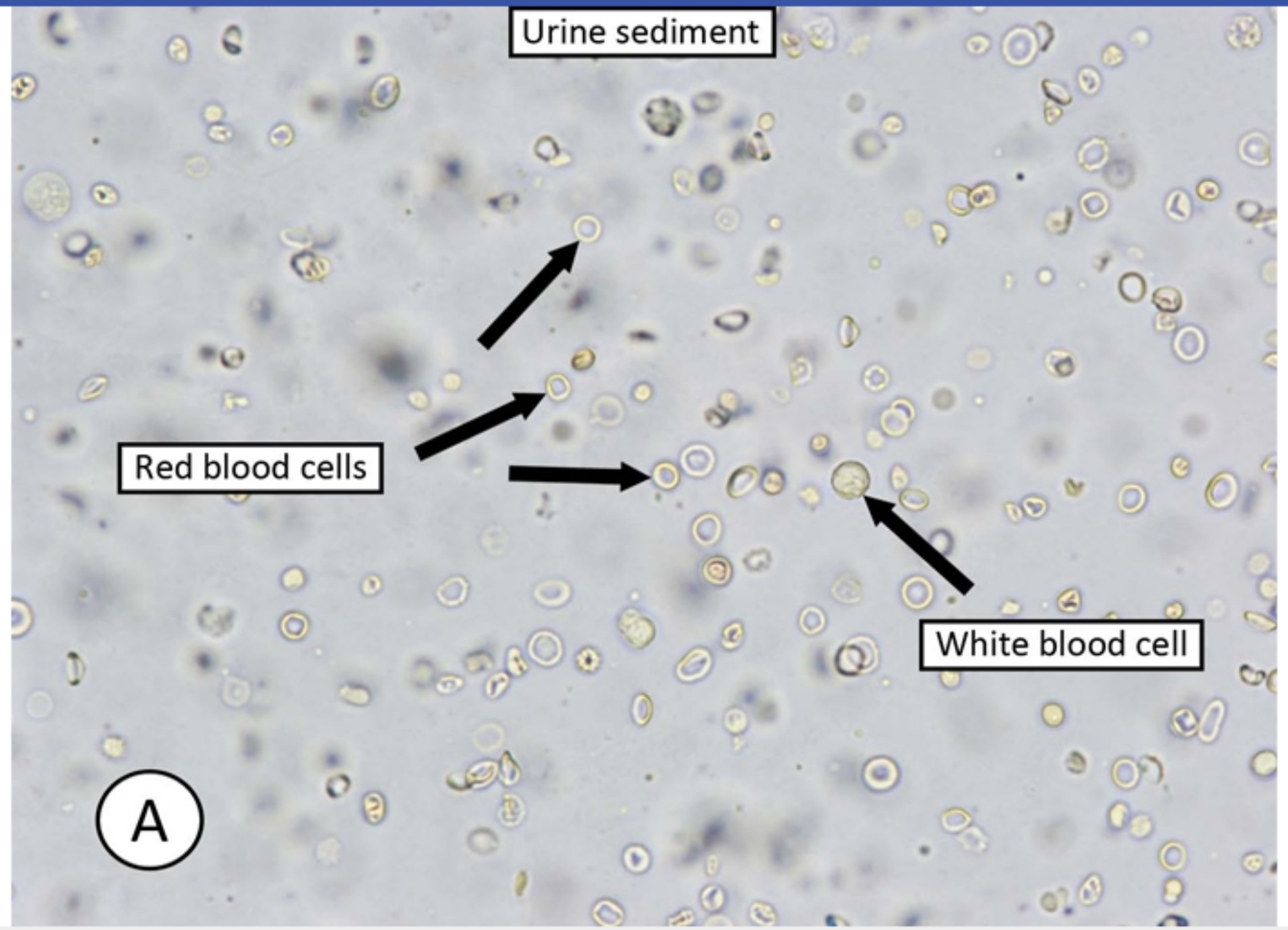

Zoom In | Zoom Out | Reset | Add To New Card | Existing Card

Subject System Topic

11
12
13
14
15
16
17
18
19
20
21
22
23
24
25
26
27
28
29
30
31
32
33
34
35
36
37
38
39
40

A 21-year-old woman with type 1 diabetes mellitus comes to the office for a follow-up appointment. She has been using daily long-acting and short-acting insulin injections from the time she was diagnosed 6 years ago. The patient was seen by her ophthalmologist 2 weeks ago and had no signs of diabetic retinopathy. She eats a balanced diet and jogs every morning for 40 minutes. On examination, the skin of her extremities is intact and peripheral pulses are palpable. Sensory examination shows normal pinprick, vibration, and temperature sensation in her lower extremities. Laboratory evaluation shows normal renal function and lipid profile. The patient's hemoglobin A1c level is 7%. Screening for early-stage diabetic nephropathy in this patient would best be accomplished by measuring the urinary concentration of which of the following substances?

A. Albumin
B. Glucose
C. Ketones
D. Red blood cell casts
E. Tubular protein
F. Waxy casts

Submit

11
12
13
14
15
16
17
18
19
20
21
22
23
24
25
26
27
28
29
30
31
32
33
34
35
36
37
38
39
40

A 21-year-old woman with type 1 diabetes mellitus comes to the office for a follow-up appointment. She has been using daily long-acting and short-acting insulin injections from the time she was diagnosed 6 years ago. The patient was seen by her ophthalmologist 2 weeks ago and had no signs of diabetic retinopathy. She eats a balanced diet and jogs every morning for 40 minutes. On examination, the skin of her extremities is intact and peripheral pulses are palpable. Sensory examination shows normal pinprick, vibration, and temperature sensation in her lower extremities. Laboratory evaluation shows normal renal function and lipid profile. The patient's hemoglobin A1c level is 7%. Screening for early-stage diabetic nephropathy in this patient would best be accomplished by measuring the urinary concentration of which of the following substances?

- ✓ A. Albumin (72%)
- B. Glucose (12%)
- C. Ketones (3%)
- D. Red blood cell casts (1%)
- E. Tubular protein (6%)
- F. Waxy casts (3%)

Omitted
Correct answer
A

72%
Answered correctly

02 secs
Time Spent

07/09/2020
Last Updated

Explanation

Explanation

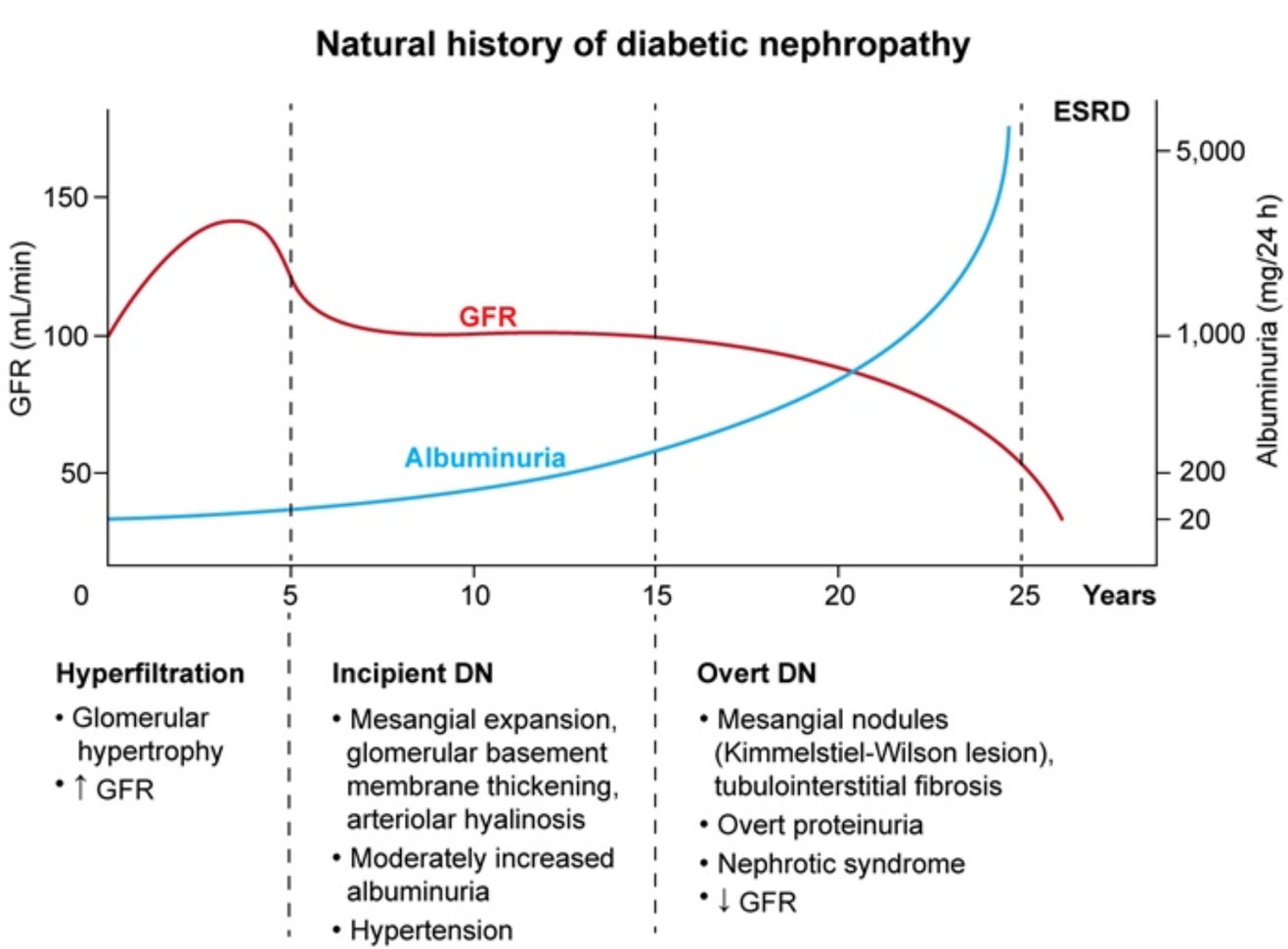

Diabetic nephropathy (DN) is the most common cause of end-stage renal disease in the United States. It occurs in both types 1 and 2 diabetes.

Diabetic nephropathy (DN) is the most common cause of end-stage renal disease in the United States. It occurs in both types 1 and 2 diabetes. The earliest morphological change is glomerular basement membrane thickening with mesangial matrix expansion. Normally, the glomerular basement membrane has negatively charged heparan sulfate moieties that form a charge barrier preventing leakage of negatively charged proteins (eg, albumin) into the Bowman capsule. In diabetes, there is progressive loss of this negative charge due to upregulation of heparanase expression by renal epithelial cells, leading to leakage of albumin and other plasma proteins.

In the initial stages of DN, only small amounts of albumin (30-300 mg/day; ie, **moderately increased albuminuria**) are lost but can be detected with an albumin-specific urine assay (regular dipstick urinalysis has low sensitivity and is not recommended). Early administration of **ACE inhibitors** in patients with diabetes and moderately increased albuminuria can reduce urinary albumin excretion and slow progression to overt DN.

(Choice B) Glycosuria is seen at blood glucose levels >200-300 mg/dL due to saturation of renal glucose transporters. Glycosuria reflects poor glycemic control but does not correlate with the degree of renal damage in DN.

(Choice C) Ketonuria occurs in starvation and in conditions that cause ketoacidosis, such as insufficient insulin administration in patients with type 1 diabetes mellitus. It is usually a transient phenomenon that corrects with treatment of the ketoacidosis.

(Choice D) Red blood cell casts are a sign of glomerular bleeding, such as in glomerulonephritis (eg, poststreptococcal glomerulonephritis). Diabetes mellitus usually causes a nephrotic syndrome with proteinuria and a bland urine sediment.

(Choice E) Low-molecular-weight proteins (eg, beta-2 microglobulin, immunoglobulin light chains) are normally filtered by the glomerulus and reabsorbed in the renal tubules. Damage to the tubular cells can cause loss of these tubular proteins in urine. Ischemic tubular damage may be seen in advanced DN.

(Choice F) Waxy casts are shiny, translucent structures formed in the dilated tubules of enlarged nephrons that undergo compensatory hypertrophy in response to reduced renal mass. They indicate advanced renal disease (chronic renal failure).

Educational objective:
Moderately increased albuminuria (urine albumin 30-300 mg/day) is the earliest manifestation of diabetic nephropathy. Screening for diabetic nephropathy is best achieved using an albumin-specific urine assay (regular dipstick urinalysis has low sensitivity).

References

Settings

11
12
13
14
15
16
17
18
19
20
21
22
23
24
25
26
27
28
29
30
31
32
33
34
35
36
37
38
39
40

Item 34 of 40
Question Id: 1913

Mark | Previous | Next | Full Screen | Tutorial | Lab Values | Notes | Calculator | Reverse Color | Text Zoom | Settings

Diabetic nephropathy (DN) is the most common cause of end-stage renal disease in the United States. It occurs in both types 1 and 2 diabetes.

Exhibit Display

Zoom In | Zoom Out | Reset | Add To New Card | Existing Card

Block Time Remaining: 00:05:54
TUTOR

3 | Feedback | Suspend | End Block

A 17-year-old boy is brought to the office due to occasional blood in the urine. The first episode occurred 1 year ago, about 3 days after a flulike illness, and resolved spontaneously. The patient had a similar episode about 6 months ago, which also seemed to resolve. He has no other medical conditions and does not use tobacco or alcohol. There is no history of blood or kidney disorders in the family. Vital signs are normal. On laboratory evaluation, blood urea nitrogen level is 14 mg/dL and creatinine is 0.8 mg/dL. Urinalysis results are as follows:

Specific gravity	1.013
Protein	+2
Blood	trace
Glucose	negative
Ketones	negative
Leukocyte esterase	negative
Nitrites	negative
White blood cells	1-2/hpf
Red blood cells	20-30/hpf

A renal biopsy is performed. Which of the following findings is most likely to be seen on microscopic evaluation?

A. Apple-green birefringent mesangial deposits
B. Crescent formation with linear IgG deposits
C. Effacement of podocyte foot processes
D. Granular IgG and C3 deposits
E. Lamellated basement membrane

11
12
13
14
15
16
17
18
19
20
21
22
23
24
25
26
27
28
29
30
31
32
33
34
35
36
37
38
39
40

Glucose	negative
Ketones	negative
Leukocyte esterase	negative
Nitrites	negative
White blood cells	1-2/hpf
Red blood cells	20-30/hpf

A renal biopsy is performed. Which of the following findings is most likely to be seen on microscopic evaluation?

- A. Apple-green birefringent mesangial deposits
- B. Crescent formation with linear IgG deposits
- C. Effacement of podocyte foot processes
- D. Granular IgG and C3 deposits
- E. Lamellated basement membrane
- F. Mesangial deposition of IgA
- G. Sclerosis of a portion of some glomeruli
- H. Thin basement membrane

Submit

11
12
13
14
15
16
17
18
19
20
21
22
23
24
25
26
27
28
29
30
31
32
33
34
35
36
37
38
39
40

Glucose	negative
Ketones	negative
Leukocyte esterase	negative
Nitrites	negative
White blood cells	1-2/hpf
Red blood cells	20-30/hpf

A renal biopsy is performed. Which of the following findings is most likely to be seen on microscopic evaluation?

A. Apple-green birefringent mesangial deposits (1%)
B. Crescent formation with linear IgG deposits (3%)
C. Effacement of podocyte foot processes (9%)
D. Granular IgG and C3 deposits (21%)
E. Lamellated basement membrane (0%)
✓ F. Mesangial deposition of IgA (60%)
G. Sclerosis of a portion of some glomeruli (1%)
H. Thin basement membrane (1%)

Omitted
Correct answer

60%
Answered correctly

05 secs
Time Spent

01/21/2020
Last Updated

Pathological findings in nephritic syndromes

	Cause of glomerular injury	Characteristic biopsy features
Poststreptococcal glomerulonephritis	Antibodies against streptococcal antigens that deposit in GBM	IF - C3 granular staining along GBM EM - **Subepithelial humps**
Anti-GBM disease	Antibodies against type IV collagen in GBM	LM - Glomerular crescents IF - **Linear staining (IgG)** along GBM
Rapidly progressive glomerulonephritis	**Severe** immunologic injury (eg, anti-GBM antibodies, immune complex deposition)	LM - Glomerular **crescents** IF - Fibrin in crescents
IgA nephropathy	Deposition of IgA-containing complexes	LM - Mesangial hypercellularity IF - **IgA in mesangium**
Alport syndrome	Defective type IV collagen in GBM	EM - **Lamellated appearance of GBM**

EM = electron microscopy; **GBM** = glomerular basement membrane; **IF** = immunofluorescence; **LM** = light microscopy.

This patient likely has **IgA nephropathy** (Berger disease), the most common cause of glomerulonephritis. It typically affects older children and young adults and presents with **painless hematuria** within 5-7 days of an **upper respiratory tract infection**. The hematuria lasts for several days and then subsides temporarily, returning every few months or with another upper respiratory infection (synpharngitic hematuria). Complement levels are usually normal. Renal biopsy will show mesangial hypercellularity with mesangial IgA deposits seen on immunohistochemical staining.

When IgA nephropathy is accompanied by extrarenal symptoms (eg, abdominal pain, arthralgias, purpuric skin lesions), the syndrome is called

EM = electron microscopy; **GBM** = glomerular basement membrane; **IF** = immunofluorescence; **LM** = light microscopy.

This patient likely has **IgA nephropathy** (Berger disease), the most common cause of glomerulonephritis. It typically affects older children and young adults and presents with **painless hematuria** within 5-7 days of an **upper respiratory tract infection**. The hematuria lasts for several days and then subsides temporarily, returning every few months or with another upper respiratory infection (synpharngitic hematuria). Complement levels are usually normal. Renal biopsy will show mesangial hypercellularity with mesangial IgA deposits seen on immunohistochemical staining.

When IgA nephropathy is accompanied by extrarenal symptoms (eg, abdominal pain, arthralgias, purpuric skin lesions), the syndrome is called Henoch-Schönlein purpura.

(Choice A) The kidney is often affected by amyloidosis. On Congo red staining, amyloid deposits appear red-pink under light microscopy and have an apple-green birefringence under polarized light. Amyloidosis typically presents in older adults as nephrotic syndrome with significant edema and proteinuria.

(Choice B) Crescent formation with linear IgG deposits occurs in patients with antiglomerular basement membrane antibody disease (Goodpasture disease). This condition generally presents as rapidly progressive glomerulonephritis associated with an acute rise in creatinine and decreased urine output; patients also often have hemoptysis. The disease is rare in children.

(Choice C) Minimal change disease (MCD) is characterized by effacement of podocyte foot processes on electron microscopy. MCD typically results in nephrotic syndrome with generalized edema and high levels of proteinuria; recurrent hematuria associated with an upper respiratory infection is more consistent with IgA nephropathy.

(Choice D) Poststreptococcal glomerulonephritis (PSGN) demonstrates granular IgG and C3 deposits along the glomerular basement membrane. However, hematuria in PSGN usually develops 1-3 weeks after streptococcal pharyngitis (postpharyngitic nephritis), and reoccurrence is rare.

(Choice E) Alport syndrome is a disorder of type IV collagen that causes a nephritic syndrome; however, it is associated with hearing loss and ocular abnormalities. Electron microscopy shows a lamellated basement membrane with irregular thinning and thickening ("basket-weave" appearance).

11
12
13
14
15
16
17
18
19
20
21
22
23
24
25
26
27
28
29
30
31
32
33
34
35
36
37
38
39
40

EM = electron microscopy; GBM = glomerular basement membrane; IF = immunofluorescence; LM = light microscopy.

This patient likely has **IgA**
young adults and presents
days and then subsides te
Complement levels are us
immunohistochemical stai

When IgA nephropathy is
Henoch-Schönlein purpur

(Choice A) The kidney is
have an apple-green biref
edema and proteinuria.

(Choice B) Crescent form
(Goodpasture disease). T
and decreased urine outp

(Choice C) Minimal chan
results in nephrotic syndro
infection is more consiste

(Choice D) Poststreptoco
membrane. However, her
reoccurrence is rare.

(Choice E) Alport syndro
ocular abnormalities. Ele
appearance).

Exhibit Display

Nephritic vs nephrotic syndrome

	Nephritic	Nephrotic
Onset	Abrupt	Insidious
GFR	Low	Normal or low
Serum albumin	Normal	Low
Edema	±	++
Hypertension	++	±
Casts	RBC casts	Fatty or none
Proteinuria	±	++
Hematuria	++	±
Pyuria	+	None

GFR = glomerular filtration rate; RBC = red blood cell.
+ = present; ++ = significant.

Add To New Card | Existing Card

Settings

11
12
13
14
15
16
17
18
19
20
21
22
23
24
25
26
27
28
29
30
31
32
33
34
35
36
37
38
39
40

Item 35 of 40
Question Id: 10

Mark | Previous | Next | Full Screen | Tutorial | Lab Values | Notes | Calculator | Reverse Color | Text Zoom | Settings

EM = electron microscopy; GBM = glomerular basement membrane; IF = immunofluorescence; LM = light microscopy.

Exhibit Display

Henoch-Schonlein purpura nephritis Henoch-Schonlein purpura nephritis

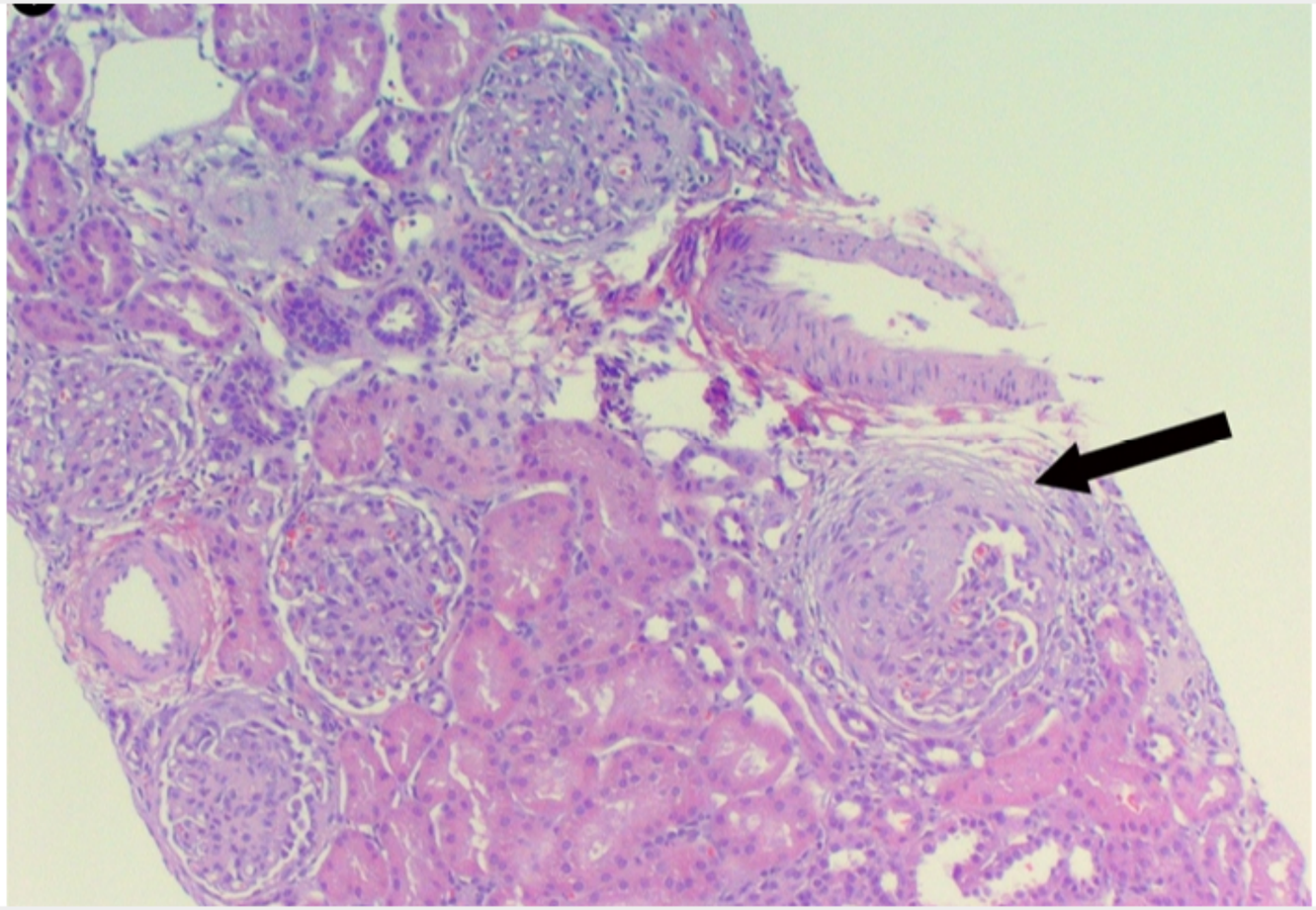

Zoom In | Zoom Out | Reset | Add To New Card | Existing Card

Block Time Remaining: 00:05:59
TUTOR

7 | Feedback | Suspend | End Block

Settings

11
12
13
14
15
16
17
18
19
20
21
22
23
24
25
26
27
28
29
30
31
32
33
34
35
36
37
38
39
40

Item 35 of 40
Question Id: 10

Mark | Previous | Next | Full Screen | Tutorial | Lab Values | Notes | Calculator | Reverse Color | Text Zoom | Settings

EM = electron microscopy; GBM = glomerular basement membrane; IF = immunofluorescence; LM = light microscopy.

Exhibit Display

Henoch-Schonlein purpura nephritis Henoch-Schonlein purpura nephritis

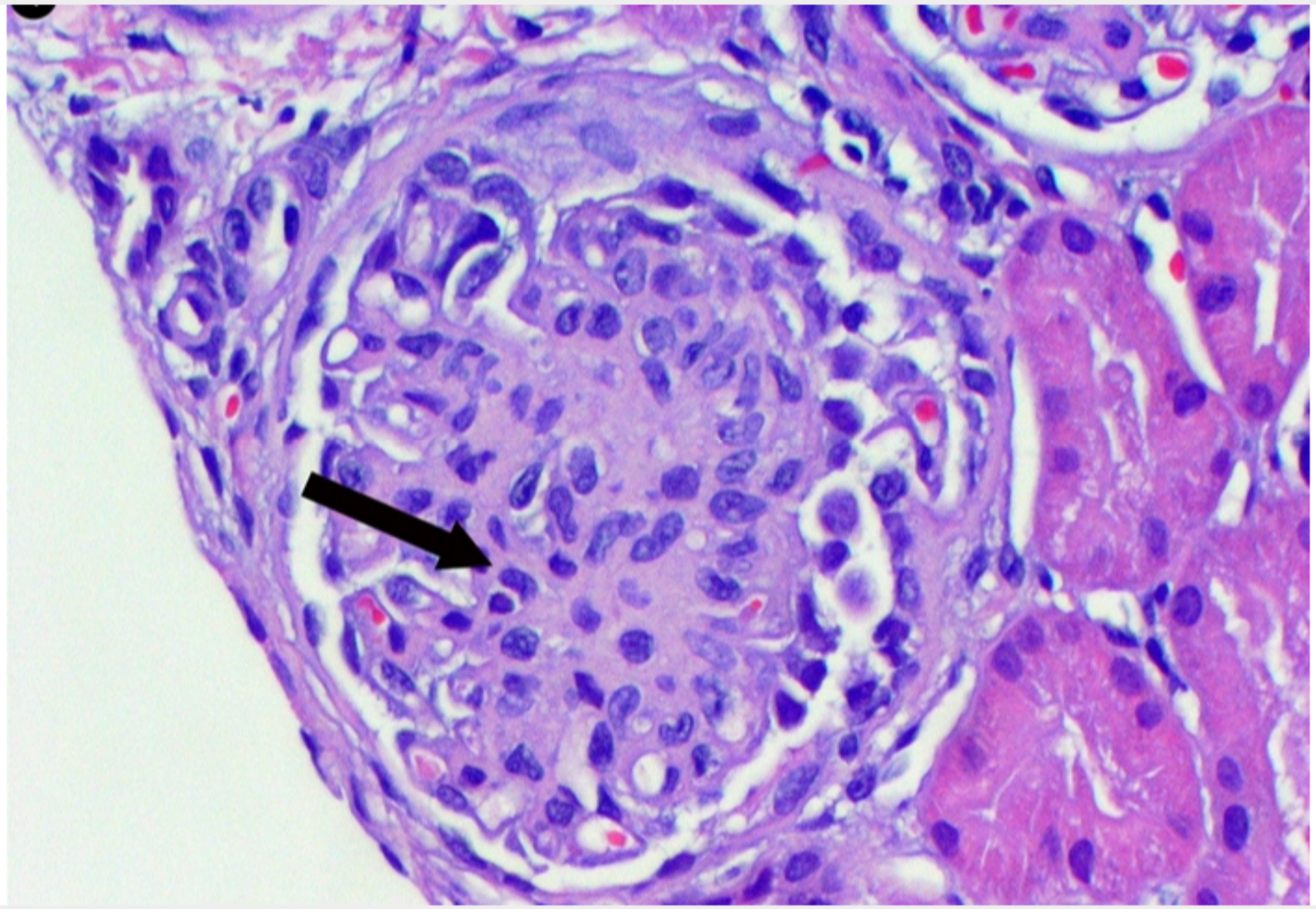

Zoom In | Zoom Out | Reset | Add To New Card | Existing Card

Block Time Remaining: 00:05:59
TUTOR

7 | Feedback | Suspend | End Block

Settings

11
12
13
14
15
16
17
18
19
20
21
22
23
24
25
26
27
28
29
30
31
32
33
34
35
36
37
38
39
40

Item 35 of 40
Question Id: 10

Mark | Previous | Next | Full Screen | Tutorial | Lab Values | Notes | Calculator | Reverse Color | Text Zoom | Settings

EM = electron microscopy; GBM = glomerular basement membrane; IF = immunofluorescence; LM = light microscopy.

Exhibit Display

Henoch-Schonlein purpura nephritis Henoch-Schonlein purpura nephritis

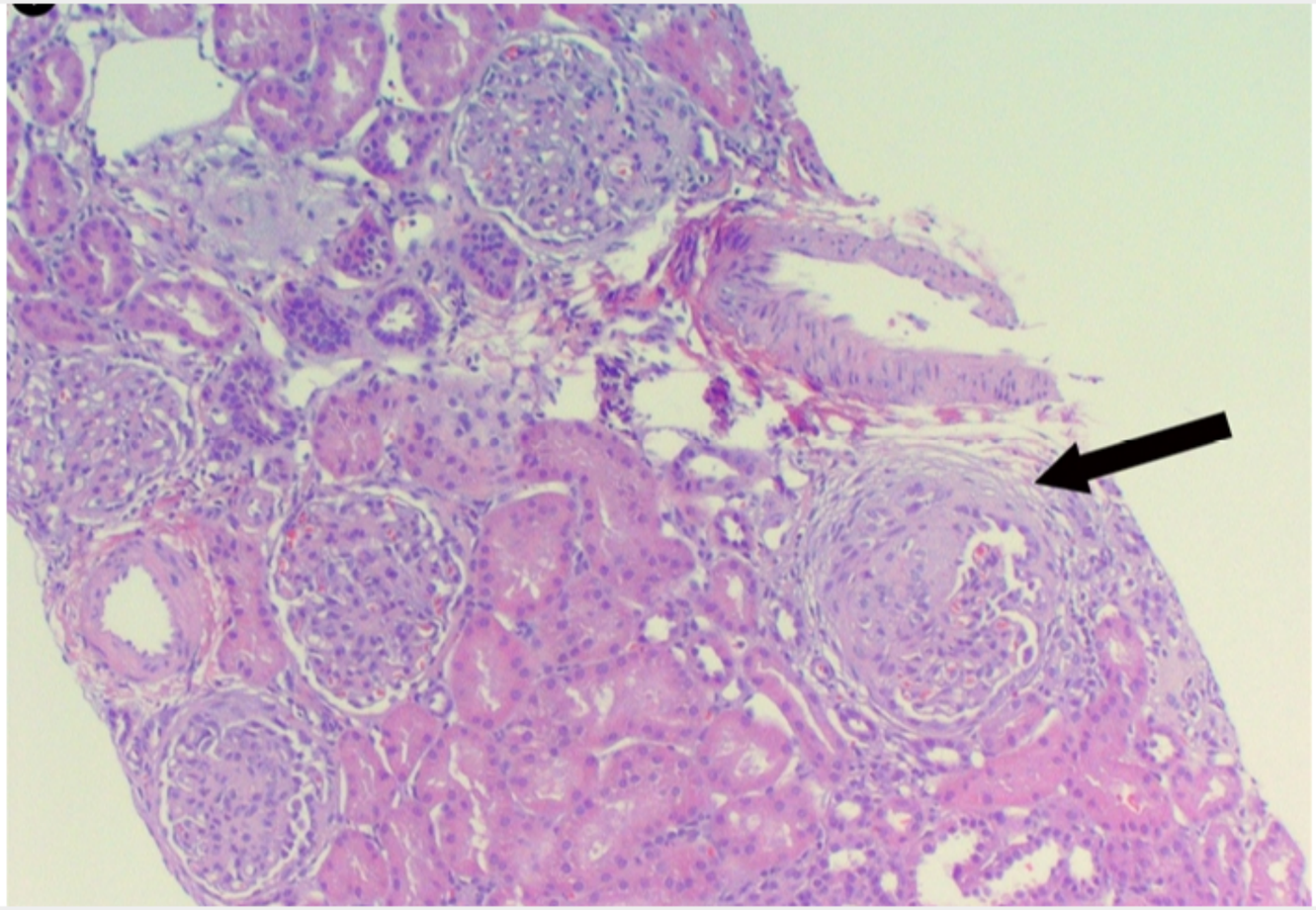

Zoom In | Zoom Out | Reset | Add To New Card | Existing Card

Block Time Remaining: 00:05:59
TUTOR

7 | Feedback | Suspend | End Block

Settings

11
12
13
14
15
16
17
18
19
20
21
22
23
24
25
26
27
28
29
30
31
32
33
34
35
36
37
38
39
40

Item 35 of 40
Question Id: 10

Mark | Previous | Next | Full Screen | Tutorial | Lab Values | Notes | Calculator | Reverse Color | Text Zoom | Settings

EM = electron microscopy; GBM = glomerular basement membrane; IF = immunofluorescence; LM = light microscopy.

Exhibit Display

Henoch-Schonlein purpura nephritis Henoch-Schonlein purpura nephritis

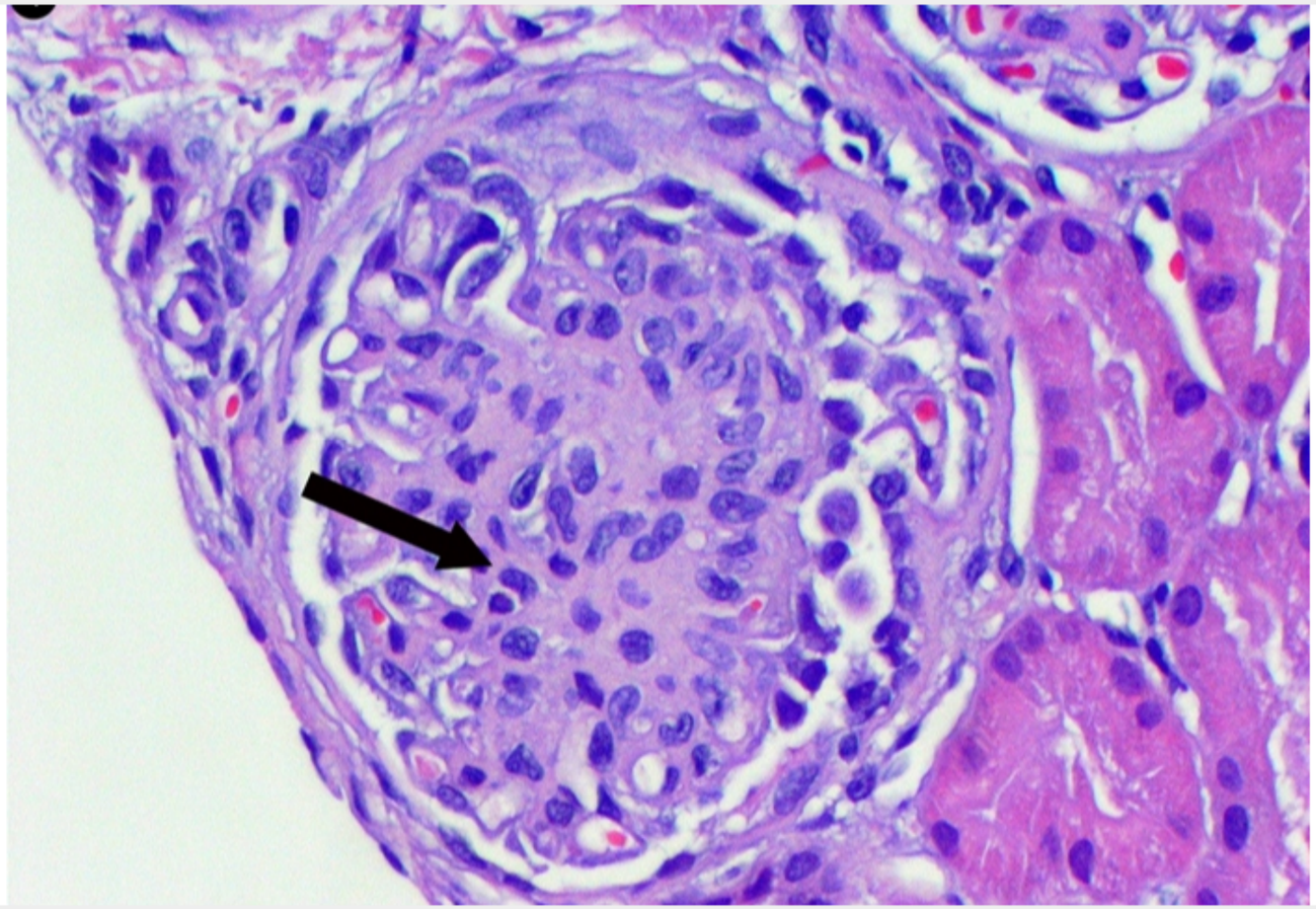

Zoom In | Zoom Out | Reset | Add To New Card | Existing Card

Block Time Remaining: 00:05:59
TUTOR

7 | Feedback | Suspend | End Block

Settings

11
12
13
14
15
16
17
18
19
20
21
22
23
24
25
26
27
28
29
30
31
32
33
34
35
36
37
38
39
40

Item 35 of 40
Question Id: 10

Mark | Previous | Next | Full Screen | Tutorial | Lab Values | Notes | Calculator | Reverse Color | Text Zoom | Settings

EM = electron microscopy; GBM = glomerular basement membrane; IF = immunofluorescence; LM = light microscopy.

Exhibit Display

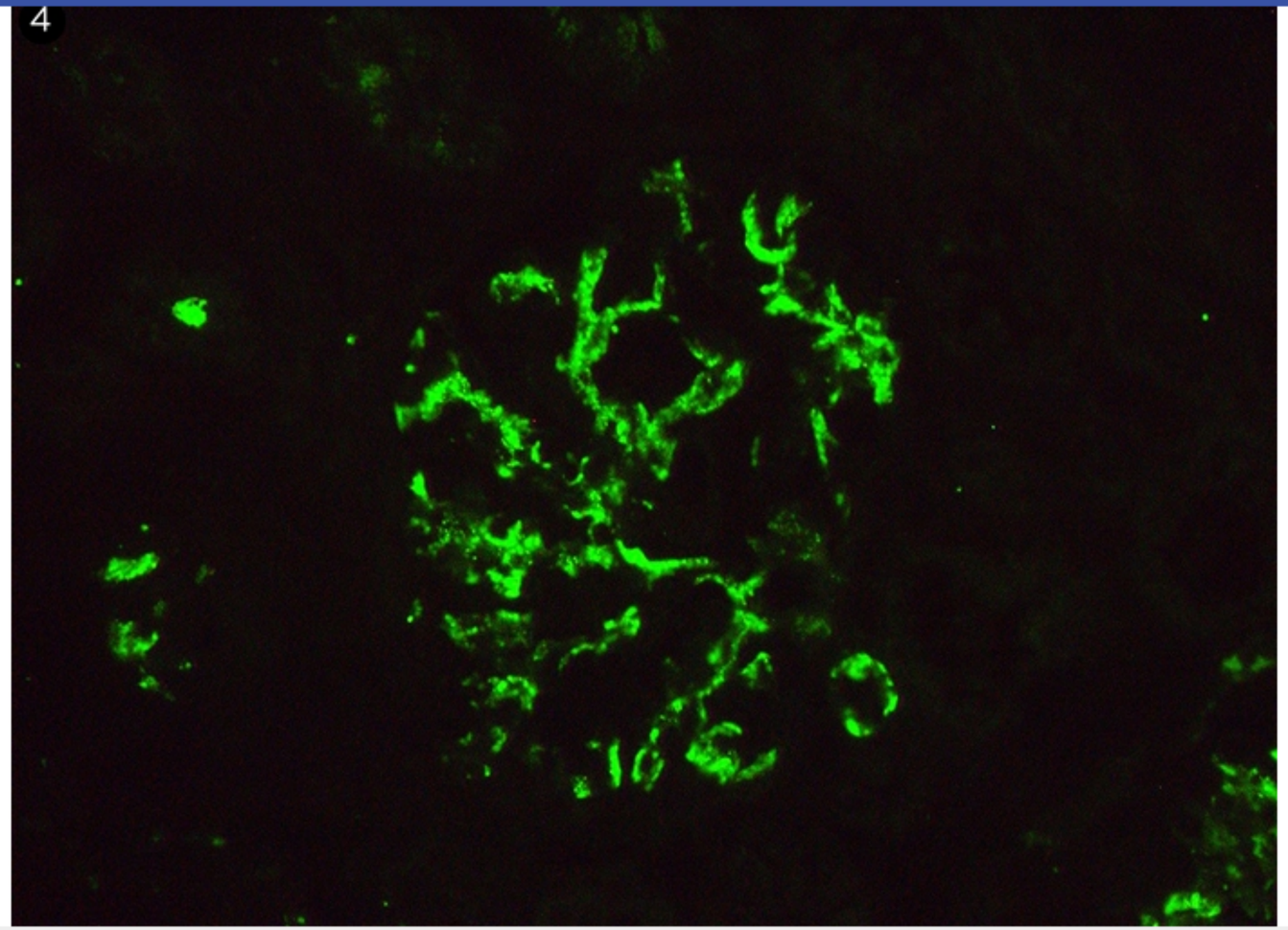

Zoom In | Zoom Out | Reset | Add To New Card | Existing Card

Block Time Remaining: 00:05:59
TUTOR

7 | Feedback | Suspend | End Block

Settings

- 11
- 12
- 13
- 14
- 15
- 16
- 17
- 18
- 19
- 20
- 21
- 22
- 23
- 24
- 25
- 26
- 27
- 28
- 29
- 30
- 31
- 32
- 33
- 34
- 35
- 36
- 37
- 38
- 39
- 40

Item 35 of 40
Question Id: 10

Mark | Previous | Next | Full Screen | Tutorial | Lab Values | Notes | Calculator | Reverse Color | Text Zoom | Settings

Exhibit Display

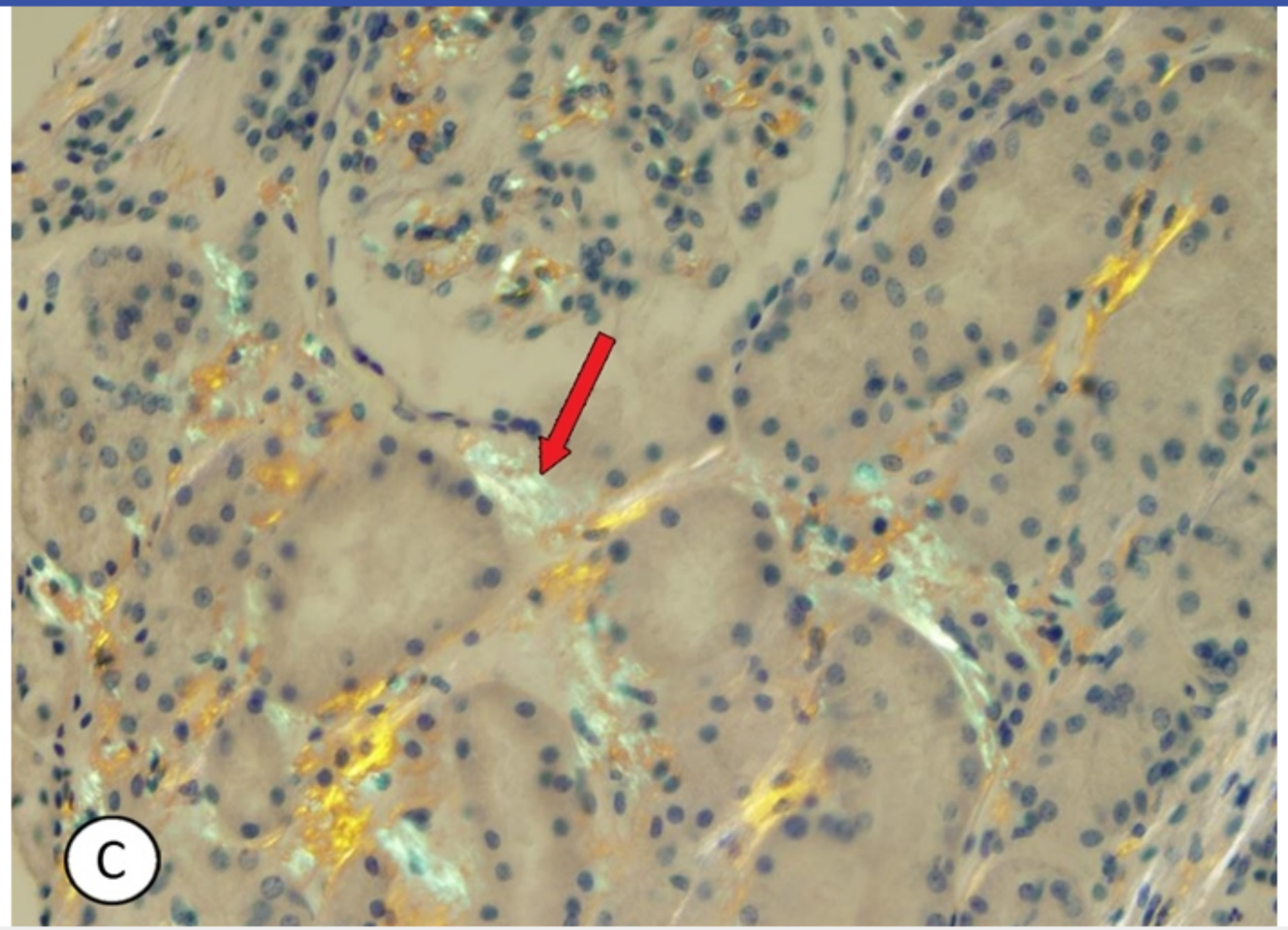

Zoom In | Zoom Out | Reset | Add To New Card | Existing Card

after streptococcal pharyngitis and is usually not recurrent.

Block Time Remaining: 00:05:59
TUTOR

7 | Feedback | Suspend | End Block

Settings

11
12
13
14
15
16
17
18
19
20
21
22
23
24
25
26
27
28
29
30
31
32
33
34
35
36
37
38
39
40

Item 35 of 40
Question Id: 10

Mark | Previous | Next | Full Screen | Tutorial | Lab Values | Notes | Calculator | Reverse Color | Text Zoom | Settings

Exhibit Display

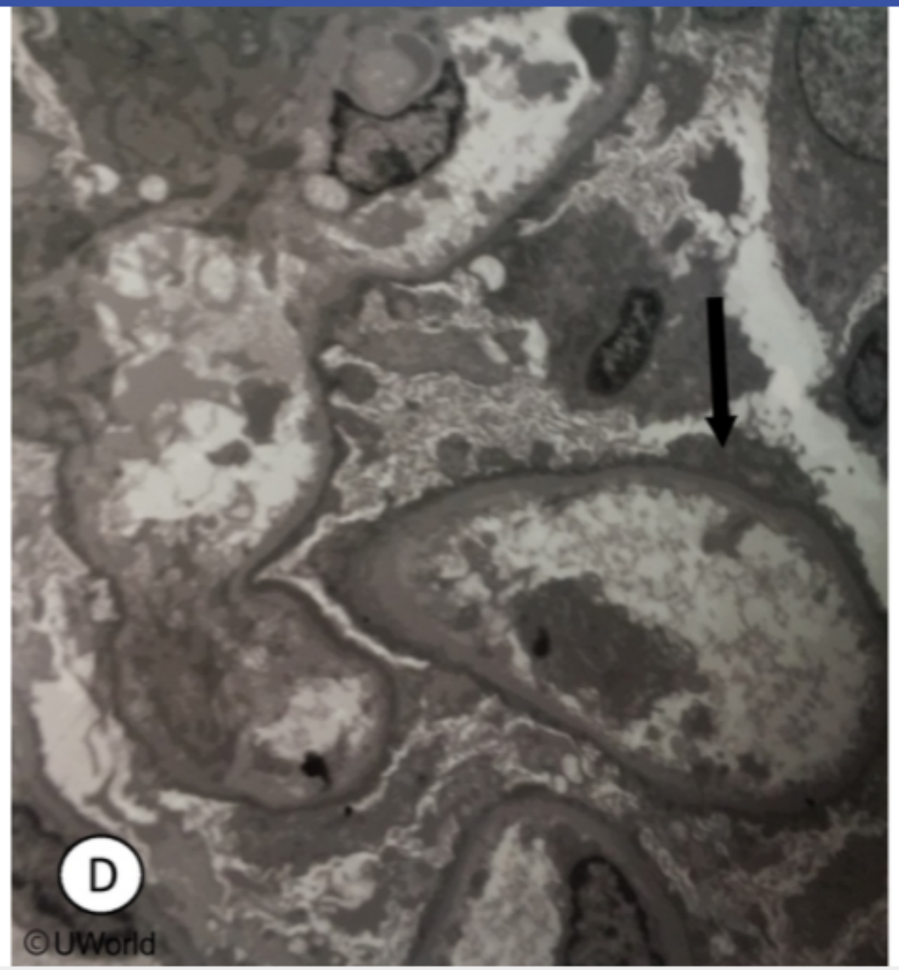

Zoom In | Zoom Out | Reset | Add To New Card | Existing Card

after streptococcal pharyngitis and is usually not recurrent.

Block Time Remaining: 00:05:59
TUTOR

7 | Feedback | Suspend | End Block

11
12
13
14
15
16
17
18
19
20
21
22
23
24
25
26
27
28
29
30
31
32
33
34
35
36
37
38
39
40

results in nephrotic syndrome with generalized edema and high levels of proteinuria; recurrent hematuria associated with an upper respiratory infection is more consistent with IgA nephropathy.

(Choice D) Poststreptococcal glomerulonephritis (PSGN) demonstrates granular IgG and C3 deposits along the glomerular basement membrane. However, hematuria in PSGN usually develops 1-3 weeks after streptococcal pharyngitis (postpharyngitic nephritis), and reoccurrence is rare.

(Choice E) Alport syndrome is a disorder of type IV collagen that causes a nephritic syndrome; however, it is associated with hearing loss and ocular abnormalities. Electron microscopy shows a lamellated basement membrane with irregular thinning and thickening ("basket-weave" appearance).

(Choice G) Focal segmental glomerular sclerosis also typically causes nephrotic syndrome. Recurrent episodes of macroscopic hematuria are unexpected.

(Choice H) Thin basement membrane disease is an autosomal dominant disorder that results in a thin basement membrane with recurrent microscopic hematuria, gross hematuria, or flank pain. Due to the inheritance pattern, patients typically have a family history of hematuria.

Educational objective:
IgA nephropathy (Berger disease) frequently presents as recurrent, self-limited, painless hematuria within 5 days of an upper respiratory infection. Kidney biopsy will show mesangial IgA deposits on immunofluorescence. In contrast, poststreptococcal glomerulonephritis is seen 1-3 weeks after streptococcal pharyngitis and is usually not recurrent.

References

- The genetics and immunobiology of IgA nephropathy.
- Diagnosis and classification of IgA nephropathy.

Pathology	Renal, Urinary Systems & Electrolytes	Glomerular disorders
Subject	System	Topic

Copyright © UWorld. All rights reserved.

11
12
13
14
15
16
17
18
19
20
21
22
23
24
25
26
27
28
29
30
31
32
33
34
35
36
37
38
39
40

A 68-year-old man comes to the emergency department due to lower abdominal pain and nausea. His symptoms started the prior evening, when he began to feel abdominal fullness and discomfort. This progressed to pain over the lower abdomen and constant nausea without vomiting. The patient last urinated >24 hours ago. He has had difficulty initiating urination and a feeling of incomplete voiding for the last year but avoided seeing a physician. Temperature is 36.7 C (98 F), blood pressure is 150/90 mm Hg, and pulse is 95/min. Physical examination shows suprapubic tenderness and fullness without guarding or rebound. Rectal examination reveals an enlarged, smooth prostate. Serum creatinine is 2.6 mg/dL and blood urea nitrogen is 22 mg/dL. A urinary catheter is placed, with immediate collection of 800 mL of urine and relief of the patient's symptoms. The following day, serum creatinine is improved. This patient's condition is associated with increased risk for which of the following?

A. Bladder transitional cell carcinoma

B. Glomerulonephritis

C. Priapism

D. Prostatic adenocarcinoma

E. Urinary tract infection

Submit

11
12
13
14
15
16
17
18
19
20
21
22
23
24
25
26
27
28
29
30
31
32
33
34
35
36
37
38
39
40

A 68-year-old man comes to the emergency department due to lower abdominal pain and nausea. His symptoms started the prior evening, when he began to feel abdominal fullness and discomfort. This progressed to pain over the lower abdomen and constant nausea without vomiting. The patient last urinated >24 hours ago. He has had difficulty initiating urination and a feeling of incomplete voiding for the last year but avoided seeing a physician. Temperature is 36.7 C (98 F), blood pressure is 150/90 mm Hg, and pulse is 95/min. Physical examination shows suprapubic tenderness and fullness without guarding or rebound. Rectal examination reveals an enlarged, smooth prostate. Serum creatinine is 2.6 mg/dL and blood urea nitrogen is 22 mg/dL. A urinary catheter is placed, with immediate collection of 800 mL of urine and relief of the patient's symptoms. The following day, serum creatinine is improved. This patient's condition is associated with increased risk for which of the following?

A. Bladder transitional cell carcinoma (4%)

B. Glomerulonephritis (5%)

C. Priapism (0%)

D. Prostatic adenocarcinoma (9%)

✓ E. Urinary tract infection (78%)

Omitted
Correct answer
E

78%
Answered correctly

01 sec
Time Spent

02/16/2020
Last Updated

Explanation

This patient with progressive lower urinary tract symptoms and an enlarged prostate has **benign prostatic hyperplasia** (BPH). Bladder-outlet obstruction with **acute urinary retention** is a common complication of BPH and can occur with progressive disease or be triggered by medications that decrease bladder contractility (eg, sympathomimetic or antichol

This patient with progressive lower urinary tract symptoms and an enlarged prostate has **benign prostatic hyperplasia** (BPH). Bladder-outlet obstruction with **acute urinary retention** is a common complication of BPH and can occur with progressive disease or be triggered by medications that decrease bladder contractility (eg, sympathomimetic or anticholinergic medications).

Enlargement of the prostate (**static obstruction**) and contraction of prostatic smooth muscle (**dynamic obstruction**) compress the prostatic urethra, which increases the hydrostatic pressure required to overcome resistance to flow. As the bladder empties during micturition, urinary pressures diminish; if urinary pressure falls below the prostatic compressive pressure, urine flow stops, leaving a **residual volume** of urine in the bladder. Complete emptying of the bladder is a defense mechanism against urinary tract infection; if the bladder does not empty completely, the residual urine can act as a growth medium for **pathogenic bacteria**. Other complications of BPH include bladder hypertrophy, hydroureter and hydronephrosis, and chronic kidney disease (obstructive uropathy).

(Choice A) Major risk factors for bladder transitional cell carcinoma include smoking and occupational exposure to aromatic amine-containing dyes. The risk is not significantly increased in patients with BPH.

(Choice B) Glomerulonephritis causes primary (intrarenal) azotemia and is not typically associated with BPH. Common causes of glomerulonephritis in adults include IgA nephropathy and membranoproliferative glomerulonephritis.

(Choice C) Priapism is prolonged erection of the penis that is not due to ongoing sexual stimulation. It may occur secondary to conditions that impair venous outflow from the penis (eg, sickle cell) or due to use of certain medications (eg, phosphodiesterase-5 inhibitors, trazodone). BPH does not increase the risk for priapism.

(Choice D) The risk for prostatic adenocarcinoma increases with age and is greatest in black patients and in individuals with a family history of prostate cancer. However, the risk is not appreciably increased in those with BPH or urinary obstruction.

Educational objective:
Benign prostatic hyperplasia can increase resistance to urine flow in the urethra and lead to incomplete bladder emptying during micturition. The residual urine can act as a growth medium for pathogenic bacteria and increase the risk for urinary tract infection.

References

- Urinary tract infection associated with conditions causing urinary tract obstruction and stasis, excluding urolithiasis and neuropathic bladder.

11
12
13
14
15
16
17
18
19
20
21
22
23
24
25
26
27
28
29
30
31
32
33
34
35
36
37
38
39
40

A 65-year-old man comes to the office with a 2-day history of skin rash and low-grade fever. He has had no cough, shortness of breath, chest pain, vomiting, dysuria, or urinary frequency. The patient was recently diagnosed with acute gouty arthritis and has been taking indomethacin for the past 10 days. Temperature is 38.1 C (100.6 F), blood pressure is 130/90 mm Hg, and pulse is 86/min. Examination shows a diffuse, maculopapular skin rash. Mucosal surfaces are moist without any lesions. Cardiopulmonary examination shows no abnormities. There is no costovertebral angle tenderness. Serum creatinine is 2.3 mg/dL (baseline 1.1 mg/dL, 2 weeks ago). Urinalysis shows numerous white blood cells/hpf. Which of the following is the most likely cause of this patient's acute renal dysfunction?

A. Interstitial nephritis
B. Pyelonephritis
C. Renal tubular necrosis
D. Stevens-Johnson syndrome
E. Uric acid nephropathy

Submit

A 65-year-old man comes to the office with a 2-day history of skin rash and low-grade fever. He has had no cough, shortness of breath, chest pain, vomiting, dysuria, or urinary frequency. The patient was recently diagnosed with acute gouty arthritis and has been taking indomethacin for the past 10 days. Temperature is 38.1 C (100.6 F), blood pressure is 130/90 mm Hg, and pulse is 86/min. Examination shows a diffuse, maculopapular skin rash. Mucosal surfaces are moist without any lesions. Cardiopulmonary examination shows no abnormities. There is no costovertebral angle tenderness. Serum creatinine is 2.3 mg/dL (baseline 1.1 mg/dL, 2 weeks ago). Urinalysis shows numerous white blood cells/hpf. Which of the following is the most likely cause of this patient's acute renal dysfunction?

- ✓ A. Interstitial nephritis (78%)
- B. Pyelonephritis (4%)
- C. Renal tubular necrosis (6%)
- D. Stevens-Johnson syndrome (6%)
- E. Uric acid nephropathy (3%)

Omitted
Correct answer
A

78%
Answered correctly

01 sec
Time Spent

05/15/2020
Last Updated

Explanation

Acute interstitial nephritis	
	• **Antibiotics** (eg, beta-lactam, sulfonamide, rifampin)

Acute interstitial nephritis	
Causes	• **Antibiotics** (eg, beta-lactam, sulfonamide, rifampin) • Proton pump inhibitors • NSAIDs • Diuretics • Other: Autoimmune diseases, *Mycoplasma*, *Legionella*
Clinical features	• Rash, fever, or asymptomatic • New drug exposure
Laboratory findings	• Acute kidney injury • Pyuria, hematuria, WBC casts • Eosinophilia, **urinary eosinophils** • Renal biopsy: Inflammatory interstitial infiltrate and edema
NSAIDs = nonsteroidal anti-inflammatory drugs; **WBC** = white blood cell.	

This patient has a rash, fever, acute kidney injury, and pyuria following the introduction of indomethacin, which is consistent with **acute interstitial nephritis** (AIN). AIN is a common cause of renal dysfunction and is characterized by an inflammatory infiltration of the renal interstitium, likely due to IgE- and T-cell–mediated hypersensitivity reactions.

Up to 75% of AIN cases are due to medications, particularly **nonsteroidal anti-inflammatory drugs** (eg, indomethacin), antibiotics (eg, penicillins, rifampin), diuretics, and proton pump inhibitors. Clinical features of AIN resemble an allergic response and include **fever**, **rash**, and eosinophilia. Urinalysis typically demonstrates sterile **pyuria**; white blood cell casts, hematuria, and mild proteinuria may also be seen. The presence of urine eosinophils is a supportive but nonspecific finding as eosinophiluria can occur in other diseases (eg, transplant rejection, prostatitis). Symptoms typically resolve with withdrawal of the offending agent.

(Choice B) Pyelonephritis can cause pyuria and fever, but patients typically have dysuria, flank pain, costovertebral tenderness, and symptoms of

11
12
13
14
15
16
17
18
19
20
21
22
23
24
25
26
27
28
29
30
31
32
33
34
35
36
37
38
39
40

due to IgE- and T-cell–mediated hypersensitivity reactions.

Up to 75% of AIN cases are due to medications, particularly **nonsteroidal anti-inflammatory drugs** (eg, indomethacin), antibiotics (eg, penicillins, rifampin), diuretics, and proton pump inhibitors. Clinical features of AIN resemble an allergic response and include **fever**, **rash**, and eosinophilia. Urinalysis typically demonstrates sterile **pyuria**; white blood cell casts, hematuria, and mild proteinuria may also be seen. The presence of urine eosinophils is a supportive but nonspecific finding as eosinophiluria can occur in other diseases (eg, transplant rejection, prostatitis). Symptoms typically resolve with withdrawal of the offending agent.

(Choice B) Pyelonephritis can cause pyuria and fever, but patients typically have dysuria, flank pain, costovertebral tenderness, and symptoms of systemic toxicity (eg, nausea, vomiting, hypotension). In addition, rash would be unexpected.

(Choice C) Acute tubular necrosis is often caused by ischemic (eg, hypotension) or toxic (eg, radiocontrast) injury to the renal tubular cells. Urinalysis typically demonstrates muddy brown, granular casts, not pyuria.

(Choice D) Stevens-Johnson syndrome can cause fever and rash after initiation of a new medication; however, the rash is typically painful, macular, and progressive, with bullae formation and sloughing of the skin. Mucosal surfaces (ie, oral, ocular) are typically involved.

(Choice E) Acute uric acid nephropathy (due to crystallization of uric acid within the renal tubules) typically occurs in patients with tumor lysis syndrome, which often occurs in leukemia and lymphomas (particularly during chemotherapy). Uric acid crystals are typically seen on urinalysis, and rash would be unexpected.

Educational objective:
Acute interstitial nephritis is a common cause of renal dysfunction; up to 75% of cases are due to medications including nonsteroidal anti-inflammatory drugs, antibiotics, diuretics, and proton pump inhibitors. Presenting features include fever, rash, and eosinophilia. Urinalysis often demonstrates pyuria and white blood cell casts with elevated urine eosinophils.

References

- Acute interstitial nephritis – a reappraisal and update.

Pathology	Renal, Urinary Systems & Electrolytes	Acute interstitial nephritis
Subject	System	Topic

A 65-year-old hospitalized man is evaluated for decreased urine output and increased serum creatinine. The patient was admitted for 3-vessel coronary artery disease and underwent coronary artery bypass grafting surgery yesterday. Other medical conditions include type 2 diabetes mellitus and hypertension. He received a dose of intravenous vancomycin prior to the surgery for prophylaxis of surgical infection. The patient has also been receiving 100 mL/hour of intravenous normal saline for the past 24 hours. He is afebrile. Blood pressure is 130/80 mm Hg and pulse is 80/min. Examination shows bibasilar crackles. The abdomen is soft. Urine output over the past 6 hours is 100 mL. Laboratory results are as follows:

	Day of admission	Today
Blood urea nitrogen	20 mg/dL	35 mg/dL
Serum creatinine	1.3 mg/dL	2.5 mg/dL

Urine sediment microscopy is shown in the exhibit. Which of the following is the most likely cause of this patient's current condition?

A. Crystal obstruction in tubules
B. Drug toxicity to renal tubules
C. Glomerulonephritis
D. Interstitial inflammation
E. Ischemic tubular necrosis
F. Prerenal azotemia

Submit

A 65-year-old hospitalized man is evaluated for decreased urine output and increased serum creatinine. The patient was admitted for 3-vessel coronary artery disease and underwent coronary artery bypass grafting surgery yesterday. Other medical conditions include type 2 diabetes mellitus and hypertension. He received a dose of intravenous vancomycin prior to the surgery for prophylaxis of surgical infection. The patient has also been receiving 100 mL/hour of intravenous normal saline for the past 24 hours. He is afebrile. Blood pressure is 130/80 mm Hg and pulse is 80/min. Examination shows bibasilar crackles. The abdomen is soft. Urine output over the past 6 hours is 100 mL. Laboratory results are as follows:

	Day of admission	Today
Blood urea nitrogen	20 mg/dL	35 mg/dL
Serum creatinine	1.3 mg/dL	2.5 mg/dL

Urine sediment microscopy is shown in the exhibit. Which of the following is the most likely cause of this patient's current condition?

A. Crystal obstruction in tubules (2%)
B. Drug toxicity to renal tubules (40%)
C. Glomerulonephritis (1%)
D. Interstitial inflammation (3%)
✓ E. Ischemic tubular necrosis (48%)
F. Prerenal azotemia (4%)

Omitted
Correct answer
E

48%
Answered correctly

02 secs
Time Spent

01/26/2020
Last Updated

Settings

- 11
- 12
- 13
- 14
- 15
- 16
- 17
- 18
- 19
- 20
- 21
- 22
- 23
- 24
- 25
- 26
- 27
- 28
- 29
- 30
- 31
- 32
- 33
- 34
- 35
- 36
- 37
- 38
- 39
- 40

Item 38 of 40
Question Id: 15225

Mark | Previous | Next | Full Screen | Tutorial | Lab Values | Notes | Calculator | Reverse Color | Text Zoom | Settings

Exhibit Display

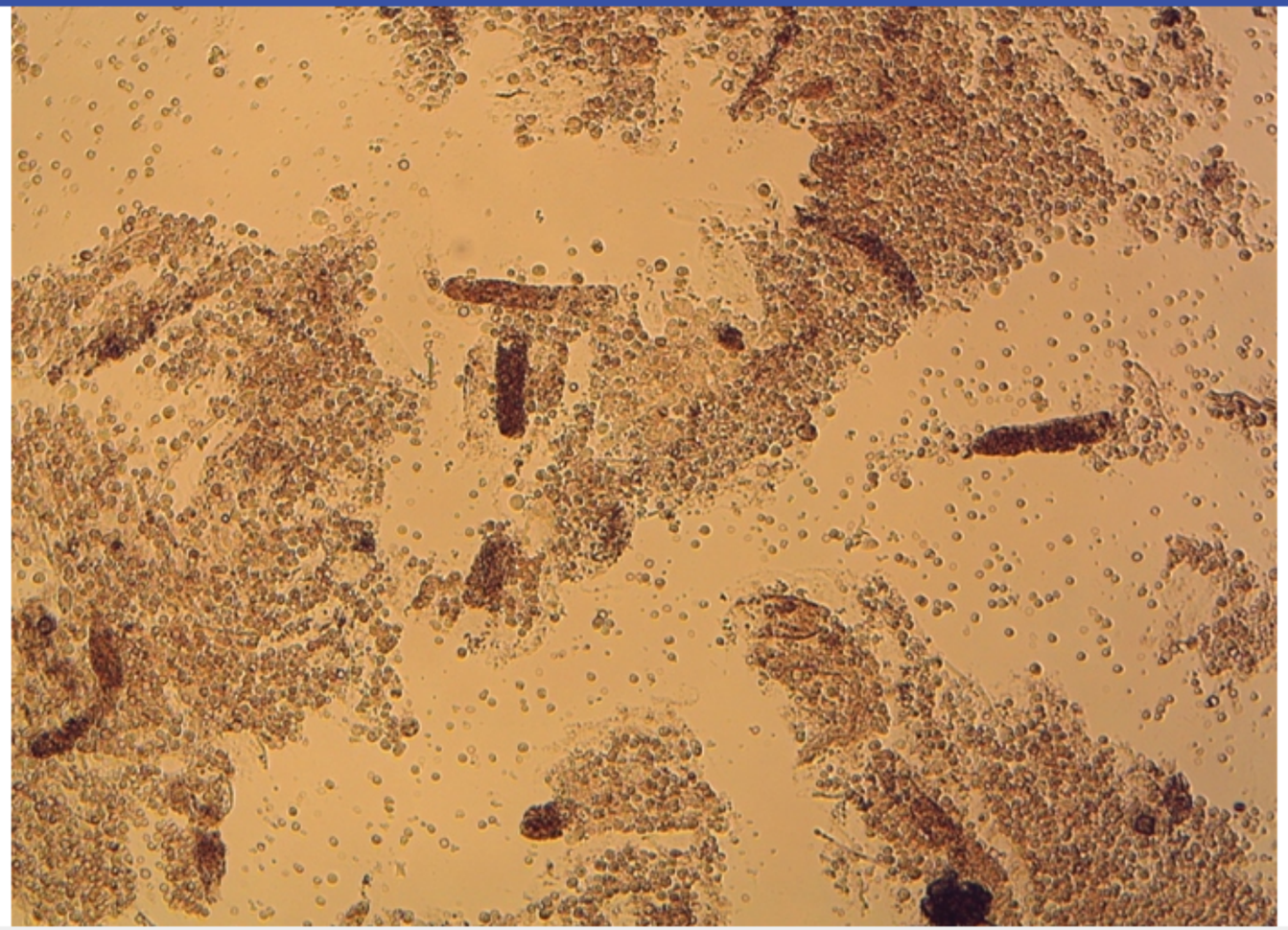

Zoom In | Zoom Out | Reset | Add To New Card | Existing Card

Correct answer | Answered correctly | Time Spent | Last Updated

Block Time Remaining: 00:06:03
TUTOR

3 | Feedback | Suspend | End Block

Urinary casts	Composition	Associated conditions
Hyaline	Tamm-Horsfall protein	Nonspecific, concentrated urine
Fatty	Lipid droplets	Nephrotic syndrome
Waxy	Degenerated hyaline cast	Chronic kidney disease
Granular (muddy brown)	Sloughed tubular epithelial cells with pigmented granules	Acute tubular necrosis
WBC	White blood cells	Pyelonephritis, interstitial nephritis
RBC	Red blood cells	Glomerulonephritis

This patient with **acute kidney injury** has muddy brown casts on urine microscopy; in the setting of recent major surgery this presentation suggests **acute tubular necrosis** (ATN) due to **intraoperative renal ischemia**. Surgeries complicated by significant blood loss or those requiring the use of cardiopulmonary bypass (eg, coronary artery bypass grafting) or aortic clamping can cause renal hypoperfusion. The risk is increased in the elderly and those with a history of chronic kidney disease, diabetes, or congestive heart failure.

ATN is characterized by the presence of muddy brown granular casts composed of sloughed renal tubular epithelial cells. Patients have increased serum creatinine, **blood urea nitrogen/ creatinine ratio <20:1** (indicating intrinsic renal pathology), and oliguria (low urine output). Histologically, flattened tubular epithelial cells with cellular necrosis and loss of the brush border are seen.

(Choice A) Crystalline-induced kidney injury most commonly occurs from acyclovir or sulfonamide (eg, sulfadiazine) usage. Urinalysis demonstrates needle or rosette-shaped crystals. Vancomycin is not associated with crystal formation.

(Choice B) Vancomycin can cause ATN, but this typically occurs after a prolonged course (days). It is highly unlikely that a single dose would

11 12 13 14 15 16 17 18 19 20 21 22 23 24 25 26 27 28 29 30 31 32 33 34 35 36 37 38 39 40

the use of cardiopulmonary bypass (eg, coronary artery bypass grafting) or aortic clamping can cause renal hypoperfusion. The risk is increased in the elderly and those with a history of chronic kidney disease, diabetes, or congestive heart failure.

ATN is characterized by the presence of muddy brown granular casts composed of sloughed renal tubular epithelial cells. Patients have increased serum creatinine, **blood urea nitrogen/ creatinine ratio <20:1** (indicating intrinsic renal pathology), and oliguria (low urine output). Histologically, flattened tubular epithelial cells with cellular necrosis and loss of the brush border are seen.

(Choice A) Crystalline-induced kidney injury most commonly occurs from acyclovir or sulfonamide (eg, sulfadiazine) usage. Urinalysis demonstrates needle or rosette-shaped crystals. Vancomycin is not associated with crystal formation.

(Choice B) Vancomycin can cause ATN, but this typically occurs after a prolonged course (days). It is highly unlikely that a single dose would cause ATN.

(Choice C) Glomerulonephritis can cause acute kidney injury, but hematuria and red blood cell casts are expected on urinalysis. In addition, patients are typically hypertensive.

(Choice D) Acute interstitial nephritis can occur after exposure to new drugs, particularly antibiotics and diuretics. However, white blood cells and white cell casts are expected on urinalysis, and patients often have fever and rash.

(Choice F) Prerenal azotemia occurs from less significant renal hypoperfusion without renal ischemia (eg, dehydration). Urinalysis reveals hyaline casts (reflecting concentrated urine) and the blood urea nitrogen/creatinine ratio is elevated (>20:1).

Educational objective:
Surgeries complicated by significant blood loss or those requiring the use of cardiopulmonary bypass or clamping of the aorta can cause sustained renal hypoperfusion and result in acute tubular necrosis (ATN). ATN presents with oliguria, increased serum creatinine, and blood urea nitrogen/creatinine ratio <20:1. Urinalysis is characterized by muddy brown granular casts composed of sloughed renal tubular epithelial cells.

Pathology	Renal, Urinary Systems & Electrolytes	Acute kidney injury
Subject	System	Topic

Copyright © UWorld. All rights reserved.

11
12
13
14
15
16
17
18
19
20
21
22
23
24
25
26
27
28
29
30
31
32
33
34
35
36
37
38
39
40

the use of cardiopulmonary bypass (eg, coronary artery bypass grafting) or aortic clamping can cause renal hypoperfusion. The risk is increased in the elderly and those with a history of chronic kidney disease, diabetes, or congestive heart failure.

Exhibit Display

Acute tubular necrosis

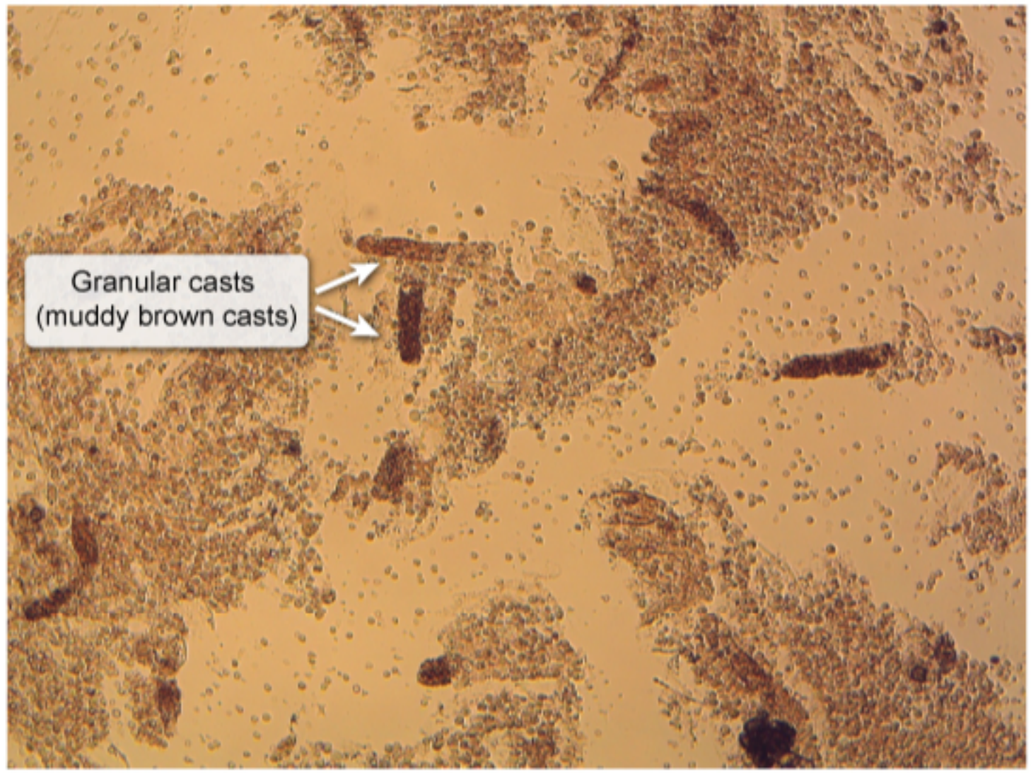

©UWorld

Zoom In | Zoom Out | Reset | Add To New Card | Existing Card

Blood urea nitrogen	68 mg/dL
Creatinine	3.8 mg/dL
Total protein	8.9 g/dL
Albumin	3.5 g/dL

Renal biopsy is performed and light microscopy shows atrophic tubules, many of which contain large, obstructing, waxy casts that stain intensely with eosin. Which of the following is the most likely diagnosis in this patient?

- A. Acute pyelonephritis
- B. Aminoglycoside toxicity
- C. Hypersensitivity interstitial nephritis
- D. Ischemic tubular necrosis
- E. Lead nephropathy
- F. Multiple myeloma
- G. Nonsteroidal anti-inflammatory drug–associated nephropathy
- H. Papillary necrosis
- I. Urate nephropathy

Submit

A 64-year-old man comes to the office due to persistent back pain, constipation, and easy fatigability for the last several months. Blood pressure is 115/75 mm Hg and pulse is 88/min. The patient has dry mucous membranes. Laboratory results are as follows:

Hemoglobin	8.6 g/dL
Mean corpuscular volume	92 fL
Blood urea nitrogen	68 mg/dL
Creatinine	3.8 mg/dL
Total protein	8.9 g/dL
Albumin	3.5 g/dL

Renal biopsy is performed and light microscopy shows atrophic tubules, many of which contain large, obstructing, waxy casts that stain intensely with eosin. Which of the following is the most likely diagnosis in this patient?

- A. Acute pyelonephritis
- B. Aminoglycoside toxicity
- C. Hypersensitivity interstitial nephritis
- D. Ischemic tubular necrosis
- E. Lead nephropathy
- F. Multiple myeloma
- G. Nonsteroidal anti-inflammatory drug–associated nephropathy
- H. Papillary necrosis

Blood urea nitrogen	68 mg/dL
Creatinine	3.8 mg/dL
Total protein	8.9 g/dL
Albumin	3.5 g/dL

Renal biopsy is performed and light microscopy shows atrophic tubules, many of which contain large, obstructing, waxy casts that stain intensely with eosin. Which of the following is the most likely diagnosis in this patient?

- A. Acute pyelonephritis
- B. Aminoglycoside toxicity
- C. Hypersensitivity interstitial nephritis
- D. Ischemic tubular necrosis
- E. Lead nephropathy
- F. Multiple myeloma
- G. Nonsteroidal anti-inflammatory drug–associated nephropathy
- H. Papillary necrosis
- I. Urate nephropathy

Submit

11
12
13
14
15
16
17
18
19
20
21
22
23
24
25
26
27
28
29
30
31
32
33
34
35
36
37
38
39
40

Blood urea nitrogen	68 mg/dL
Creatinine	3.8 mg/dL
Total protein	8.9 g/dL
Albumin	3.5 g/dL

Renal biopsy is performed and light microscopy shows atrophic tubules, many of which contain large, obstructing, waxy casts that stain intensely with eosin. Which of the following is the most likely diagnosis in this patient?

A. Acute pyelonephritis (2%)
B. Aminoglycoside toxicity (1%)
C. Hypersensitivity interstitial nephritis (6%)
D. Ischemic tubular necrosis (18%)
E. Lead nephropathy (2%)
✓ F. Multiple myeloma (53%)
G. Nonsteroidal anti-inflammatory drug–associated nephropathy (10%)
H. Papillary necrosis (5%)
I. Urate nephropathy (1%)

Omitted
Correct answer

53%
Answered correctly

06 secs
Time Spent

04/28/2020
Last Updated

Multiple myeloma	
Pathophysiology	• Plasma cell neoplasm produces **monoclonal** paraprotein (immunoglobulin)
Manifestations	• Bone pain, fractures • Constitutional symptoms (weight loss, fatigue) • Recurrent infections
Laboratory	• Normocytic anemia • Renal insufficiency • Hypercalcemia (constipation, muscle weakness) • Monoclonal paraproteinemia **(M-spike)**
Radiology	• **Osteolytic lesions**/osteopenia (osteoclast activation)

This patient with back pain, fatigue, normocytic anemia, renal failure, and a gamma gap (serum total protein minus serum albumin ≥4 g/dL) likely has **multiple myeloma** (MM). MM is a lymphoproliferative disorder characterized by monoclonal plasma cell proliferation and production of monoclonal immunoglobulins. It should be suspected in elderly patients with any combination of **hypercalcemia** (causes constipation), **normocytic anemia** (causes fatigue), **bone pain** (often in the back and ribs due to lytic lesions), elevated **gamma gap** (due to the presence of large amounts of monoclonal proteins), or **renal failure**.

Renal failure in MM is often caused by **light chain cast nephropathy**. Free light chains (Bence Jones proteins) are filtered by the glomerulus in small amounts and then reabsorbed in the tubules. When levels exceed reabsorptive capacity, light chains precipitate with Tamm-Horsfall protein and form casts that cause tubular obstruction and epithelial injury, leading to impaired renal function. On light microscopy, numerous large, glassy **eosinophilic casts** are seen. Deposition of light chain fragments in the glomerular mesangium and capillary loops can also cause renal failure in MM (amyloid light-chain amyloidosis).

(Choice A) Acute pyelonephritis presents acutely with fever, flank pain, and pyuria. White blood cell casts may be present.

(Choices B and D) Both nephrotoxins (eg, aminoglycosides) and ischemia cause acute tubular necrosis, which classically presents with muddy brown, granular epithelial cell casts and tubular epithelial cells in the urine.

11
12
13
14
15
16
17
18
19
20
21
22
23
24
25
26
27
28
29
30
31
32
33
34
35
36
37
38
39
40

Renal failure in MM is often caused by **light chain cast nephropathy**. Free light chains (Bence Jones proteins) are filtered by the glomerulus in small amounts and then reabsorbed in the tubules. When levels exceed reabsorptive capacity, light chains precipitate with Tamm-Horsfall protein and form casts that cause tubular obstruction and epithelial injury, leading to impaired renal function. On light microscopy, numerous large, glassy **eosinophilic casts** are seen. Deposition of light chain fragments in the glomerular mesangium and capillary loops can also cause renal failure in MM (amyloid light-chain amyloidosis).

(Choice A) Acute pyelonephritis presents acutely with fever, flank pain, and pyuria. White blood cell casts may be present.

(Choices B and D) Both nephrotoxins (eg, aminoglycosides) and ischemia cause acute tubular necrosis, which classically presents with muddy brown, granular epithelial cell casts and tubular epithelial cells in the urine.

(Choice C) Hypersensitivity interstitial nephritis is often associated with initiation of a new medication. Eosinophilia and eosinophiluria with white cell casts containing eosinophils may be seen; however, waxy eosinophilic casts are not present.

(Choice E) Chronic lead intoxication produces chronic tubulointerstitial nephritis (interstitial fibrosis and tubular atrophy seen on light microscopy); casts are unexpected.

(Choices G and H) Nonsteroidal anti-inflammatory drugs (NSAIDs) may cause chronic interstitial nephritis or acute papillary necrosis; urinalysis may show clear, hyaline casts. Excessive NSAID use is often associated with a microcytic (from gastrointestinal bleeding) rather than normocytic anemia, and a gamma gap would not be expected.

(Choice I) Chronic hyperuricemia leads to urate nephropathy due to precipitation of urate crystals. On light microscopy, needle-shaped crystals are seen in the interstitium and tubular lumen.

Educational objective:
Multiple myeloma should be suspected in elderly patients with any combination of hypercalcemia, normocytic anemia, bone pain, elevated gamma gap, or renal failure. Renal failure is commonly caused by light chain cast nephropathy; large, waxy, eosinophilic casts composed of Bence Jones proteins are seen in the tubular lumen.

Pathology	Renal, Urinary Systems & Electrolytes	Multiple myeloma
Subject	System	Topic

11
12
13
14
15
16
17
18
19
20
21
22
23
24
25
26
27
28
29
30
31
32
33
34
35
36
37
38
39
40

Leukocytes	7,100/mm^3
Platelets	150,000/mm^3
Serum chemistry	
Sodium	135 mEq/L
Potassium	5.1 mEq/L
Blood urea nitrogen	45 mg/dL
Creatinine	3.0 mg/dL

Urine sediment is unremarkable. Ultrasound examination shows bilateral small kidneys and no hydronephrosis. Kidney biopsy shows intimal thickening and luminal narrowing of the renal arterioles with evidence of glomerular sclerosis. Which of the following is most likely responsible for this patient's kidney disease?

A. Analgesic use
B. Fibromuscular dysplasia
C. Hepatitis C infection
D. Hypertension
E. Multiple myeloma

Submit

A 70-year-old man is brought to the hospital by his son for evaluation of worsening fatigue. The patient has not seen a physician in the past 15 years. He takes naproxen occasionally for knee arthritis. Physical examination of the prostate shows no abnormalities. Laboratory results are as follows:

Complete blood count	
Hemoglobin	10.5 g/dL
Leukocytes	7,100/mm^3
Platelets	150,000/mm^3
Serum chemistry	
Sodium	135 mEq/L
Potassium	5.1 mEq/L
Blood urea nitrogen	45 mg/dL
Creatinine	3.0 mg/dL

Urine sediment is unremarkable. Ultrasound examination shows bilateral small kidneys and no hydronephrosis. Kidney biopsy shows intimal thickening and luminal narrowing of the renal arterioles with evidence of glomerular sclerosis. Which of the following is most likely responsible for this patient's kidney disease?

A. Analgesic use

B. Fibromuscular dysplasia

C. Hepatitis C infection

Leukocytes	7,100/mm^3
Platelets	150,000/mm^3

Serum chemistry

Sodium	135 mEq/L
Potassium	5.1 mEq/L
Blood urea nitrogen	45 mg/dL
Creatinine	3.0 mg/dL

Urine sediment is unremarkable. Ultrasound examination shows bilateral small kidneys and no hydronephrosis. Kidney biopsy shows intimal thickening and luminal narrowing of the renal arterioles with evidence of glomerular sclerosis. Which of the following is most likely responsible for this patient's kidney disease?

A. Analgesic use
B. Fibromuscular dysplasia
C. Hepatitis C infection
D. Hypertension
E. Multiple myeloma

Submit

11
12
13
14
15
16
17
18
19
20
21
22
23
24
25
26
27
28
29
30
31
32
33
34
35
36
37
38
39
40

Leukocytes	7,100/mm^3
Platelets	150,000/mm^3
Serum chemistry	
Sodium	135 mEq/L
Potassium	5.1 mEq/L
Blood urea nitrogen	45 mg/dL
Creatinine	3.0 mg/dL

Urine sediment is unremarkable. Ultrasound examination shows bilateral small kidneys and no hydronephrosis. Kidney biopsy shows intimal thickening and luminal narrowing of the renal arterioles with evidence of glomerular sclerosis. Which of the following is most likely responsible for this patient's kidney disease?

A. Analgesic use (21%)
B. Fibromuscular dysplasia (6%)
C. Hepatitis C infection (3%)
✓ D. Hypertension (64%)
E. Multiple myeloma (4%)

Omitted
Correct answer

64%
Answered correctly

05 secs
Time Spent

03/15/2020
Last Updated

Explanation

This patient's biopsy findings are consistent with **hypertensive nephrosclerosis** (HN), a complication of chronic hypertension that is most common in elderly patients. Prolonged elevation of systemic blood pressure causes the renal arterioles to undergo compensatory **medial hypertrophy** and **fibrointimal proliferation**. Endothelial damage leads to deposition of plasma proteins and basement membrane material in the arteriolar walls (**hyaline arteriolosclerosis**). The resultant lumenal narrowing restricts renal blood flow, resulting in glomerular ischemia and fibrosis (**glomerulosclerosis**) with collapse of the capillary loops and thickening of the Bowman capsule. Gross examination of affected kidneys shows mild **renal atrophy** with a finely granular surface.

HN generally progresses slowly, and most patients with mild to moderate disease do not develop renal insufficiency. However, advanced disease occurs more commonly in patients of African American descent and in those with severe hypertension or comorbid diabetes. Proteinuria is common in advanced disease, but **urinalysis** is otherwise typically **bland** (eg, no casts, red or white blood cells). Like all chronic kidney diseases, advanced HN can cause **anemia** due to a reduction in renal erythropoietin production.

(Choice A) Analgesic nephropathy can occur with prolonged, excessive nonsteroidal anti-inflammatory use. However, pathologic findings typically include papillary necrosis and tubulointerstitial nephritis.

(Choice B) Fibromuscular dysplasia causes renal artery stenosis, resulting in refractory hypertension. However, it typically occurs in younger women (age <50), and histology characteristically shows fibromuscular ridges alternating with areas of aneurysmal dilation affecting the main renal artery.

(Choice C) Hepatitis C infection can cause membranous nephropathy, which presents with nephrotic syndrome (eg, proteinuria, edema). Histology demonstrates diffuse thickening of the glomerular basement membrane without glomerular hypercellularity.

(Choice E) Multiple myeloma can cause anemia and renal disease, but histology typically demonstrates a light chain cast nephropathy; eosinophilic casts obstruct the renal tubules, resulting in tubular inflammation and fibrosis. Patients typically also have fatigue, constipation (hypercalcemia), and bone pain (lytic lesions).

Educational objective:
Chronic hypertension can result in hypertensive nephrosclerosis, which is characterized by compensatory medial hypertrophy and fibrointimal proliferation; endothelial damage from elevated systemic pressure also leads to hyaline arteriolosclerosis. The narrowed arteriolar lumens cause

shows mild **renal atrophy** with a finely granular surface.

HN generally progresses slowly, and most patients with mild to moderate disease do not develop renal insufficiency. However, advanced disease occurs more commonly in patients of African American descent and in those with severe hypertension or comorbid diabetes. Proteinuria is common in advanced disease, but **urinalysis** is otherwise typically **bland** (eg, no casts, red or white blood cells). Like all chronic kidney diseases, advanced HN can cause **anemia** due to a reduction in renal erythropoietin production.

(Choice A) Analgesic nephropathy can occur with prolonged, excessive nonsteroidal anti-inflammatory use. However, pathologic findings typically include papillary necrosis and tubulointerstitial nephritis.

(Choice B) Fibromuscular dysplasia causes renal artery stenosis, resulting in refractory hypertension. However, it typically occurs in younger women (age <50), and histology characteristically shows fibromuscular ridges alternating with areas of aneurysmal dilation affecting the main renal artery.

(Choice C) Hepatitis C infection can cause membranous nephropathy, which presents with nephrotic syndrome (eg, proteinuria, edema). Histology demonstrates diffuse thickening of the glomerular basement membrane without glomerular hypercellularity.

(Choice E) Multiple myeloma can cause anemia and renal disease, but histology typically demonstrates a light chain cast nephropathy; eosinophilic casts obstruct the renal tubules, resulting in tubular inflammation and fibrosis. Patients typically also have fatigue, constipation (hypercalcemia), and bone pain (lytic lesions).

Educational objective:
Chronic hypertension can result in hypertensive nephrosclerosis, which is characterized by compensatory medial hypertrophy and fibrointimal proliferation; endothelial damage from elevated systemic pressure also leads to hyaline arteriolosclerosis. The narrowed arteriolar lumens cause a progressive decrease in renal blood flow, resulting in glomerular ischemia and fibrosis (glomerulosclerosis).

Pathology	Renal, Urinary Systems & Electrolytes	Primary hypertension
Subject	System	Topic

Copyright © UWorld. All rights reserved.

A 54-year-old man hospitalized with an acute myocardial infarction goes into cardiac arrest. The patient is resuscitated successfully and transferred to the cardiac intensive care unit where he remains hemodynamically stable. However, on the second day of hospitalization, his urine flow diminishes to 400 mL/day. Blood pressure is 115/68 mm Hg and pulse is 78/min. Laboratory results are as follows:

	Day 1	Day 2
Sodium	134 mEq/L	133 mEq/L
Potassium	4.2 mEq/L	4.0 mEq/L
Chloride	96 mEq/L	94 mEq/L
Bicarbonate	26 mEq/L	22 mEq/L
Blood urea nitrogen	16 mg/dL	26 mg/dL
Creatinine	1.1 mg/dL	2.4 mg/dL

Urine sediment microscopy reveals muddy brown casts. Which of the following renal structures in this patient are most likely to demonstrate signs of ischemic injury?

A. Collecting ducts
B. Distal tubules
C. Glomeruli
D. Proximal tubules
E. Renal papillae

transferred to the cardiac intensive care unit where he remains hemodynamically stable. However, on the second day of hospitalization, his urine flow diminishes to 400 mL/day. Blood pressure is 115/68 mm Hg and pulse is 78/min. Laboratory results are as follows:

	Day 1	Day 2
Sodium	134 mEq/L	133 mEq/L
Potassium	4.2 mEq/L	4.0 mEq/L
Chloride	96 mEq/L	94 mEq/L
Bicarbonate	26 mEq/L	22 mEq/L
Blood urea nitrogen	16 mg/dL	26 mg/dL
Creatinine	1.1 mg/dL	2.4 mg/dL

Urine sediment microscopy reveals muddy brown casts. Which of the following renal structures in this patient are most likely to demonstrate signs of ischemic injury?

A. Collecting ducts (6%)
B. Distal tubules (7%)
C. Glomeruli (7%)
✓ D. Proximal tubules (69%)
E. Renal papillae (10%)

Omitted
Correct answer

69%
Answered correctly

03 secs
Time Spent

05/03/2020
Last Updated

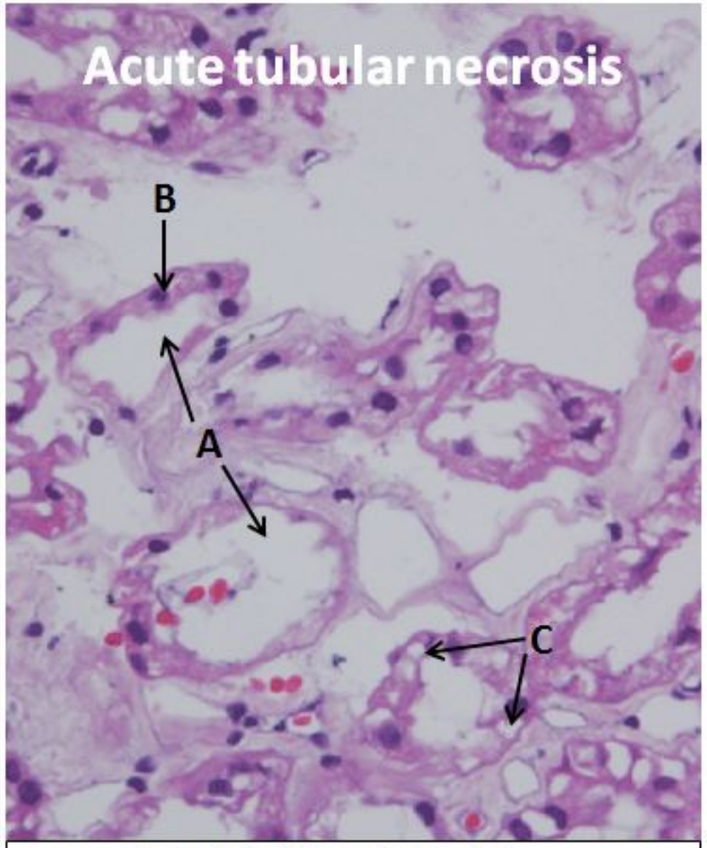

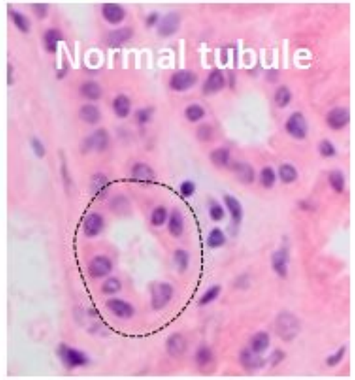

Outer medulla of the kidney (H&E stain)
(a) Patchy loss of proximal tubular epithelial cells with tubular dilation; (b) regenerating epithelial cells with hyperchromatic nuclei; (c) epithelial cell vacuolization.

This patient most likely has **acute tubular necrosis** (ATN) due to decreased renal perfusion during cardiac arrest (cardiogenic shock). Ischemic kidney injury predominantly affects the **renal medulla**, which has low blood supply even under normal conditions. The **most metabolically active** segments of the nephron are particularly vulnerable, including the terminal (straight) portion of the **proximal tubule** and **thick ascending limb** of

This patient most likely has **acute tubular necrosis** (ATN) due to decreased renal perfusion during cardiac arrest (cardiogenic shock). Ischemic kidney injury predominantly affects the **renal medulla**, which has low blood supply even under normal conditions. The **most metabolically active** segments of the nephron are particularly vulnerable, including the terminal (straight) portion of the **proximal tubule** and **thick ascending limb** of the loop of Henle.

ATN is characterized histologically by flattening of the tubular epithelial cells with loss of the brush border and subsequent cell necrosis and denudation of the tubular basement membrane. Muddy brown casts consisting of sloughed and degenerated tubule cells are pathognomonic for ATN. Patients have **increased serum creatinine**, a blood urea nitrogen/serum creatinine ratio <20 (indicating intrinsic renal pathology), and **oliguria**.

(Choices A and B) The collecting ducts and distal tubules are located in the renal cortex and are less likely to show signs of ischemic injury because they are less metabolically active than the proximal tubules or the thick ascending limb of the loop of Henle.

(Choice C) The increased distal sodium delivery caused by tubular dysfunction in ATN leads to afferent arteriolar constriction via the tubuloglomerular feedback mechanism. This can further reduce medullary blood flow and worsen tubular ischemic damage. However, the glomeruli themselves are less susceptible to ischemic injury because of their low oxygen demand.

(Choice E) Renal papillary blood supply may be interrupted by urinary tract obstruction/infection, interstitial nephritis due to analgesic ingestion, or microvascular disease (eg, diabetes mellitus, sickle cell disease). However, renal papillary necrosis typically presents with gross hematuria and flank pain.

Educational objective:
Acute tubular necrosis is caused by renal ischemia and is characterized by oliguria, increased serum creatinine, and muddy brown casts. Ischemic injury predominantly affects the renal medulla, which has a relatively low blood supply. The terminal (straight) portion of the proximal tubules and the thick ascending limb of the loop of Henle are the most commonly involved portions of the nephron due to their high metabolic rate and location within the medulla.

Pathology	Renal, Urinary Systems & Electrolytes	Acute kidney injury
Subject	System	Topic

segments of the nephron are particularly vulnerable, including the terminal (straight) portion of the **proximal tubule** and **thick ascending limb** of the loop of Henle.

ATN is characterized histologically by flattening of the tubular epithelial cells with loss of the brush border and subsequent cell necrosis and denudation of the tubular basement membrane. Muddy brown casts consisting of sloughed and degenerated tubule cells are pathognomonic for ATN. Patients have **increased serum creatinine**, a blood urea nitrogen/serum creatinine ratio <20 (indicating intrinsic renal pathology), and **oliguria**.

(Choices A and B) The collecting ducts and distal tubules are located in the renal cortex and are less likely to show signs of ischemic injury because they are less metabolically active than the proximal tubules or the thick ascending limb of the loop of Henle.

(Choice C) The increased distal sodium delivery caused by tubular dysfunction in ATN leads to afferent arteriolar constriction via the tubuloglomerular feedback mechanism. This can further reduce medullary blood flow and worsen tubular ischemic damage. However, the glomeruli themselves are less susceptible to ischemic injury because of their low oxygen demand.

(Choice E) Renal papillary blood supply may be interrupted by urinary tract obstruction/infection, interstitial nephritis due to analgesic ingestion, or microvascular disease (eg, diabetes mellitus, sickle cell disease). However, renal papillary necrosis typically presents with gross hematuria and flank pain.

Educational objective:
Acute tubular necrosis is caused by renal ischemia and is characterized by oliguria, increased serum creatinine, and muddy brown casts. Ischemic injury predominantly affects the renal medulla, which has a relatively low blood supply. The terminal (straight) portion of the proximal tubules and the thick ascending limb of the loop of Henle are the most commonly involved portions of the nephron due to their high metabolic rate and location within the medulla.

Pathology	Renal, Urinary Systems & Electrolytes	Acute kidney injury
Subject	System	Topic

Copyright © UWorld. All rights reserved.

A 50-year-old man with polycystic kidney disease comes to the office due to constant, deep pain in his shoulders, arms, and legs. Medical history includes long-standing hypertension treated with ramipril. Blood pressure is 150/85 mm Hg and pulse is 78/min. Cardiopulmonary examination is normal. Abdominal examination shows large, palpable renal masses. Trace bilateral lower-extremity edema is present. Laboratory results from 2 years ago showed a blood urea nitrogen level of 25 mg/dL and a creatinine level of 2.3 mg/dL. Current laboratory results are as follows:

Sodium	136 mEq/L
Potassium	4.8 mEq/L
Chloride	104 mEq/L
Bicarbonate	22 mEq/L
Blood urea nitrogen	66 mg/dL
Creatinine	5.5 mg/dL
Calcium	7.5 mg/dL

Which of the following metabolic states is most likely present in this patient?

	Phosphate	Parathyroid Hormone	Calcitriol
A.	↓	↑	↑
B.	↑	↓	↑
C.	↑	↑	↓
D.	↓	↑	↓
E.	↑	↓	↓

Sodium	136 mEq/L
Potassium	4.8 mEq/L
Chloride	104 mEq/L
Bicarbonate	22 mEq/L
Blood urea nitrogen	66 mg/dL
Creatinine	5.5 mg/dL
Calcium	7.5 mg/dL

Which of the following metabolic states is most likely present in this patient?

	Phosphate	Parathyroid Hormone	Calcitriol
A. (9%)	↓	↑	↑
B. (4%)	↑	↓	↑
✓ C. (61%)	↑	↑	↓
D. (18%)	↓	↑	↓
E. (5%)	↑	↓	↓

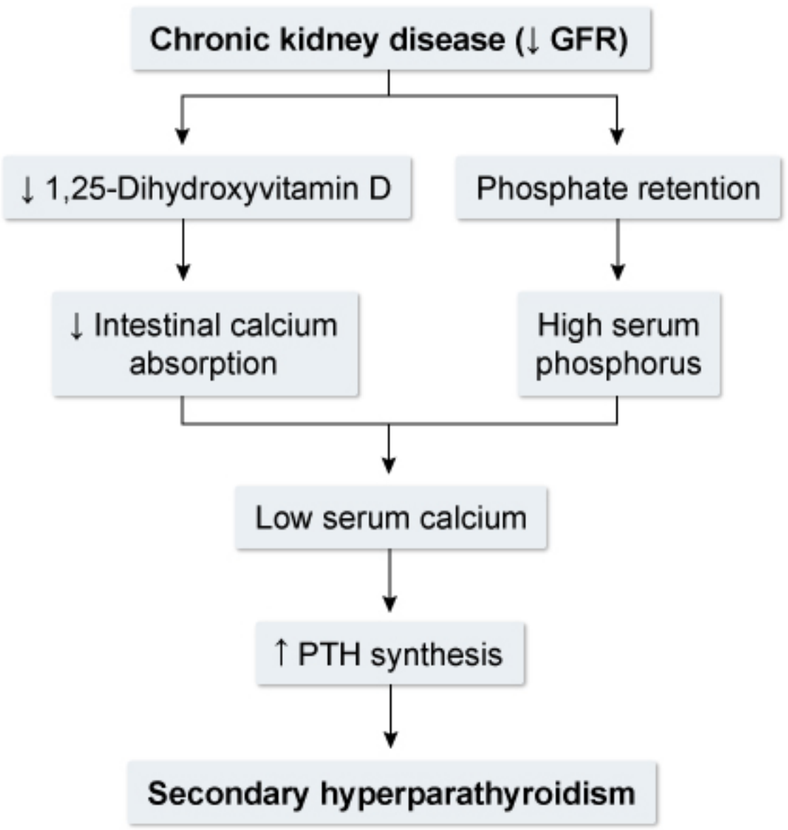

GFR = glomerular filtration rate; **PTH** = parathyroid hormone.

©UWorld

This patient's presentation is consistent with **metabolic bone disease** due to chronic kidney disease (CKD). CKD decreases the glomerular filtration rate (GFR), which decreases the filtered phosphate load and causes **elevated serum phosphate levels**. Hyperphosphatemia reduces serum free calcium and stimulates osteocytes and osteoclasts to release fibroblast growth factor-23 (FGF-23), a circulating peptide that decreases proximal tubule phosphate reabsorption. Elevated levels of phosphate and FGF-23 also **reduce calcitriol synthesis** by inhibiting the proximal

This patient's presentation is consistent with **metabolic bone disease** due to chronic kidney disease (CKD). CKD decreases the glomerular filtration rate (GFR), which decreases the filtered phosphate load and causes **elevated serum phosphate levels**. Hyperphosphatemia reduces serum free calcium and stimulates osteocytes and osteoclasts to release fibroblast growth factor-23 (FGF-23), a circulating peptide that decreases proximal tubule phosphate reabsorption. Elevated levels of phosphate and FGF-23 also **reduce calcitriol synthesis** by inhibiting the proximal tubular expression of 1-alpha-hydroxylase, resulting in decreased intestinal calcium and phosphate absorption. This worsens hypocalcemia but does not significantly improve hyperphosphatemia due to the low GFR, which is the limiting factor for phosphate excretion in patients with advanced CKD.

Hypocalcemia and hyperphosphatemia also **increase parathyroid hormone (PTH) secretion**, which stimulates osteoclasts to increase bone turnover. Long-term elevation in PTH (secondary hyperparathyroidism) can eventually lead to friable bones and **osteitis fibrosa**. Affected patients can develop weakness, **bone pain**, and fractures.

(Choice A) Primary hyperparathyroidism causes hypercalcemia and decreased serum phosphate due to inappropriately elevated PTH. Renal synthesis of calcitriol is also increased by PTH. In contrast, calcitriol levels remain low in patients with CKD due to the reduction in renal mass and the inhibitory effects of FGF-23 and phosphate.

(Choice B) Vitamin D toxicity raises calcitriol levels, which increases calcium and phosphate absorption causing hypercalcemia and hyperphosphatemia. Hypercalcemia inhibits PTH release, lowering serum PTH.

(Choice D) Vitamin D deficiency in patients with normally functioning kidneys decreases intestinal calcium and phosphate absorption, leading to lower serum phosphate and calcium levels. The resulting hypocalcemia stimulates PTH release from the parathyroid glands.

(Choice E) Primary hypoparathyroidism causes hypocalcemia and hyperphosphatemia due to decreased PTH. Calcitriol levels can also be low due to decreased PTH-mediated stimulation of renal 1-alpha-hydroxylase.

Educational objective:
Chronic kidney disease causes disordered mineralization and bone metabolism that usually presents with hyperphosphatemia, secondary hyperparathyroidism, and decreased calcitriol levels. Patients can be asymptomatic or develop weakness, bone pain, and fractures.

References

advanced CKD.

Hypocalcemia and hyperphosphatemia also **increase parathyroid hormone (PTH) secretion**, which stimulates osteoclasts to increase bone turnover. Long-term elevation in PTH (secondary hyperparathyroidism) can eventually lead to friable bones and **osteitis fibrosa**. Affected patients can develop weakness, **bone pain**, and fractures.

(Choice A) Primary hyperparathyroidism causes hypercalcemia and decreased serum phosphate due to inappropriately elevated PTH. Renal synthesis of calcitriol is also increased by PTH. In contrast, calcitriol levels remain low in patients with CKD due to the reduction in renal mass and the inhibitory effects of FGF-23 and phosphate.

(Choice B) Vitamin D toxicity raises calcitriol levels, which increases calcium and phosphate absorption causing hypercalcemia and hyperphosphatemia. Hypercalcemia inhibits PTH release, lowering serum PTH.

(Choice D) Vitamin D deficiency in patients with normally functioning kidneys decreases intestinal calcium and phosphate absorption, leading to lower serum phosphate and calcium levels. The resulting hypocalcemia stimulates PTH release from the parathyroid glands.

(Choice E) Primary hypoparathyroidism causes hypocalcemia and hyperphosphatemia due to decreased PTH. Calcitriol levels can also be low due to decreased PTH-mediated stimulation of renal 1-alpha-hydroxylase.

Educational objective:
Chronic kidney disease causes disordered mineralization and bone metabolism that usually presents with hyperphosphatemia, secondary hyperparathyroidism, and decreased calcitriol levels. Patients can be asymptomatic or develop weakness, bone pain, and fractures.

References

- Chronic kidney disease-mineral and bone disorders (CKD-MBDs): what the endocrinologist needs to know.

Pathology	Renal, Urinary Systems & Electrolytes	Chronic kidney disease
Subject	System	Topic

Copyright © UWorld. All rights reserved.

Settings

1
2
3
4

Item 3 of 4
Question Id: 1850

Mark | Previous | Next | Full Screen | Tutorial | Lab Values | Notes | Calculator | Reverse Color | Text Zoom | Settings

A 7-year-old boy with a two-day history of colicky abdominal pain now develops bloody stools. His mother states that his urine also appeared red today. Physical examination reveals palpable skin lesions on his buttocks. Which of the following additional findings is most consistent with this patient's condition?

A. Impetigo
B. Joint pain
C. Swollen lymph nodes
D. Red eyes
E. Oral ulcers

Submit

Block Time Remaining: 00:00:07
TUTOR

2 | Feedback | Suspend | End Block

A 7-year-old boy with a two-day history of colicky abdominal pain now develops bloody stools. His mother states that his urine also appeared red today. Physical examination reveals palpable skin lesions on his buttocks. Which of the following additional findings is most consistent with this patient's condition?

A. Impetigo (10%)
✓ B. Joint pain (64%)
C. Swollen lymph nodes (10%)
D. Red eyes (6%)
E. Oral ulcers (7%)

Omitted
Correct answer
B

64%
Answered correctly

02 secs
Time Spent

02/03/2020
Last Updated

Explanation

This patient presents with classic signs of Henoch-Schönlein purpura (HSP), the most common small vessel vasculitis in children. This disease classically affects boys 2-10 years old, and is often preceded by viral or streptococcal upper respiratory infections. Symptoms of HSP generally develop a few weeks after the associated illness resolves. It is hypothesized that antigen from the infection stimulates production of IgA antibodies and that IgA-containing immune complexes then deposit on vessel walls, inducing an inflammatory reaction. HSP is therefore an IgA-mediated leukocytoclastic (hypersensitivity) vasculitis.

The effects of this vasculitis are seen most prominently in the following organ systems:

This patient presents with classic signs of Henoch-Schönlein purpura (HSP), the most common small vessel vasculitis in children. This disease classically affects boys 2-10 years old, and is often preceded by viral or streptococcal upper respiratory infections. Symptoms of HSP generally develop a few weeks after the associated illness resolves. It is hypothesized that antigen from the infection stimulates production of IgA antibodies and that IgA-containing immune complexes then deposit on vessel walls, inducing an inflammatory reaction. HSP is therefore an IgA-mediated leukocytoclastic (hypersensitivity) vasculitis.

The effects of this vasculitis are seen most prominently in the following organ systems:

1. **Gastrointestinal tract:** Intermittent severe abdominal pain is common in HSP. Vasculitis within the GI tract may result in upper and lower GI bleeding (hematemesis and bloody diarrhea, respectively) as well as bowel wall edema. Patients with HSP also have an increased risk of intussusception.
2. **Kidneys:** Renal involvement in HSP is identical to that seen in IgA nephropathy (Berger disease), a condition characterized by IgA leukocytoclastic vasculitis limited to the kidney. Both diseases cause mesangial proliferation and crescent formation.
3. **Skin:** HSP classically causes "palpable purpura" on the buttocks and lower extremities. These lesions may begin as urticarial papules or plaques and subsequently evolve into purpura. The cutaneous findings in HSP result from leukocytoclasis of cutaneous vessels.
4. **Joints:** Self-limited migratory arthralgias and arthritis are most commonly seen in the large joints of the lower extremities (ankle and knee joints), possibly because of their dependent nature.

(Choice A) Impetigo is a superficial skin infection characterized by a "honey-colored" crust. Streptococcus and Staphylococcus species are generally responsible.

(Choices C and D) Swollen lymph nodes and red eyes are characteristic findings in Kawasaki disease. Other symptoms of Kawasaki disease include high fevers, strawberry tongue, perioral erythema and fissuring, and periungual desquamation.

(Choice E) Oral ulcers can be a component of many illnesses, including pemphigus vulgaris, paraneoplastic pemphigus, Behçet disease and Crohn's disease.

Educational Objective:
Henoch-Schönlein purpura (HSP) generally affects young children and is classically preceded by an upper respiratory infection. This IgA-

mediated leukocytoclastic (hypersensitivity) vasculitis.

The effects of this vasculitis are seen most prominently in the following organ systems:

1. **Gastrointestinal tract:** Intermittent severe abdominal pain is common in HSP. Vasculitis within the GI tract may result in upper and lower GI bleeding (hematemesis and bloody diarrhea, respectively) as well as bowel wall edema. Patients with HSP also have an increased risk of intussusception.
2. **Kidneys:** Renal involvement in HSP is identical to that seen in IgA nephropathy (Berger disease), a condition characterized by IgA leukocytoclastic vasculitis limited to the kidney. Both diseases cause mesangial proliferation and crescent formation.
3. **Skin:** HSP classically causes "palpable purpura" on the buttocks and lower extremities. These lesions may begin as urticarial papules or plaques and subsequently evolve into purpura. The cutaneous findings in HSP result from leukocytoclasis of cutaneous vessels.
4. **Joints:** Self-limited migratory arthralgias and arthritis are most commonly seen in the large joints of the lower extremities (ankle and knee joints), possibly because of their dependent nature.

(Choice A) Impetigo is a superficial skin infection characterized by a "honey-colored" crust. Streptococcus and Staphylococcus species are generally responsible.

(Choices C and D) Swollen lymph nodes and red eyes are characteristic findings in Kawasaki disease. Other symptoms of Kawasaki disease include high fevers, strawberry tongue, perioral erythema and fissuring, and periungual desquamation.

(Choice E) Oral ulcers can be a component of many illnesses, including pemphigus vulgaris, paraneoplastic pemphigus, Behçet disease and Crohn's disease.

Educational Objective:
Henoch-Schönlein purpura (HSP) generally affects young children and is classically preceded by an upper respiratory infection. This IgA-mediated hypersensitivity (leukocytoclastic) vasculitis commonly causes abdominal pain, joint pain, lower extremity palpable purpura and hematuria.

Pathology	Renal, Urinary Systems & Electrolytes	Henoch schonlein purpura
Subject	System	Topic

Settings

1
2
3
4

Item 4 of 4
Question Id: 817

Mark | Previous | Next | Full Screen | Tutorial | Lab Values | Notes | Calculator | Reverse Color | Text Zoom | Settings

A nephrology researcher conducts a clinical study to determine the risk factors for the development of renal calculi. He recruits a number of patients with a history of idiopathic calcium oxalate kidney stones, along with age- and sex-matched healthy subjects. Detailed medical, surgical, and nutritional histories are obtained, and several serum and urine laboratory tests are performed. Which of the following is most likely to be seen in affected patients compared with healthy individuals?

A. Higher dietary calcium

B. Higher dietary potassium

C. Higher fluid intake

D. Lower dietary oxalate

E. Lower urinary citrate

Submit

Block Time Remaining: 00:00:09
TUTOR

3 | Feedback | Suspend | End Block

A nephrology researcher conducts a clinical study to determine the risk factors for the development of renal calculi. He recruits a number of patients with a history of idiopathic calcium oxalate kidney stones, along with age- and sex-matched healthy subjects. Detailed medical, surgical, and nutritional histories are obtained, and several serum and urine laboratory tests are performed. Which of the following is most likely to be seen in affected patients compared with healthy individuals?

A. Higher dietary calcium (22%)

B. Higher dietary potassium (3%)

C. Higher fluid intake (1%)

D. Lower dietary oxalate (8%)

✓ E. Lower urinary citrate (63%)

Omitted
Correct answer
E

63%
Answered correctly

02 secs
Time Spent

03/30/2020
Last Updated

Explanation

Risk & prevention of kidney stones		
Stone type	**Risk factors**	**Prevention**
	• Hypercalciuria (eg, hyperparathyroidism) • Hyperoxaluria (eg, malabsorption,	• Reduce sodium, animal protein, oxalate

Risk & prevention of kidney stones		
Stone type	**Risk factors**	**Prevention**
Calcium stones (oxalate, phosphate)	• Hypercalciuria (eg, hyperparathyroidism) • Hyperoxaluria (eg, malabsorption, low-calcium diet) • Hypocitraturia (eg, distal RTA) • Diet: ↑ sodium, ↑ protein, ↑ oxalate, ↓ calcium	• Reduce sodium, animal protein, oxalate intake • Increase potassium intake; moderate calcium intake • Thiazide diuretics
Uric acid	• Gout • Myeloproliferative disorders	• Urine alkalinization • Allopurinol
Magnesium ammonium phosphate (struvite)	• Recurrent upper urinary infection (eg, *Klebsiella*, *Proteus*)	• Stone removal • Suppressive antibiotics
All types	• Dehydration	• Increase fluid intake

RTA = renal tubular acidosis.

Renal calculi occur due to an imbalance of the factors that facilitate or prevent stone formation. Overall, increased urinary concentrations of calcium (hypercalciuria), oxalate (hyperoxaluria), and uric acid (hyperuricosuria) promote salt crystallization, whereas increased urinary citrate and high fluid intake inhibit calculi formation.

Normally, **citrate** excreted by the kidneys **binds to ionized calcium** in the urine, **preventing** the formation of **insoluble calcium-oxalate complexes**. When urinary citrate is low (**hypocitraturia**), increased calcium availability leads to formation of calcium-oxalate complexes that can precipitate and form **calcium oxalate stones**. Hypocitraturia often occurs in the setting of chronic metabolic acidosis (eg, distal renal tubular acidosis, chronic diarrhea) due to enhanced renal citrate reabsorption. Supplemental oral potassium citrate is often prescribed to prevent recurrent calcium stones.

RTA = renal tubular acidosis.

Renal calculi occur due to an imbalance of the factors that facilitate or prevent stone formation. Overall, increased urinary concentrations of calcium (hypercalciuria), oxalate (hyperoxaluria), and uric acid (hyperuricosuria) promote salt crystallization, whereas increased urinary citrate and high fluid intake inhibit calculi formation.

Normally, **citrate** excreted by the kidneys **binds to ionized calcium** in the urine, **preventing** the formation of **insoluble calcium-oxalate complexes**. When urinary citrate is low (**hypocitraturia**), increased calcium availability leads to formation of calcium-oxalate complexes that can precipitate and form **calcium oxalate stones**. Hypocitraturia often occurs in the setting of chronic metabolic acidosis (eg, distal renal tubular acidosis, chronic diarrhea) due to enhanced renal citrate reabsorption. Supplemental oral potassium citrate is often prescribed to prevent recurrent calcium stones.

(Choice A) Individuals with higher (but not excessive) calcium intake paradoxically have a lower risk of calcium oxalate stone formation. Dietary calcium binds oxalate in the gut to form insoluble calcium oxalate, which is eliminated in the feces. This reduces the amount of oxalate absorbed into the body and excreted in the urine, reducing stone formation.

(Choice B) In patients with inadequate dietary intake of potassium, increased tubular reabsorption of potassium leads to increased citrate reabsorption, which facilitates formation of calcium oxalate complexes in the renal tubules. Higher potassium intake promotes urinary excretion of citrate and lowers urinary calcium excretion, leading to a lower risk of calcium oxalate stones.

(Choice C) High fluid intake prevents supersaturation of urine with stone-forming ingredients. Low fluid intake increases the urinary concentration of these ions regardless of their absolute amounts, promoting stone formation.

(Choice D) Excessive oxalate intake (eg, chocolate, spinach, rhubarb) leads to increased intestinal absorption of free oxalate, which is then excreted in the urine where it promotes formation of calcium oxalate stones. Intestinal malabsorption syndromes (eg, Crohn disease) can also cause hyperoxaluria because calcium becomes bound by unabsorbed lipids in the gut.

Educational objective:
Renal calculi occur due to an imbalance of the factors that facilitate or inhibit stone formation. Increased urinary concentrations of calcium, oxalate, and uric acid promote salt crystallization, whereas increased urinary citrate concentration and high fluid intake prevent calculi formation.

References

precipitate and form **calcium oxalate stones**. Hypocitraturia often occurs in the setting of chronic metabolic acidosis (eg, distal renal tubular acidosis, chronic diarrhea) due to enhanced renal citrate reabsorption. Supplemental oral potassium citrate is often prescribed to prevent recurrent calcium stones.

(Choice A) Individuals with higher (but not excessive) calcium intake paradoxically have a lower risk of calcium oxalate stone formation. Dietary calcium binds oxalate in the gut to form insoluble calcium oxalate, which is eliminated in the feces. This reduces the amount of oxalate absorbed into the body and excreted in the urine, reducing stone formation.

(Choice B) In patients with inadequate dietary intake of potassium, increased tubular reabsorption of potassium leads to increased citrate reabsorption, which facilitates formation of calcium oxalate complexes in the renal tubules. Higher potassium intake promotes urinary excretion of citrate and lowers urinary calcium excretion, leading to a lower risk of calcium oxalate stones.

(Choice C) High fluid intake prevents supersaturation of urine with stone-forming ingredients. Low fluid intake increases the urinary concentration of these ions regardless of their absolute amounts, promoting stone formation.

(Choice D) Excessive oxalate intake (eg, chocolate, spinach, rhubarb) leads to increased intestinal absorption of free oxalate, which is then excreted in the urine where it promotes formation of calcium oxalate stones. Intestinal malabsorption syndromes (eg, Crohn disease) can also cause hyperoxaluria because calcium becomes bound by unabsorbed lipids in the gut.

Educational objective:
Renal calculi occur due to an imbalance of the factors that facilitate or inhibit stone formation. Increased urinary concentrations of calcium, oxalate, and uric acid promote salt crystallization, whereas increased urinary citrate concentration and high fluid intake prevent calculi formation.

References

- Clinical review. Kidney stones 2012: pathogenesis, diagnosis, and management.

Pathology	Renal, Urinary Systems & Electrolytes	Renal calculi
Subject	System	Topic

Copyright © UWorld. All rights reserved.